

Comparison of the GTV coverage by PTV and isodose of 90% in 2D and 3D planning during endobronchial brachytherapy in the palliative treatment of patients with advanced lung cancer. Pilot study

Jarosław Łyczek, MD, PhD, Damian Kazalski, MD, Łukasz Kowalik, MSc, Marcin Sawicki, MSc

Brachytherapy Department, Brzozów Hospital, Subcarpathian Cancer Center, Brzozów, Poland

Abstract

Purpose: Endobronchial brachytherapy (EB) is one way of treatment of patients with advanced lung cancer. Technological progress and the introduction of computed tomography for use in 3D planning allows one to define the area being treated very precisely, which gives an opportunity to extend survival, even in groups of patients receiving palliative care.

Material and methods: In 2011, in the Brachytherapy Department of the Subcarpathian Oncological Center, a group of 12 consecutive patients with advanced cancer of the bronchus underwent palliative EB. We compared the coverage of GTV (gross tumor volume), seen in the computed tomography study with intravenous contrast, by the PTV (planning target volume) planned in 3D and 2D.

Results: In 2D planning GTV coverage ranged from 15% to 89%. By analyzing the isodose of 90%, it was found that 2D planning covered GTV in 15-35% of the dose. In 3D planning, this coverage changed positively, and ranged from 85% to 100%. The GTV coverage in 3D planning was 100% by definition. In addition, it should be noted that in the 3D planning one can spare critical organs or pacemakers.

Conclusions: Planning for HDR brachytherapy in all locations should be based on dynamic imaging at present, especially in centers that are equipped with CT. Evaluation should be a routine test in treatment planning. The use of CT, even in palliative treatment planning, allows for much better coverage of GTV areas as well, which is very important to reduce radiation doses to critical organs and thereby reduce the toxic effects of treatment.

J Contemp Brachyther 2012; 4, 2: 113-115

DOI: 10.5114/jcb.2012.29369

Key words: endobronchial brachytherapy, lung cancer, 3D planning.

Purpose

Endobronchial brachytherapy (EB) is one way of treatment of patients with advanced lung cancer [1,2]. Exophytically spreading tumors, restricting or obturating the bronchus in most cases, manifest disturbances of breathing, dyspnea, and sometimes hemoptysis. Routinely used techniques (external irradiation and/or chemotherapy) do not produce the desired effect, and often the cost of treatment is significant. The use of brachytherapy in these cases brings results in a very short time (even after the first fraction of irradiation) by improving ventilation and often relief of hemoptysis. Brachytherapy as a topical treatment in palliative care, inherently conformal, provides tangible benefits to the patient by improving the general condition and reducing

the stress level because of limitation of problems, giving time to implement systemic therapy [1,3]. Technological progress and the introduction of computed tomography for use in 3D planning [4] as a routine allows one to define the area being treated very precisely, which gives an opportunity to extend survival, even in groups of patients receiving palliative care [5,6].

Material and methods

In 2011, in the Brachytherapy Department of the Subcarpathian Oncological Center, a group of 12 consecutive patients with advanced lung cancer was treated with palliative EB. Two irradiation regimens were used, 4×6 Gy and 3×7 Gy to the PTV volume, and the selection of patient

Address for correspondence: Damian Kazalski, MD, Brachytherapy Department, Subcarpathian Cancer Center, 18 Bielawskiego Street, 36-200 Brzozów, Poland, phone: +48 13 430 79 06,
✉ e-mail: damian.kazalski@gmail.com; brachyterapia@szpital-brzozow.pl

Received: 02.06.12

Accepted: 14.06.12

Published: 30.06.12

for the group was random [1,7-10]. Patients were treated with a microSelectron unit (Nucletron®) with an Ir¹⁹² source, nominal activity of 10 Ci. Each treatment was planned on an Oncentra Masterplan Brachy 4.0 (Nucletron®). All patients had both orthogonal radiographs (simulator Simulix Oldelft, Nucletron®) and chest computed tomography (CT GE BrightSpeed 8®).

We compared the coverage of GTV (gross tumor volume), seen in the computed tomography study with intravenous contrast, by the PTV (planning target volume) planned in 3D and 2D. During the planning we selected both the PTV area (equivalent in 3D planning with GTV) and critical organs (area of myocardium, aorta, spinal cord and healthy lung tissue). In case of implanted pacemakers their volume was also contoured.

Length of the area irradiated with a 1 cm margin around the applicator was marked on the orthogonal 2D fluoroscopy studies, based on the descriptions of bronchoscopy. In the case of a single applicator the obtained PTV-2D region was in the form of a cylinder. Then, the area was transposed into a computer planning system, resulting in close to the actual

2D-planning PTV-2D area. Treatment planning was then performed according to the 2D rules. When planning the 'pseudo 2D' was established, the isodose of 100% had to cover PTV-2D by 100%, without taking into account the dose or volume of critical organs (Figs. 1A, 2A, 3A).

After that, 3D planning was performed according to International Commission of Radiation Units and Measurements (ICRU) standards, but with the aim not to exceed the maximum dose to critical organs (heart, aorta, healthy lung tissue, spinal cord) and the present pacemakers (Medtronic® - average dose < 5 Gy; other brands < 2 Gy) (Figs. 1B, 2B, 3B).

Results

Comparison of GTV coverage in 3D planning (with the assumption of 100%) as compared to 2D planning showed significant differences between those two planning systems. In 2D planning GTV coverage ranged from 15% to 89%. By analyzing the isodose of 90%, it was found that 2D planning covered GTV in 15-35% of the dose. In 3D planning, this coverage changed positively, and ranged from 85% to

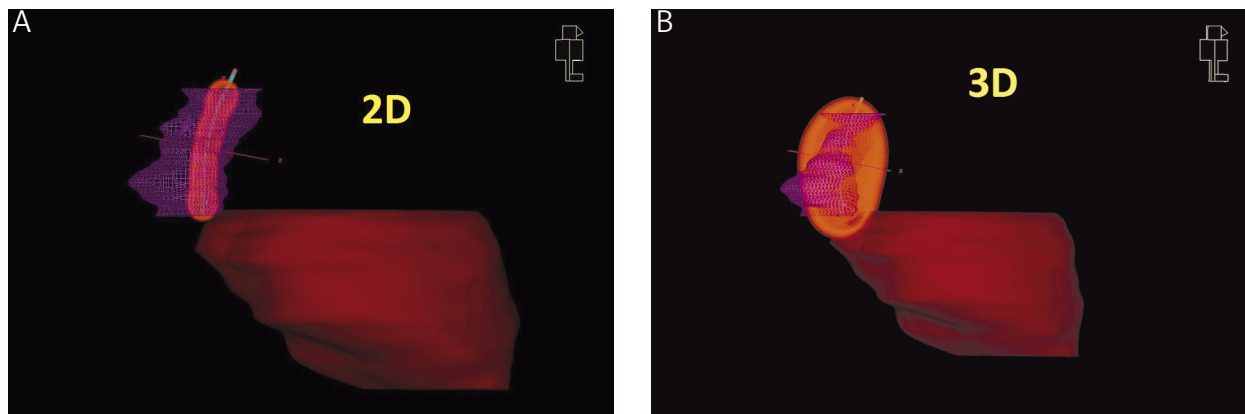


Fig. 1. A) Patient with one catheter inserted. Comparison of GTV coverage by the 90% isodose achieved in 2D planning system. Legend: purple triangles - GTV volume; orange cylinder - 2D 90% isodose; brown - heart; blue - catheter. B) Patient with one catheter inserted. Comparison of GTV coverage by the 90% isodose achieved in 3D planning system. Legend: purple triangles - GTV volume; orange volume - 3D 90% isodose; brown - heart; blue - catheter

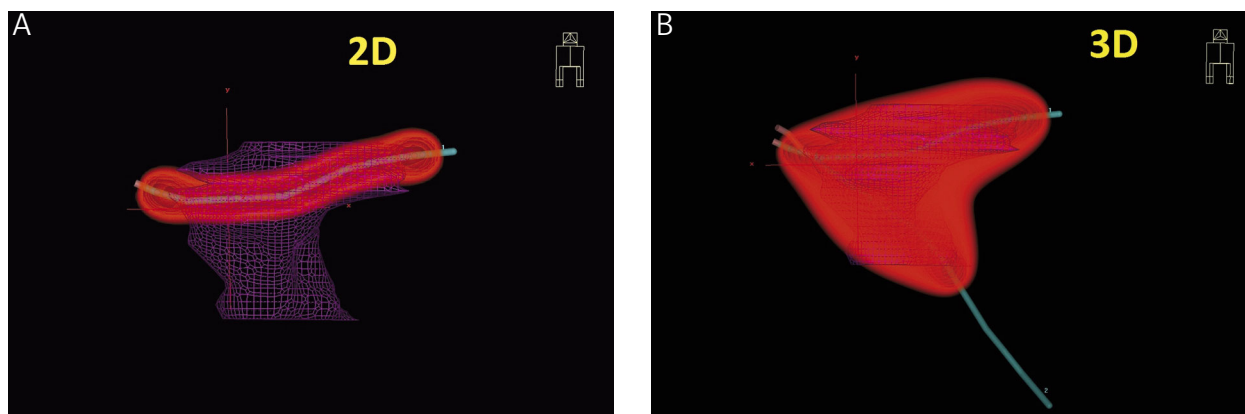


Fig. 2. A) Patient with two catheters inserted during regular 3D planning. For the 2D planning only one of them would be used (the one inserted into the bronchus with visible obturation). Comparison of GTV coverage by the 90% isodose achieved in 2D planning system. Legend: purple triangles - GTV volume; orange cylinder - 2D 90% isodose; blue - catheter. B) Patient with two catheters inserted. Comparison of GTV coverage by the 90% isodose achieved in 3D planning system. Legend: purple triangles - GTV volume; orange volume - 3D 90% isodose; blue - catheters

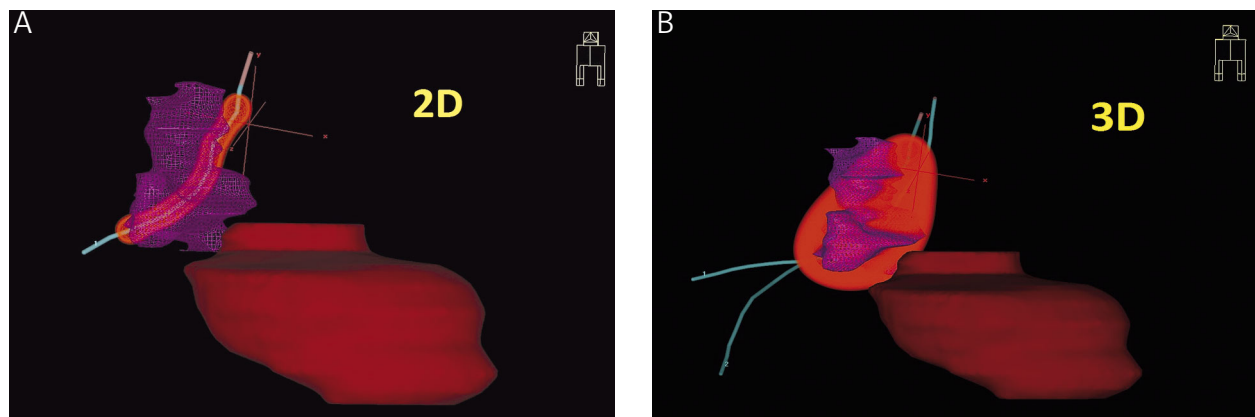


Fig. 3. A) Patient with three catheters inserted during regular 3D planning. For the 2D planning only one of them would be used (the one inserted into the bronchus with visible obturation). Comparison of GTV coverage by the 90% isodose achieved in 2D planning system. Legend: purple triangles – GTV volume; orange cylinder – 2D 90% isodose; brown – heart; blue – catheter. **B)** Patient with three catheters inserted. Comparison of GTV coverage by the 90% isodose achieved in 3D planning system. Legend: purple triangles – GTV volume; orange volume – 3D 90% isodose; brown – heart; blue – catheter

100%. In addition, it should be noted that in 3D planning we can spare critical organs and the pacemakers [7].

Due to the short observation time and a limited (pilot) group of patients the survival time as well as local effects were not a subject of analysis.

Discussion

Since the development of HDR brachytherapy techniques, many radiation oncologists have counted treatment of bronchial cancer as a field of interest. Experience of the 1980s and '90s showed the efficacy of the HDR technique, especially in palliative treatment. The introduction of stenting techniques at the turn of the century greatly reduced the use of brachytherapy. This was due to both the simplicity of endoscopic techniques, as well as a severe drop in prices of stents used in the treatment of neoplastic diseases of the bronchial tree. At the same time, the weakness of HDR brachytherapy was the use of 2D visualization, which greatly limited, and often prevented proper determination of the irradiated volume. The gradual introduction of imaging with the use of computed tomography, and particularly the introduction of so-called virtual bronchoscopy, has allowed the return of the application of HDR brachytherapy in the treatment of bronchial carcinoma. It is increasingly appearing in publications, showing a definite advantage with the use of CT 3D imaging over 2D imaging. It is the proof of the correct path of the choice of procedure.

Conclusions

Planning for HDR brachytherapy in all locations should be based on dynamic imaging at present. GEC-ESTRO recommendations explicitly mention that in centers that are equipped with computerized tomography, evaluation should be a routine test in treatment planning. The use of CT, even in palliative treatment planning, allows for much better coverage of GTV areas as well, which is very important, to reduce radiation doses to critical organs and thereby reduce the toxic effects of treatment undertaken. The prop-

er use of 3D planning assumptions in palliative treatment can be assessed after a longer period of observation and a larger group of patients treated using this technique of planning. It should also be noted that the use of 3D planning based on computed tomography does not extend the planning time greatly, and using modern image reconstruction algorithms allows one to perform virtual reconstructions. This type of equipment allows for non-invasive monitoring of tumor size directly before brachytherapy and with changes significantly obstructive of the bronchial tree, it is the only test for the actual definition of its extent (length of infiltration).

References

1. Makarewicz R. Brachyterapia HDR. *Via Medica*, Gdańsk 2004.
2. Skowronek J. Lung cancer brachytherapy. In: Lung Cancer Treatment. West BS, Stanley DR (eds.). *Nova Science Publishers Inc.* 2011.
3. Kazalski D, Gawełko J. High dose rate endobronchial brachytherapy effectively palliates symptoms due to inoperable lung cancer in elderly patients (over 65 y.o.). *J Contemp Brachyther* 2009; 1: 183 (abstract).
4. Senan S, Lagerwaard FJ, de Pan C on behalf of the Rotterdam Oncological Thoracic Study Group. A CT-assisted method of dosimetry in brachytherapy of lung cancer. *Radiother Oncol* 2000; 55: 75-80.
5. Nori D, Allison R, Kaplan B. High dose rate intraluminal irradiation in bronchogenic carcinoma. *Chest* 1993; 104: 1006-1011.
6. Fijuth J. HDR endobronchial brachytherapy in palliative and combined radical treatment of lung cancer. *J Contemp Brachyther* 2009; 1: 231-236.
7. Lagerwaard FJ, Murrer LHP, de Pan C et al. Mucosal dose prescription in endobronchial brachytherapy: a study based on CT-dosimetry. *Int J Radiat Oncol Biol Phys* 2000; 46: 1051-1059.
8. Hoskin P, Coyle C (eds.). *Radiotherapy in Practice – Brachytherapy*. 2 ed. *Oxford University Press*, Oxford 2011.
9. Kasproicz A, Łyczek J, Kulik A et al. Paliatywna jednofrakcyjna brachyterapia HDR w leczeniu zaawansowanego miejscowo raka oskrzeli. *Nowotwory* 1999; 49: 35-38 [In Polish].
10. Skowronek J, Kubaszewska M, Kanikowski M et al. HDR endobronchial brachytherapy (HDRBT) in the management of advanced lung cancer – comparison of two different dose schedules. *Radiother Oncol* 2009; 93: 436-440.