

Surgery combined with brachytherapy in patients with retroperitoneal sarcomas

Wirginiusz Dziewirski MD, PhD¹, Piotr Rutkowski MD, PhD, Ass. Prof.¹, Zbigniew I. Nowecki MD, PhD¹, Tadeusz Morysinski MD, PhD¹, Maciej Salamacha MD, PhD¹, Anna Kulik MD, PhD², Maria Kawczynska MD, PhD², Anetta Kasprzewicz MD, PhD², Jarosław Łyczek MD, PhD², Włodzimierz Ruka MD, PhD, Prof.¹

¹Department of Soft Tissue/Bone Sarcoma, Cancer Center and Institute of Oncology, ²Brachytherapy Department, Cancer Centre Institute Warsaw, Poland

Abstract

Purpose: The primary aim of this work was to analyze feasibility of combined treatment of retroperitoneal sarcomas (RS): surgery (S) and intraoperative brachytherapy (IOBRT). The secondary aim was to analyze results and complications after this treatment.

Material and methods: 84 patients with retroperitoneal sarcomas were qualified for combined treatment (S and IOBRT) between June 1998 and September 2006. 65 of the patients (77.4%) had local recurrences. Sarcomas with intermediate and high grade of histological malignancy (G2, G3 – 76.2%) were the most frequent within the all surgically treated patients. Resection ability (R0/R1) in analyzed group of patients was estimated as 85% (74 cases). After intraoperative evaluation, 57 (67.8%) patients were qualified for IOBRT. Since 2000, in 34 patients (60%) an adjuvant post-operative external beam radiation therapy (EBRT) in dose of 50 Gy was applied. Median follow-up of the surviving patients was 40 months.

Results: On the basis of the univariate analysis, relevant aspects negatively influencing overall survival rate within the RS group treated with IOBRT were as follows: surgery of sarcoma recurrence ($p = 0.002$), higher grade of histological malignancy ($p = 0.05$), histological type different than liposarcoma ($p = 0.05$) as well as no adjuvant EBRT ($p = 0.05$). On the basis of multivariate analysis one can ascertain that relevant factors negatively influencing LRFS in RS patients treated with IOBRT were: surgery due to recurrence of sarcoma ($p = 0.008$) and lack of EBRT ($p = 0.01$).

Conclusions: Combined treatment (surgery and brachytherapy) was possible to be carried out on 68% of RS patients. The overall number of complications was quite high, however acceptable, taking into consideration the application of extensive, multi-organ treatments in case of sarcoma recurrences in this localization. The results suggest that the method of treatment will improve the final outcome when most of patients will be qualified for treatment of primary sarcomas in experienced centre.

J Contemp Brachyther 2010; 2, 1: 14-23

Key words: brachytherapy, intraoperative, recurrence, retroperitoneal sarcoma, surgery.

Purpose

Soft tissue sarcomas belong to a rare type of malignant tumors deriving from connective tissue and originating mainly from mesodermal germ layer. Retroperitoneal sarcoma (RS) constitute for approximately 0,4% of all malignant tumors, which is about 15% of all sarcoma localizations [1]. The retroperitoneal space is very difficult for physical evaluation, mainly because the RS develops asymptotically thus attaining large size and is often detected accidentally during an examination of different matter. Surgery is the sole treatment modality that may lead to total cure of this type of tumor. Obtaining microscopic tumor-free radical margin restricts complicated

anatomic issues, lack of anatomic compartments, asymptomatic growth of the tumor and its large size, frequent infiltration and proximity of the vital organs. To reach the appropriate surgery margin without removal of the sarcoma in one piece with an adjacent organ is usually impossible.

Furthermore, during treatment of local recurrences the radical approach is possible in 60-70% of all cases with first or consecutive tumor recurrence [2-5]. The resection of adjacent organs is generally well-founded because of its technical rationale in radical surgery, rather than actual infiltration of the organ. Jacques *et al.* had shown the actual infiltration of kidney parenchyma in 2 out of 30 nephrectomies [6]. The NCI analysis conducted in 1975 demon-

Address for correspondence: Piotr Rutkowski, MD, PhD, Ass. Prof., Department of Soft Tissue/Bone Sarcoma, Cancer Center and Institute of Oncology, Cancer Centre – Institute, 5 Roentgen Street, Warsaw, Poland, phone: +48 22 546 21 72, fax: +48 22 643 97 91, e-mail: rutkowskip@coi.waw.pl

Received: 04.12.09
Accepted: 29.12.09
Published: 28.03.10

strated that patients with retroperitoneal sarcoma tend to experience local recurrences with intraperitoneal dissemination [7] rather than create metastases beyond abdomen cavity. The time of local recurrence is similar in all conducted analyses: Cantin *et al.* [8] presented in their publication that 80% of local recurrences occurred within 2 years, Simon and Ennecking [9] – 100% of local recurrences within 30 months, Lindberg *et al.* [10] – 80% of local recurrences within 2 years and 100% of local recurrences in 3 years, whereas Shiu *et al.* [11] observed 87% of local recurrences within 2 years.

Adjuvant radiotherapy is a standard procedure for extremities and integument sarcomas patients treated with radical surgery. In patients with extremities sarcoma the dose of the whole postoperative radiation field exceeds 60 Gy (60-80 Gy) [12]. Tepper *et al.* [13] showed excellent improvement of the local control in case of applying a dose level more than 60 Gy as compared to the dose below 50 Gy. Fein *et al.* [14] presented data that after application of a dose > 55 Gy the local control rate was 72%, while after dose < 55 Gy the local control was 38%. Comparable results were achieved by Catton *et al.* [15]. Applications of such doses are usually impossible in case of retroperitoneal sarcomas due to possible complications and difficult anatomic relations. In localization of retroperitoneal sarcomas a lot of critical organs are found: intestines, kidneys, liver and spinal cord. EBRT in high doses considerably increases serious complications, so the dose in retroperitoneal space rarely exceeds 45-50 Gy which is recognized as a well tolerated dose [16, 17]. However, this dose is too low for adjuvant treatment of soft tissue sarcomas. This explains the importance of combined treatment (surgery/radiotherapy) in order to achieve good local control. Based on the results and taking into consideration difficulties in achieving the accurate surgery margins and high percentage of local recurrences in retroperitoneal sarcomas, determine the use of adjuvant radiotherapy in the case of retroperitoneal sarcomas also. The idea of interstitial irradiation is to deliver a High Dose Rate dose (HDR) directly into tumor tissues or to the site of removed tumor which increases of the therapeutic index without the necessity of exposing the organ at risk due to EBRT complications. In treatment of retroperitoneal sarcomas, the range of radiation doses used in different centers of the world is quite large and differ from 8,75 to 30 Gy, however doses used in most of the centers vary from 10 to 20 Gy [17-23]. The data relates to cases with previous application of EBRT or planned postoperative adjuvant radiotherapy.

The aim of this work was to evaluate the effectiveness of combined treatment (surgery + IOBRT/EBRT), complications of this type of treatment, results of overall survival rate and local recurrence rate in retroperitoneal sarcoma patients.

Material and methods

Material

In 1998 Department of Soft Tissue/Bone Sarcoma (DSTBS), Cancer Center and Institute of Oncology started a prospective study about the estimation of possibilities and results for intraoperative brachytherapy (IOBRT) after

radical surgery of retroperitoneal sarcoma. In 2000 the Centre started a treatment with the use of additional adjuvant EBRT for patients treated with combined treatment (surgery/intraoperative brachytherapy). The treatment protocol of the study was accepted by Bioethics Committee of M. Skłodowska-Curie Cancer Center and Institute of Oncology in Warsaw. Before entering the trial, every patient was obliged to give his written consent for participation in the study. From June 1998 to September 2006, 84 retroperitoneal sarcoma patients were qualified for combined treatment (surgery + IOBRT). Retroperitoneal sarcoma was confirmed in all 84 patients by obtaining histopathology results, CT scan, X-ray, abdomen cavity and pelvis MRI. Surgery was performed in 49 women and 35 men. The age ranged from 17-78 (median 50): 17-75 for women (median 51), 22-78 for man (median 49). In the whole group of patients only 19 (22.6%) of cases with retroperitoneal sarcoma were previously diagnosed and primarily treated at the Institute of Oncology. The remaining 77.4% experienced recurrences of retroperitoneal sarcoma and were operated (sometimes even several times) in other Centers and eventually guided to DSTBS. The largest diameter of most treated tumors (94.1%) exceeded 5 cm (range 4-23 cm; median tumor size 15 cm) (Fig. 1). In this group the majority of sarcomas were with intermediate and high histological malignance grade (G2, G3 – 76.2%), the most common type of sarcomas were liposarcoma – 46 cases (54.8%) and leiomyosarcoma – 11 patients (13.1%). After radical surgery, 57 patients (67.8%) had undergone BRT.

Brachytherapy

HDR units: Gammamed 12i[®] and MicroSelectron[®] were used for intraoperative irradiation. Iridium -192 was used with nominal activity 10 Ci, applied through HAM (Harrison Anderson Mick) flap applicator. The treatment planning was done with the use of ABACUS 3.0 treatment planning system (earlier, version 1.6 was used instead) on a 3D platform. The range of therapeutic beam penetration was

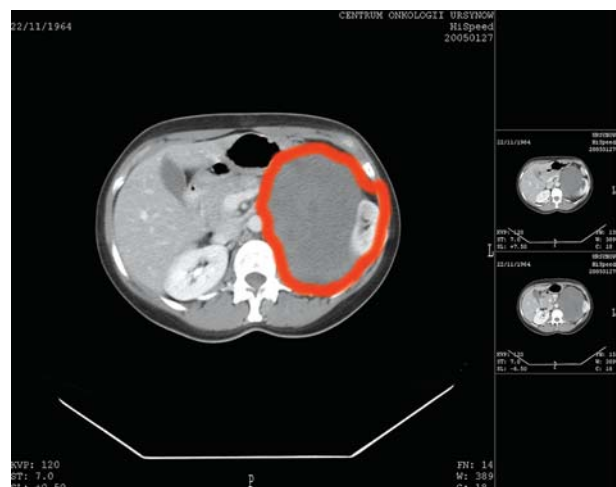

Fig. 1. CT scan of retroperitoneal sarcoma prepared for EBRT planning and extent of surgery (tumor and left kidney, tumor outlined in red line)

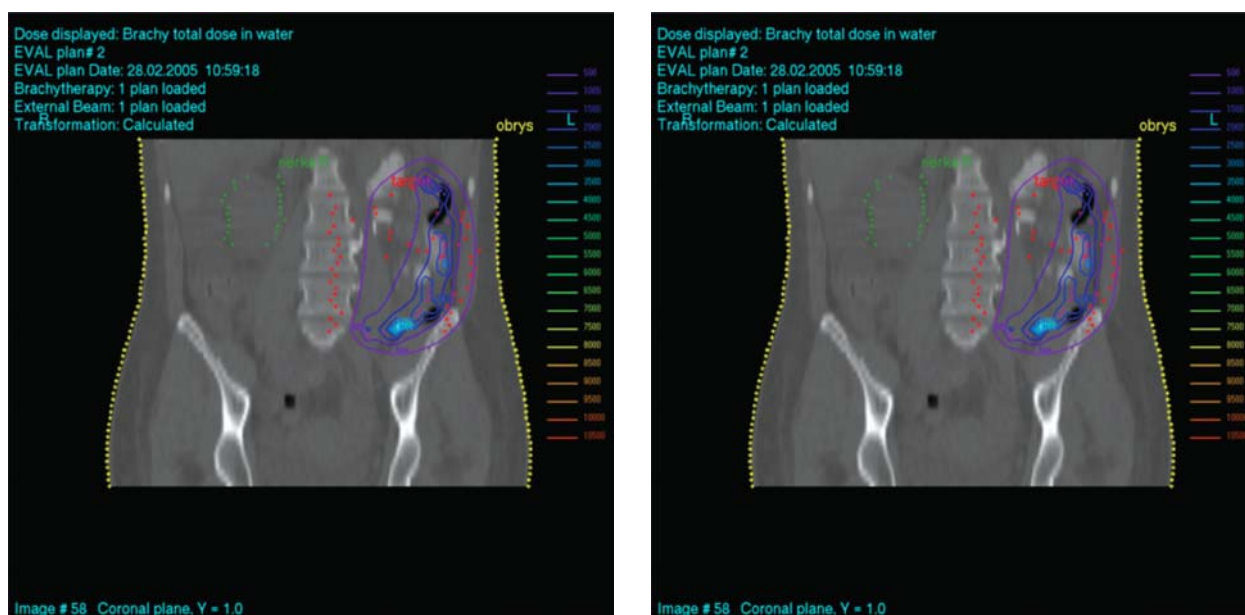


Fig. 2. Brachytherapy planning - dose distribution for a frontal plane

set on the basis of intraoperative radiologic test that did not exceed 1 cm from the applicator surface. The single dose of 20 Gy was delivered to the treatment volume with 1 cm margins (Figs. 2 and 3). In case of insufficient hemodynamic parameters such as high amount of blood loss, irradiation was not applied in the day of surgery. The abdominal cavity was closed, but packing (cotton cloth) was placed on location where organ removal occurred and triggered ambiguous homeostasis. Eventual packing removal was done after 1-3 days. Since 2000, the additional postoperative EBRT radiation after IOBRT was applied meanly after 30 days from combined retroperitoneal sarcomas/IOBRT surgery. EBRT planned dose of site and postoperative scar was 50 Gy in 1.8 Gy fractions.

The clinical and pathological parameters examined for prognostic value within the group undergoing IOBRT were tumor size (divided into two groups: < 10 and > 10 cm), histological malignancy grade of tumor (low grade G1 vs. high grade G2 or G3), histological tumor type (liposarcoma vs. others), sex, one-time resection with a contiguous organ (zero additional organs, one organ, and more than one organ), number of previous operations (zero, one, or more than one), and subsequent EBRT. We did not include the microscopic status of resection margins R0 vs. R1 in this analysis, because the probability of reliable estimation found mostly in recurrent retroperitoneal sarcomas is doubtful.

Follow-up

Postoperative follow-up consisted of physical examination and routine imaging investigations such as computed tomography and ultrasonography of the abdominal cavity as well as chest X-ray/X-rays. Observations were assessed and analyzed every 3 months for the first 2 years, then in the 3rd to 5th year period - every 6 months, and annually thereafter. The median follow-up time was

40 months for survivors (range: 8-100 months) and for IOBRT patients - 39 months (range: 8-82 months).

Statistical analysis

Overall survival (OS) time was calculated from the date of operation at the study institution to the date of the most recent follow-up or death. The local recurrence free survival (LRFS) time was estimated from the date of retroperitoneal sarcoma excision to the date of the most recent follow-up or local retroperitoneal sarcomas recurrence. For prospective data collection, the hospital system Oncosys was applied. Statistical analysis was performed using Statistica® software (StatSoft, Tulsa, OK). In univariate analysis survival rate was assessed using the Kaplan-Meier method in combination with the log-rank test. Multivariate analysis for overall survival was performed with the use of proportional hazard Cox regression model. Differences were considered statistically significant if p values were < 0.05.

Results

74 (85%) patients qualified for retroperitoneal surgery of sarcoma underwent radically macroscopic surgery. The estimated 5-year OS for the entire group of retroperitoneal sarcomas patients after radical macroscopic resection was 41% (median survival time: 48 months), and the evaluated 5-years LRFS was 61%. In the total group of patients with retroperitoneal sarcoma it was necessary to remove another organ along with the tumor in 79% of patients (60/74 cases with R0/R1 resection) - one organ in 20 patients and more than 1 organs in 40 patients. Within the IOBRT group, there was a total of 75% of patients (43 cases) were removal was performed - one organ in 11 patients (19.2%) and more than 1 organ in 32 patients (56.1%). The most often removed organ was as follows:

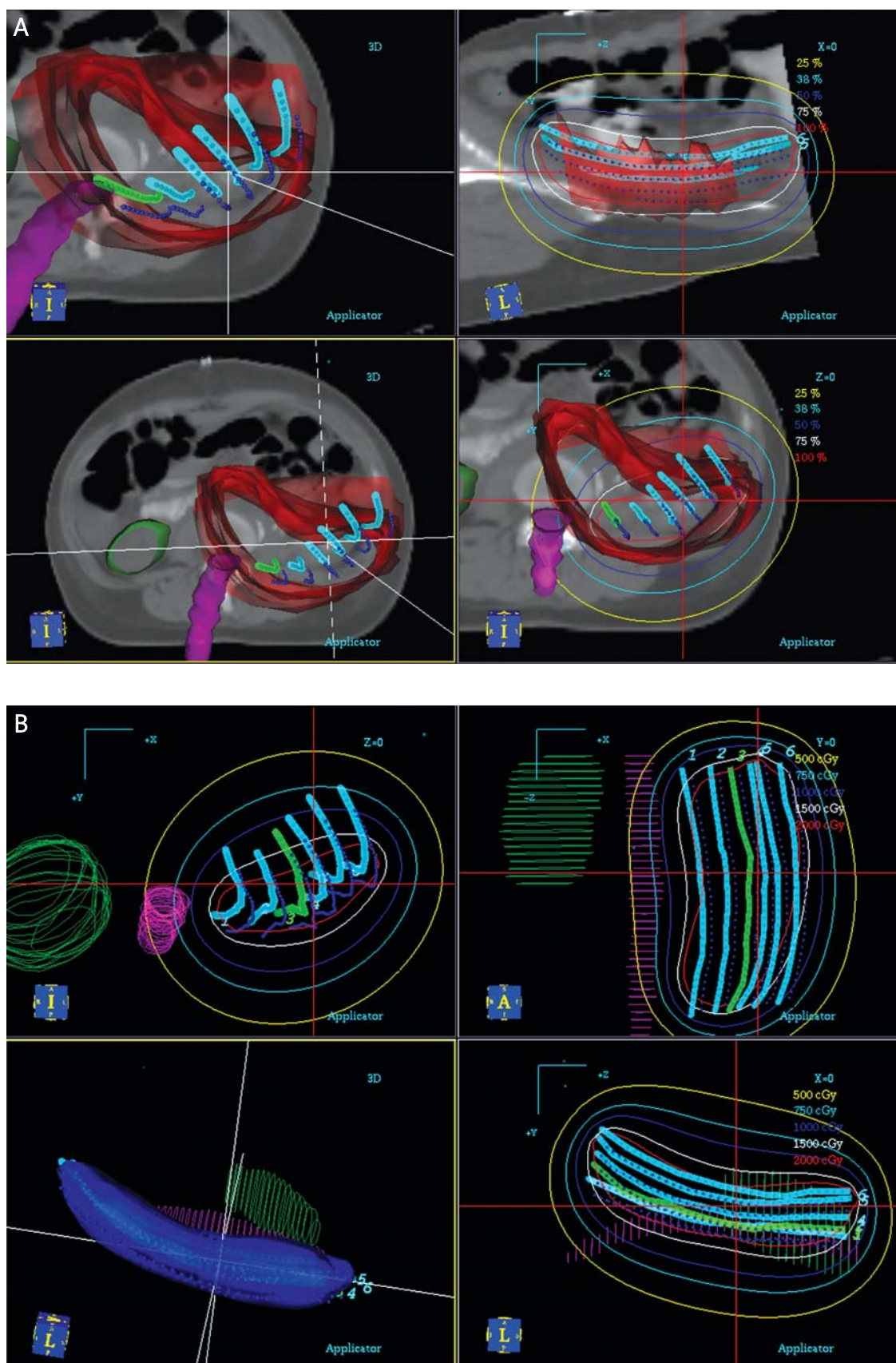


Fig. 3. Intraoperative brachytherapy planning. A) 3D image of HAM applicator position, B) Dose distribution and HAM applicators location

Table 1. Clinical characteristics of 57 retroperitoneal sarcoma patients treated with intraoperative brachytherapy

Clinical data	Number of patients, rate (%)
Sex:	
Female	31 (54.4%)
Male	26 (45.6%)
Age [years] (range; median):	17-78; 50
Female	17-75; 49
Male	22-78; 50
Greatest size of sarcoma:	
≤ 10 cm	22 (26%)
> 10 cm	62 (74%)
Malignancy grade (G)	
G1	19 (33.3%)
G2	14 (24.6%)
G3	24 (42.1%)
Histopathology:	
liposarcoma	35 (61.4%)
leiomyosarcoma	5 (8.8%)
malignant peripheral nerve sheath tumor	5 (8.8%)
others	12 (21.0%)
Surgery:	
Primary tumour	15 (26.3%)
Recurrence	42 (73.7%)
Previous surgery:	
0	15 (36.3%)
1	36 (63.2%)
>1	6 (10.5%)
Number of resected organs during RS surgery:	
0	14 (24.5%)
1	11 (19.3%)
>1	32 (56.2%)
Intraoperative brachytherapy:	
simultaneous	48 (84.21%)
delayed	9 (15.8%)
External Beam Radiation Therapy (after surgery)	34 (60%)

kidney (39 cases), large intestine (28 cases), small intestine (10 cases), ovary (8 cases), spleen (7 cases) and iliopsoas (6 cases).

57 patients (67.8%) were ultimately qualified for BRT, out of which 48 patients (84%) underwent one-time BRT at the time of surgery, directly after removal of retroperitoneal sarcoma, whereas 9 patients (16%) underwent IOBRT in 1-3 days after retroperitoneal sarcoma removal due to poor parameters at the time of surgery. For reasons of high amount of blood loss and/or hemodynamical disorders, the patients were not able to receive one-time BRT on the day of surgery.

The remaining group of 27 patients (32.2%) was disqualified from IOBRT. This group consisted of 20 women and 7 men. Within this group only 4 patients (14.8%) had primary sarcomas that were diagnosed at the DSTBS, while the remaining 85.2% cases were qualified for treatment as

recurrences after previously completed surgery and EBRT outside our Clinic.

The reasons for IOBRT disqualification were as follows:

- multifocal changes undetected during preoperative imaging evaluations: 11 patients,
- non-radical resection: 5 patients,
- tumor localized on large vessels: 4 patients,
- circulatory failure and high amount of blood loss during surgery: 3 patients,
- liver metastases confirmed intraoperatively 2 patients,
- irradiation before CO-I: 2 patients.

Analysis of IOBRT group of patients

57 patients received IOBRT. The data of IOBRT patients are presented in Table 1. The final resection margins were evaluated as radically microscopic (R0) in 37 cases (65%), while tumor infiltration in microscopic investigation of resection margins (R1) was confirmed in 20 cases (35%).

Different number of applicators was used because of the diameter of the field (ranged from 4 to 19). The total irradiation time ranged from 20 to 87 minutes with mean value of 56 min. In two patients it was necessary to install two HAM applicators due to large radiation fields requiring two applicators with 10 adapters (6 and 9 adapters were used) in asymmetrical position. During 30 days after surgery one patient died (1.2%). Surgery was necessary in 10 patients (17.5%) due to postoperative complications after IOBRT which included intraperitoneal abscess (2 cases), fecal fistula (2 cases), wound dehiscence (2 cases), adhesive mechanical ileus (1 case), duodenal fistula (1 case), hemorrhage (1 case), and massive hydroperitonitis (1 case). The complications appeared only in patients operated due to recurrences of retroperitoneal sarcoma. In the group of patients after adjuvant EBRT (34 cases), the most common late complication was symptoms of chronic, recurrent mechanical sub-ileus of intestine (6/34 patients: 17.6%). Two patients in late postoperative periods underwent surgery due to mechanical ileus symptoms (in one case with accompanying intestinal fistula: the patient died because of complications), in 15 and 26 months after the primary BRT and surgery. In a distant period of time, one abscess and rib necrosis in field of EBRT occurred. Two patients were complaining about symptoms of peripheral neuropathy.

The estimated 5 year overall survival (OS) in group of 57 patients after IOBRT was 50% (mean value: 58 months) (Fig. 4). At the end of follow-up, 30 patients were alive (53%), 18 (32%) died due to progression of the disease, while 8 patients (14%) died from reasons not associated with sarcoma progression (5 cases - all medical reasons, mainly circulatory system; 3 cases - treatment complications).

In univariate analysis the important factors negatively influenced the OS of patients with retroperitoneal sarcoma under IOBRT were as follows: sarcoma recurrence surgery ($p = 0.002$) (Fig. 5), higher grade of sarcoma histological malignancy ($p = 0.005$) (Fig. 6), histological type different than liposarcoma ($p = 0.05$) and lack of adjuvant therapy of EBRT ($p = 0.05$) (Table 2). In multivariate analysis, the independent factors of OS were: sarcoma recurrence surgery ($p = 0.02$) and histological type different than

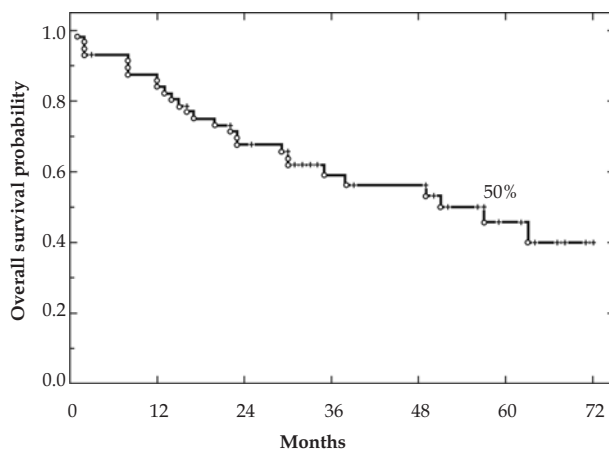


Fig. 4. Overall Survival (OS) of patients with retroperitoneal sarcomas in IOBRT group

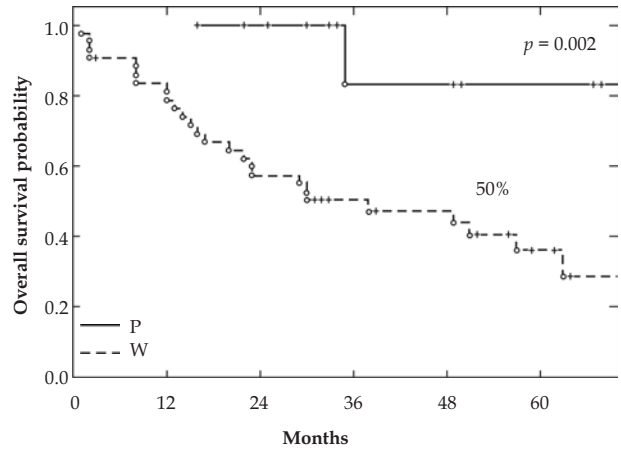


Fig. 5. Overall Survival (OS) of retroperitoneal sarcoma patients in IOBRT group according to prime tumor surgery (P) or recurrence surgery (W)

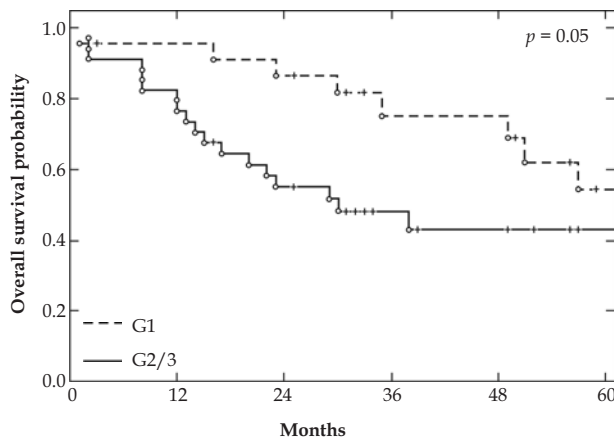


Fig. 6. Overall Survival (OS) of retroperitoneal sarcomas patients treated with IOBRT according to histological grade of sarcoma malignancy

Table 2. Prognostic factors influencing overall survival (OS) and local recurrence free survival (LRFS) after brachytherapy (BRT) – univariate analysis

Prognostic factor	OS	LRFS
	P value	
Malignancy grade (G1 vs G2/3)	0.05	n.s.
Histopathological type (liposarcoma vs inne)	0.05	n.s.
Previous surgery (0, ≥1) [primary tumour vs recurrence]	0.002	0.008
EBRT postoperative vs no EBRT	0.05	0.01
Size of sarcoma (≤ 10 cm vs. > 10 cm)	n.s.	n.s.
Sex	n.s.	n.s.
Number of resected organs (0, 1, > 1) during RS surgery	n.s.	n.s.

n.s. – statistically no significant

liposarcoma ($p = 0.04$) (Table 3). The actual 3-year overall survival rate was 82% for patients operated due to primary retroperitoneal sarcoma and 50% for patients operated due to recurrence of retroperitoneal sarcoma, previously operated in another clinic; OS reached 76% in retroperitoneal sarcoma group of patient with G1 histological grade of

malignancy, compared with 48 % for G2/G3 tumors; 71% – for liposarcoma patients, compared with 37% for other histological sarcomas; 70% – for additional postoperative radiotherapy patient, compared with 43,5% of patients without additional EBRT. No substantial differences in overall survival rate was noticed regarding the size of oper-

Table 3. Independent prognostic factors for overall survival rates in retroperitoneal sarcomas, treated with intra-operative brachytherapy – multivariate analysis

Unfavorable prognostic factors	Hazard ratio	Wald ratio	Standard error	P value
Surgery due to recurrent tumour	10.2	4.99	1.03	0.02 ¹
Histopathological type other then liposarcoma	1.15	4.16	0.05	0.04 ¹
Malignancy grade G2/G3	1.31	0.40	0.43	0.52
Lack of postoperative EBRT	1.69	1.81	0.39	0.18

¹statistically important

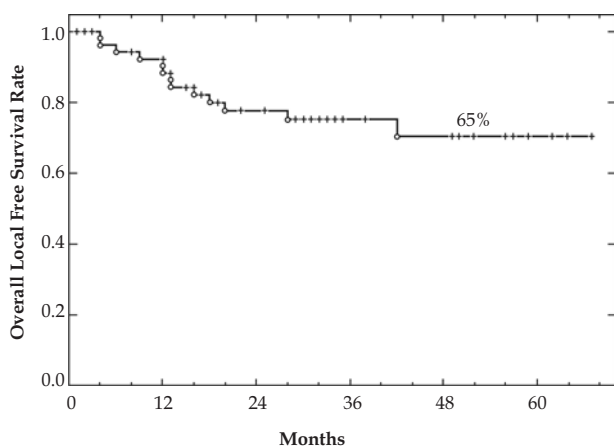


Fig. 7. Overall Local Recurrence Free Survival in retroperitoneal sarcoma patients treated with IOBRT

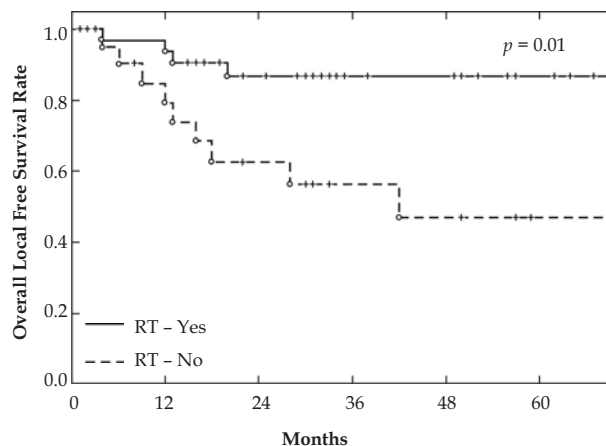


Fig. 8. Overall Local Recurrence Free Survival in patients with retroperitoneal sarcoma treated with IOBRT according to adjuvant postoperative EBRT

ated tumor, sex and the number of removed adjoining organs (Table 2). The estimated 5-year local recurrence free survival (LRFS) in 57 patients after IOBRT was 65% (Fig. 7).

On the basis of univariate analysis, the significant factors negatively inclined LRFS of retroperitoneal sarcoma patients after IOBRT were: sarcoma recurrence surgery ($p = 0.008$) and lack of EBRT ($p = 0.01$) (Fig. 8). The multivariate LRFS analysis was not carried out in regards to methodological limitation.

The actuarial 3-year LRFS was 100% for patients operated due to primary retroperitoneal sarcoma and only 66% for patients operated due to recurrence of retroperitoneal sarcoma that were previously operated in different clinic. LRFS reached 87% in patients with postoperative radiotherapy compared with 57% of patients without additional radiotherapy. No significant differences were estimated in LRFS regarding the size of operated tumor, sarcoma malignancy grade, histological type, sex and the number of removed adjacent organs (Table 2).

24 cases (42%) of recurrences were noticed: liver recurrences ($n = 3$; 12.5%), lung recurrences ($n = 3$; 12.5%), bone recurrence ($n = 1$; 4%) – mainly local and intraperitoneal recurrences.

Since 2000, a total number of 34 patients qualified for treatment (60% of all) and additional EBRT was performed (usually in 30 days after the main combined IOBRT/surgery; in most of the cases the time gap was larger due to wound-healing process and radiation planning procedure). Some patients were disqualified from postoperative radiotherapy due to following reasons: previous radiotherapy given in another clinic, bad general condition, intestine fistula, disease progression. All patients, with the exception of 3 (one case of no-tumor related neurological disorders, one case of radiation induced enteronitis and one patient's resignation from further participation in the study after reception of 36 Gy dose) received presumed dose of 50 Gy.

Discussion

Retroperitoneal sarcomas are a rare group of malignant cancers usually with bad prognosis [24]. However, series

of publications were released with multiple sets of data regarding the treatment results of patients with this type of cancer. [18, 23-32]. It seem like the best option for the longest distant survival rate is a radical resection during the primary surgery of retroperitoneal sarcoma [6, 18, 32, 33]. However, such surgery is not always possible due to large size of the tumor and deep infiltration of adjoining organs. Distant metastases of retroperitoneal sarcomas are rare [33]. In most cases the reason for failure of treatment is local recurrence. Such observation is confirmed by results of this study in which over 70% of recurrences can be qualified as local recurrences. This is to imply that the upgrading of local treatment can be transmitted into a better cure rate. Furthermore, strong scientific evidence confirms that additional EBRT improves local control with association of surgery in trunk or extremities sarcoma locations, with absence of microscopically radical margins [19, 34]. Similar publications regarding combined treatment (surgery and EBRT) in retroperitoneal sarcoma demonstrate decrease of local recurrences rate [14, 35, 36]. Series of studies where EBRT was used in adult soft tissue sarcoma patients show precise correlation with percentage of local recurrence and radiation dose [34, 37]. The effective therapeutic dose (above 60 Gy) is not possible to be acquired in case of retroperitoneal sarcoma due to tumor proximity with organs at risk such as intestines, parenchyma organs and large vessels in potential radiation field.

Intraoperative radiation with the use of electron accelerator or HDR BRT (used in our Clinic) is the alternative way of treatment to EBRT in case of soft tissue sarcoma with high malignancy level [26, 38, 39]. Brachytherapy allows high radiation dose application on site of removed sarcoma (place of high risk of local recurrence) and at the same time secures from unnecessary irradiation of critical organs that could be found in the radiation field [22, 26, 35, 39]. Theoretical advantage of brachytherapy is a direct visualization of a treated field that allows better control of irradiated area and the usage of higher radiation dose. Biological effectiveness of such sole dose results in 2 to 5 times better efficiency than in case of dose fractionation in traditional way (directly into site of removed sarcoma) [40].

Such way of radiation allows effective saving of surrounding tissues in comparison with preoperative or postoperative radiotherapy. IOBRT can be combined with EBRT and therefore making it possible to increase the total radiation dose to more than 65 Gy. Such proceedings theoretically allow significant improvement of local control [29, 37].

In our study, one of the largest in the world, 68% of patients operated for retroperitoneal sarcoma received IOBRT. Furthermore, 60% of patients received additional postoperative BRT. It is difficult to establish the complications of radiotherapy due to series of complexities connected to extensive and prolonged surgical treatment or towel pressure (ischemia), isolating critical organs from intraoperative field irradiation. Frequently, the surgical procedures were very extensive, demanding removal of adjoining organs along with sarcoma (80% of cases). This is to imply that such type of procedure should be performed in specialized and experienced centres by qualified anesthesiologists, radiotherapists and oncologists surgeons. The reports regarding benefits of BRT application in soft tissues sarcoma treatment are still ambiguous [34, 35]. The results of this study correlate with some uncommon findings from other medical centers. They show the tendency to improve local control with the use of intraoperative radiotherapy [22, 36].

Somewhat different matter of substance constitutes BRT combined with EBRT. In case of sarcomas with extracompartmental localization such as retroperitoneal sarcomas and local recurrences, it might be essential to apply larger spectrum of radiation like BRT combined with EBRT [35]. EBRT can be used as an addition to pre- or post-operative treatment [15, 16, 21, 22, 36, 41-44]. In the original study protocol presented within this work, EBRT was employed as an additional postoperative treatment after IOBRT application. Furthermore, obtained results of such additional therapy application appear to be necessary in combined treatment of retroperitoneal sarcomas. Within the group of postoperative additional EBRT patients, local control of tumor and better (70%) overall survival rate was significantly achieved. The combination of these two radiotherapy techniques permits to achieve appropriate large total therapeutic dose. The possibility of preoperative additional radiotherapy application in case of retroperitoneal sarcomas remains debatable. Theoretically, such type of treatment could bring certain benefits in consideration of common delays or disqualification for postoperative EBRT due to concurrent complications in extensive surgeries, as well as improved definition of radiation field with the use of preoperative radiotherapy [45, 46]. Other methods of treatment including systematic chemotherapy (except microcellular sarcomas of Ewing's sarcomas) or intraperitoneal therapy do not present significant influence in treatment improvement.

Overall survival rate or local recurrence survival of the studied group of patients are comparable with other international results of analyzed group of retroperitoneal sarcomas patients. However, the majority of literature information are formulated on the basis of small group of

patients with divergent data (5 year survival rate oscillating between 12% to 70%) [6, 15, 18, 23, 25, 32, 33, 47-59]. Moreover, it is difficult to find present - day data of patients treated with surgery as a sole way of treatment. The analysis published by Royal Marsden Hospital in London [18] revealed that 20% of 5-year survival, whereas in our study 5-year survival in brachytherapy patients is 50%. What is also significant, other Polish results of surgically treated retroperitoneal sarcomas patients with no extensive, multi-organ "en-bloc" resection and IOBRT/surgery, showed only 34% of 5-year overall survival and 23% of 5-year of asymptomatic survival [52]. This results seem to be much worse than in our group of patients. Storm and Mahvi [60] demonstrated 72% of 5-year local recurrence free survival in group of 204 of retroperitoneal sarcomas patients after macroscopic radical surgical treatment. This study correlates findings of our group of patients as 65% of 5-year local recurrence free survival after intensive surgical treatment combined with IOBRT.

Surgical procedure allowing "en-bloc" sarcoma removal along with at least one of adjoining organs in order to obtain large margin of resection, enables significant improvement of retroperitoneal sarcomas treatment results [53, 55]. Apart from histological malignancy level, the quality of surgical treatment represents the most significant factor to influence the results of retroperitoneal sarcomas treatment. Recently published analyses of French and Italian scientists confirm this observations [55, 61-64].

The group of patients in our study mostly consisted of patients with high histological malignancy level of sarcomas. The histological malignancy level is the most important prognosis factor for overall survival in soft tissue sarcoma patients as well as in retroperitoneal sarcomas patients [53, 57, 59, 65] confirmed by above data. Majority of patients were operated not because of primary sarcoma, but due to local recurrence after ineffective treatment beyond our Centre. Unfortunately, treatment of local recurrence is associated (in significant percentage of cases) with consecutive local recurrence. In group of patients presented in international literature, the predominated group consisted of patients operated primarily not due to recurrence [32, 54, 56-58]. In our study we confirmed that treatment of primary retroperitoneal sarcomas is one of the major factor influencing prognosis (on the basis of multivariate analysis with its limitation resulting from numerical amount of cases in analyzed group). The results of our study present that in order to achieve such good treatment results, despite significantly substantial amount of patients operated due to recurrence of retroperitoneal sarcoma, is associated with the application of IOBRT followed by postoperative EBRT.

Under ideal circumstances, patients with primary retroperitoneal sarcoma should be instantly directed for combined treatment. It is important to emphasize that the appropriate planning of the treatment procedure and realization of planned therapeutic protocol in centers with adequate experience in this field is the major factor that influence the improvement of results of overall survival and local recurrence free survival in patients with retroperitoneal sarcoma.

Conclusions

The case study formulation of combined treatment of retroperitoneal sarcoma patients was evaluated on the basis of one – centre group of sarcoma patients qualified for combined treatment (surgery + IOBRT) and it was possible to conduct in 68% of patients. Additional EBRT is a necessary procedure in order to diminish local recurrences. Presented results: 50% of 5-year OS and 65% of 5-year LFRS are comparable with the results of major international oncologic centers. The outcomes account for the necessity of further investigations in order to improve the effects of combined retroperitoneal sarcoma treatment. The amount of complications in our study is quite high, however acceptable, taking into consideration very extensive, multi-organ surgical procedures with frequent cases of local recurrences. Presented analysis show that the improvement of treatment results in retroperitoneal sarcoma patients is genuinely achievable in case of primal treatment performed in high- specialist oncologic centre with possible application of brachytherapy and radiotherapy as well as experience and appropriate knowledge in treatment of retroperitoneal sarcoma patients.

Acknowledgments

The study was presented partially as PhD thesis in M. Skłodowska-Curie Memorial Cancer Center-Institute by Dr Wirginiusz Dziewirski.

References

1. Wojciechowska U, Didkowska J, Tarkowski W et al. Nowotwory złośliwe w Polsce w 2004 roku. Cancer Centre – Institute, Warsaw, Poland 2006 [in Polish].
2. Lewis JJ, Leung D, Woodruff J et al. Retroperitoneal Soft-Tissue Sarcoma. Analysis of 500 Patients Treated and Followed at a Single Institution. *Ann Surg* 1998; 228: 355-365.
3. Enzinger FM, Winslow DJ. Liposarcoma. A study of 30 cases. *Virchows Arch [A]* 1968; 335: 367-388.
4. Kearney MM, Soule EH, Ivins JC. Malignant fibrous histiocytoma. A retrospective study of 167 cases. *Cancer* 1980; 45: 167-178.
5. Weiss SW, Enzinger FM. Malignant fibrous histiocytoma. An analysis of 200 cases. *Cancer* 1978; 41: 2250-2266.
6. Jaques DP, Coit DG, Hajdu SI et al. Management of primary and recurrent soft-tissue sarcoma of the retroperitoneum. *Ann Surg* 1990; 212: 51-59.
7. Hellman S, Rossenber SA. Chapter 42: 1436-1488. In: *Cancer: Principles & Practice of Oncology, Fourth Edition*; edited by Vincent T. DeVita Jr. Copyright by J.B. Lippincott Co., Philadelphia 1993.
8. Cantin J, McNeer GP, Chu FC et al. The problem of local recurrence after treatment of soft tissue sarcoma. *Ann Surg* 1968; 168: 47-53.
9. Simon MA, Enneking WF. The management of soft tissue sarcomas of the extremities. *J Bone Joint Surg [Am]* 1976; 58: 317.
10. Lindberg RD, Martin RG, Romsdahl MM. Surgery and postoperative radiotherapy in the treatment of soft tissue sarcomas in adults. *Am J Roentgenol Radium Ther Nucl Med* 1975; 123: 123-129.
11. Shiu MH, Castro EB, Hajdu SI et al. Surgical treatment of 297 soft tissue sarcomas of the lower extremity. *Ann Surg* 1975; 182:597.
12. Spiro IJ, Suit HD. Soft tissue sarcomas. Chapter 11: 565-582. In: *Clin Radiat Oncol: Indications Techniques and Results*. 2nd ed. Edited by C. C. Wang. Wiley-Liss, Inc. 2000.
13. Tepper JE, Suit HD, Wood WC et al. Radiation therapy of retroperitoneal soft tissue sarcomas. *Int Radiat Oncol Biol Phys* 1984; 10: 825-830.
14. Fein DA, Corn BW, Lanciano RM et al. Management of retroperitoneal sarcomas: dose escalation impact on locoregional control? *Int J Radiat Oncol Biol Phys* 1995; 31:129-134.
15. Catton CN, O'Sullivan B, Kotwall C et al. Outcome and prognosis in retroperitoneal soft tissue sarcoma. *Int J Radiat Oncol Biol Phys* 1994; 29: 1005-1010.
16. Gilbeau L, Kantor G, Stoeckle E et al. Surgical resection and radiotherapy for primary retroperitoneal soft tissue sarcoma. *Radiother Oncol* 2002; 65: 137-143.
17. Gieshen HI, Spiro IJ, Suit H et al. Long-term results of intraoperative electron beam radiation therapy for primary and recurrent retroperitoneal soft tissue sarcoma. *Int J Radiat Oncol Biol Phys* 2001; 50: 127-131.
18. Jenkins MP, Alvaranga JC, Thomas JM. The management of retroperitoneal soft tissue sarcomas. *Eur J Cancer* 1996; 32A: 622-626.
19. O'Sullivan B, Ward I, Catton C. Recent advances in radiotherapy for soft-tissue sarcoma. *Curr Oncol Rep* 2003; 5: 274-281.
20. Bobin JY, Al-Lawati, Stoeckle E et al. Surgical management of retroperitoneal sarcomas associated with external and intraoperative electron beam radiotherapy. *Eur J Surg Oncol* 2003; 29: 676-681.
21. Petersen IA, Haddock MG, Donohue JH et al. Use of intraoperative electron beam radiation in the management of retroperitoneal soft tissue sarcoma. *Int J Radiat Oncol Biol Phys* 2002; 52: 469-475.
22. Sindelar WF, Kinsella TJ, Chen PW et al. Intraoperative radiotherapy in retroperitoneal sarcomas. Final results of prospective, randomized, clinical trial. *Arch Surg* 1993; 128: 402-410.
23. Ferrario T, Karakousis CP. Retroperitoneal sarcomas: grade and survival. *Arch Sur* 2003; 138: 248-251.
24. Herman K, Kusy T. Retroperitoneal sarcoma-the continued challenge for surgery and oncology. *Surg Oncol* 1999; 7: 77-81.
25. Lewis JJ, Leung D, Woodruff JM et al. Retroperitoneal soft tissue sarcoma. Analysis of 500 patients treated and followed at a single institution. *Ann Surg* 1998; 14: 859-868.
26. Pisters PW, Harrison LB, Leung DH et al. Long-term results of a prospective randomized trial of adjuvant brachytherapy in soft tissue sarcoma. *J Clin Oncol* 1997; 14: 859-868.
27. Heslin MJ, Lewis JJ, Nadler E et al. Prognostic factors associated with long-term survival for retroperitoneal sarcoma: implication for management. *J Clin Oncol* 1997; 15: 2832-2839.
28. Jones JJ, Catton CN, O'Sullivan B et al. Initial results of a trial of preoperative external beam radiation therapy and postoperative brachytherapy for retroperitoneal sarcoma. *Ann Surg Oncol* 2002; 9: 346-354.
29. Wang YN, Zhu WQ, Shen ZZ et al. Treatment of locally recurrent soft tissue sarcomas of the retroperitoneum: report of 30 cases. *J Surg Oncol* 1994; 56: 213-216.
30. Hassan I, Park SZ, Donohue JH et al. Operative management of primary retroperitoneal sarcomas: a reprisal institutional experience. *Ann Surg* 2004; 239: 244-250.
31. Chiappa A, Zbar AP, Biffi R et al. Primary and recurrent retroperitoneal sarcoma: factors affecting survival and long-term outcome. *Hepatogastroenterology* 2004; 51: 1304-1309.
32. Gronchi A, Casali PG, Fiore M et al. Retroperitoneal soft tissue sarcomas: patterns of recurrence in 167 patients treated at single institution. *Cancer* 2004; 100: 2448-2455.
33. Cody HS, Turnbull AD, Fortner JG et al. The continuing challenge of retroperitoneal sarcomas. *Cancer* 1981; 47: 2147-2152.

34. Strander H, Turesson I, Cavallin-Stahl E. A systematic overview of radiation therapy effects in soft tissue sarcomas. *Acta Oncol* 2003; 42: 516-531.
35. Ballo MT, Lee AK. Current results of brachytherapy for soft tissue sarcoma. *Curr Opin Oncol* 2003; 15: 313-318.
36. Van Doorn RC, Gallee MPW, Hart AAM et al. Resectable retroperitoneal soft tissue sarcoma. The effect of extent of resection and post-operative radiation therapy on local tumor control. *Cancer* 1994; 73: 637-642.
37. Zagars GK, Ballo MT. Significance of dose in postoperative radiotherapy for soft tissue sarcoma. *Int Radiat Oncol Biol Phys* 2003; 56: 473-481.
38. Nag S, Hu KS. Intraoperative high-dose-rate brachytherapy. *Surg Oncol Clin N Am* 2003; 12: 1079-1097.
39. Ellis RJ, Kim E, Kinsella TJ et al. Intraoperative radiotherapy in the multimodality approach to bone and soft tissue cancers. *Surg Oncol Clin N Am* 2003; 12: 1015-1029.
40. Krempien R, Roeder F, Oertel S et al. Intraoperative electron-beam therapy for primary and recurrent retroperitoneal soft-tissue sarcoma. *Int J Radiat Oncol Phys* 2006; 65: 772-779.
41. Willet CG, Suit HD, Tepper JE et al. Intra-operative electron beam radiation of retroperitoneal soft tissue sarcoma. *Cancer* 1991; 68: 278-283.
42. Azinovic I, Martinez Monge R, Javier Aristu J et al. Intraoperative radiotherapy electron boost followed by moderate doses of external beam radiotherapy in resected sarcoma of extremities. *Radiother Oncol* 2003; 67: 331-337.
43. Youssef E, Fontanesi J, Mott M et al. Long-term outcome of combined modality therapy in retroperitoneal and deep-trunk soft-tissue sarcoma: analysis of prognostic factors. *Int J Radiat Oncol Biol Phys* 2002; 54: 514-519.
44. Mikula LA, Ko MA, Catton CV et al. Long-term results of a prospective trial of preoperative radiation and postoperative brachytherapy for retroperitoneal sarcoma. *J Clin Oncol* 2005; Suppl, 2005 ASCO Annual Meeting Proceedings; 823s; abstract 9007.
45. Pawlik FM, Mikula L, Feig BW et al. Long term results of two prospective trials of preoperative external beam radiotherapy for localized intermediate-or high grade retroperitoneal soft tissue sarcomas. *Ann Surg Oncol* 2006; 13: 508-517.
46. Raut CP, Pisters PW. Retroperitoneal sarcomas: combined-modality treatment approaches. *J Surg Oncol* 2006; 94: 81-87.
47. McGrath PC, Neifeld JP, Lawrence W et al. Improved survival following complete excision of retroperitoneal sarcomas. *Ann Surg* 1984; 200: 200-204.
48. Karakousis CP, Velez AF, Emrich LJ. Management of retroperitoneal sarcomas and patient survival. *Am J Surg* 1985; 150: 376-380.
49. Salvadori B, Cusumano F, Delledonne V et al. Surgical treatment of 43 retroperitoneal sarcomas. *Eur J Surg Oncol* 1986; 12: 29-33.
50. Dalton RR, Donohue JH, van Heerden JA et al. Management of retroperitoneal sarcomas. *Surgery* 1989; 106: 725-732.
51. Stoeckle E, Coindre JM, Bonvalot S et al. Prognostic factors in retroperitoneal sarcoma: a multivariate analysis of series of 165 patients of the French Cancer Center Federation Sarcoma Group. *Cancer* 2001; 359-68.
52. Piotrowski P, Rutkowski P, Dziewirski W et al. Ocena wyników leczenia chirurgicznego chorych na mięsaki przestrzeni zaotrzewnowej. *Nowotwory* 2009; 59: 9-14 [in Polish].
53. Van Dalen T, Hennipman A, van Coevorden F et al. Evaluation of clinically applicable postsurgical classification system for primary retroperitoneal soft-tissue sarcoma. *Ann Surg Oncol* 2004; 11: 483-490.
54. Karakousis CP, Velez AF, Gestenbluth R et al. Resectability and survival in retroperitoneal sarcomas. *Ann Surg Oncol* 1996; 3: 150-158.
55. Rivoire M, Bonvalot S, Castaing M et al. A multivariate analysis of a series of 382 primary retroperitoneal sarcomas (RPS). *J Clin Oncol* 2007; ASCO Annual Meeting Proceedings Part I; 25, 18S: Abstract 10065.
56. Pacelli F, Tortorelli AP, Rosa F et al. Retroperitoneal soft tissue sarcoma: prognostic factors and therapeutic approaches. *Tumori* 2008; 94: 497-504.
57. Krempien R, Roeder F, Oertel S et al. Intraoperative electron-beam therapy for primary and recurrent retroperitoneal soft-tissue sarcoma. *Int J Radiat Oncol Phys* 2006; 65: 772-779.
58. Neuhaus SJ, Barry P, Clark MA et al. Surgical management of primary and recurrent retroperitoneal liposarcoma. *Br J Surg* 2005; 92: 246-252.
59. Dziewirski W, Rutkowski P, Nowecki et al. Surgery combined with intraoperative brachytherapy in the treatment of retroperitoneal sarcomas. *Ann Surg Oncol* 2006; 13: 245-252.
60. Storm FK, Mahvi DM. Diagnosis and management of retroperitoneal soft-tissue sarcoma. *Ann Surg* 1991; 214: 2-10.
61. Pisters PWT. Resection of Some But Not All Clinically Uninvolved Adjacent Viscera As Part of Surgery for Retroperitoneal Soft Tissue Sarcomas. *J Clin Oncol* 2009; 27: 6-8.
62. Gronchi A, Vullo SL, Fiore M et al. Aggressive Surgical Policies in a Retrospectively Reviewed Single-Institution Case Series of Retroperitoneal Soft Tissue Sarcoma Patients. *J Clin Oncol* 2009; 27: 24-30.
63. Gronchi A, Bonvalot S, Le Cesne A et al. Resection of Uninvolved Adjacent Organs Can Be Part of Surgery for Retroperitoneal Soft Tissue Sarcoma. *J Clin Oncol* 2009; 27: 2106-2107.
64. Bonvalot S, Rivoire M, Castaigne M et al. Primary Retroperitoneal Sarcomas: A Multivariate Analysis of Surgical Factors Associated With Local Control. *J Clin Oncol* 2009; 27: 31-37.
65. Pawlik FM, Mikula L, Feig BW et al. Long term result of two prospective trials of preoperative external beam, radiotherapy for localized intermediate- or high grade retroperitoneal soft tissue sarcomas. *Ann Surg Oncol* 2006; 13: 508-517.