

Changes of important anatomical structures in the inguinal region after a herniorrhaphy: observations during treatment of recurrent hernia using TEP

Anton Scierski¹, Frank Röchte²

¹Department of Surgery, Section General and Visceral Surgery, Section Chief, Grossburgwedel Hospital, Region Hannover, Burgwedel, Germany

²Department of Surgery, Senior House Officer, Grossburgwedel Hospital, Region Hannover, Burgwedel, Germany

Wideochirurgia i inne techniki małoinwazyjne 2007; 2 (1): 13–17

Summary

In this study we will describe important anatomical structures in the inguinal region as well as their changes after a herniorrhaphy, as they were seen during treatment of 135 recurrent hernias between 1993 and 2003 using TEP. We observed in most cases an upwardly curving arc-shaped deflection of the inguinal ligament and ileopubic tract, which may be due to tension caused by the attachment of the fascia transversalis and M. obliquus internus to the inguinal ligament. This leads to extension of the femoral canal and the lacuna vasorum. The femoral canal gets wider. This explains the regular occurrence of femoral hernias after a herniorrhaphy. Due to herniorrhaphy, damage is caused to Henle's loop, the retroperitoneal spermatic sheath as well as the urogenital fascia. These structures were either only partially or even no longer visible on recurrent operations. The internal inguinal ring has a lip-shaped appearance with a forward tilt in nearly all cases after a herniorrhaphy, whereas with TEP a view into the inguinal canal is practically impossible through the internal inguinal ring. Furthermore, using TEP we often saw especially in large primary hernias with a long medical history tough connective tissue lying upon the inguinal sack. This covering has so far not been described in the literature and is also present on recurrent hernias after a herniorrhaphy.

Key words: anatomical changes, recurrent hernia, inguinal herniorrhaphy, inguinal ligament, retroperitoneal spermatic sheath.

Introduction

With the work of Bassini the era of modern treatment of the inguinal hernia began. Numerous modifications to the Bassini technique are based on the principle of layer-for-layer suturing of the anatomical structures in this region.

The question we ask is, what changes are caused by the suture tension to the anatomical structures in

the inguinal region after an inguinal herniorrhaphy and how does this affect the operative treatment of a hernia as a result of it?

Materials and methods

Between 1993 and 2003 in Grossburgwedel hospital (Region Hannover, Germany) 2452 hernia operations using the total extraperitoneal method (TEP) were

Address for correspondence

Anton Scierski, Krankenhaus Grossburgwedel, Chirurgische Klinik, Fuhrberger-Strasse 8, 30938 Burgwedel, tel. +49 51 398 01 44 23, fax +49 51 398 01 53 75, Email: ascierski@yahoo.com

Tab. I. Total extraperitoneal inguinal hernia operations (TEP) carried out in Grossburgwedel hospital from 1993 to 2003

Number of operations	2452	100%
Primary operations	2317	94.5%
Recurrent operations	135	5.5%

Tab. II. Distribution of hernial recurrences

Number of recurrent operations	135	100%
1 recurrence	84	62.2%
2 recurrences	28	20.7%
3 or more recurrences	23	17.1%

carried out. 135 patients had recurrent hernias, for which all had previously been operationally treated using inguinal herniorrhaphy (Shouldice or Bassini) (Tab. I).

Of the 135 recurrent operations 84 cases were first time recurrences, 28 cases second recurrences and 23 cases were third or higher recurrences (Tab. II).

Intraoperative photos from video footage were taken and stored digitally. The evaluation of the

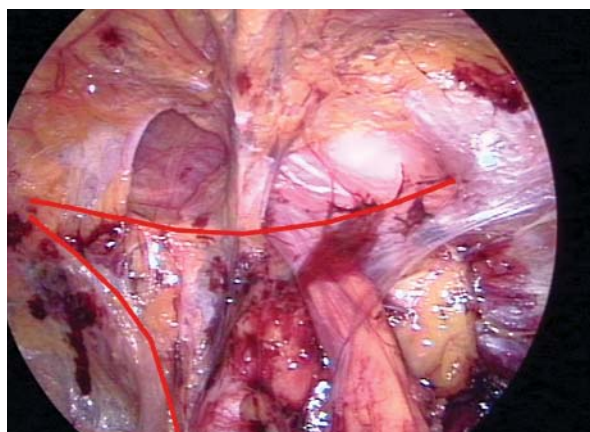


Fig. 1. Primary inguinal medial hernia on right side. The inguinal ligament takes a straight route from the spina iliaca anterior superior to the pecten ossis pubis. The lower marking signs the os pubis. Henle's loop makes a V-shaped loop around the internal inguinal ring thus restricting the spermatic cord within the inguinal ring

pictures was made by marking reference points on a monitor in accordance with a visual evaluation scale.

The following anatomical structures were examined for changes:

1. Inguinal ligament
2. Ileopubic tract
3. Henle's Loop
4. Internal inguinal ring
5. Urogenital fascia
6. Retroperitoneal spermatic sheath and the route of the spermatic cord

Results

Inguinal ligament

On the laparoscopic photos of primary inguinal hernia we can see that the inguinal ligament takes a straight route from the spina iliaca anterior superior to the pecten ossis pubis (Fig. 1). In recurrent hernias the inguinal ligament takes an arc-shaped route upward induced by tension from the fascia transversalis and the M. obliquus internus (Fig. 2). Because of this an obtuse insertion angle into the inguinal ligament at the pecten ossis pubis is required, which causes enlargement of the femoral canal and the lacuna vasorum.

Ileopubic tract

The ileopubic tract can be seen clearly on primary hernias using TEP. It appears as a structure running

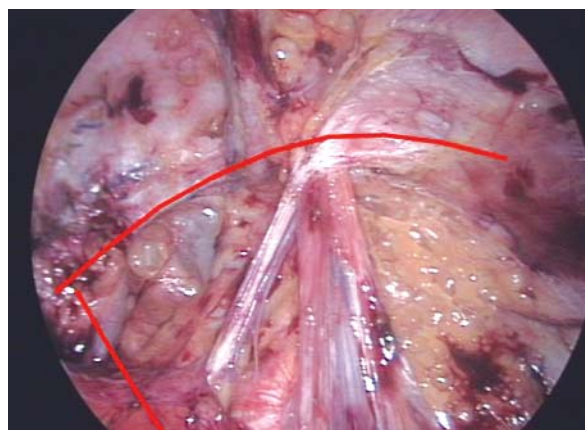


Fig. 2. Recurrent inguinal hernia on right side. The inguinal ligament takes an arc-shaped route upward. The lower marking indicates the os pubis. Henle's loop is absent

parallel to the inguinal ligament. Similar to the inguinal ligament, the ileopubic tract makes an arc-shaped deflection upwards. Again, we see here enlargement of the femoral canal and the lacuna vasorum.

Henle's Loop

Henle's loop makes a V-shaped loop around the internal inguinal ring thus restricting the spermatic cord within the inguinal ring (Fig. 1, 3). Through contractions of the abdominal muscle, during laparoscopic operations, the function of the loop can clearly be seen. Due to muscular movement Henle's loop tightens, raising the spermatic cord and thus causing partial closure of the internal inguinal ring. Henle's loop is no longer definable with recurrent hernia (Fig. 2), thus damaging the muscular closing mechanism.

Internal inguinal ring

The internal entrance of the inguinal canal is the internal inguinal ring. In primary inguinal hernias, the ring is round. Because of this, particularly with large indirect hernias, there is laparoscopically a better view inside the inguinal canal laterally from above. With recurrent hernias the internal inguinal ring is no longer round, but stretched into a lip-shape and the entrance of the internal inguinal ring tilts forward. Furthermore, after inguinal herniorrhaphy, the fascia transversalis and the musculus obliquus internus lie, in part, in front and above the internal inguinal ring. This leads to the fact that with recurrent hernias a view inside the inguinal canal through the internal inguinal ring is barely possible (Fig. 3). Only once did we successfully view the inguinal canal of a recurrent hernia. We saw a disfigured arc-shaped inguinal ligament on an unchanged ileopubic tract.

During ultrasound examination of the indirect primary inguinal hernia, the internal inguinal ring becomes wider and larger due to the intraabdominal pressure. Contents of the inguinal sack reach the inguinal canal taking a direct route. The depth of penetration into the inguinal canal depends on the size (length) of the inguinal sack. The entrance into the inguinal canal in indirect recurrent hernias comes from underneath. The fascia transversalis and the musculus obliquus internus, which are pulled down, form a barrier behind which a "sack-like" space develops. This space is the start of the inguinal canal. Contents of the inguinal sack reach the inguinal canal taking an s-shaped route.

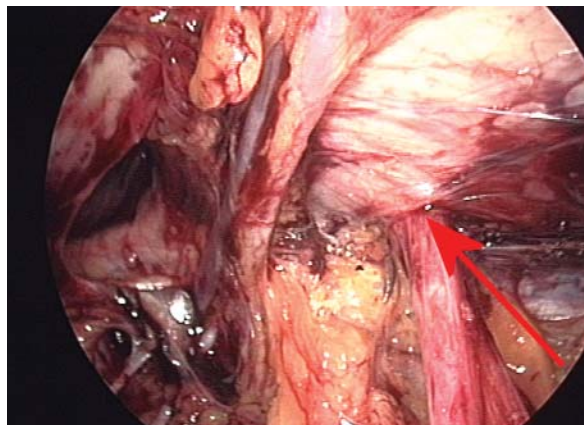


Fig. 3. Recurrent inguinal hernia on right side. After herniorrhaphy, the fascia transversalis and the musculus obliquus internus lie, in part, in front and above the internal inguinal ring (arrow). This leads to the fact that a view inside the inguinal canal through the internal inguinal ring is barely possible

Urogenital fascia

The urogenital fascia is a structure which lies between the pre- and retroperitoneal space and separates both spaces. A primary hernia manifests itself as a broader, more stable structure. With patients who suffer from a recurrent hernia after inguinal herniorrhaphy, the urogenital fascia is narrow or no longer definable.

Retroperietal spermatic sheath and the route of the spermatic cord

With operations using the TEP method, particularly with large and persistent hernias, the retroperietal spermatic sheath has been discovered to be a stable layer which encloses the spermatic vessels laterally and the vas deferens medially. Its exterior as well as its route taken to the muscles are structurally similar. This common "sheath" encloses the spermatic vessels and the vas deferens 2-3 cm prior to entering into the inguinal canal (Fig. 4).

We could not trace this sheath in recurrent hernias and in some cases the spermatic vessels and the vas deferens were separated and were, right up to its entry into the anulus inguinalis internus, enclosed in weak connective tissue. The vas deferens and the spermatic vessels first conjoin at the internal inguinal ring (Fig. 5).

Inguinal hernias often have tough connective tissue which lies upon the inguinal sack. The thickness

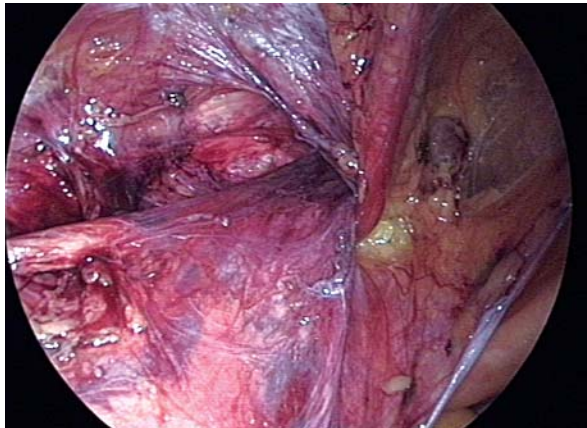


Fig. 4. Primary inguinal hernia on left side. The retroperitoneal spermatic sheath is a stable layer which encloses the spermatic vessels laterally and the vas deferens medially. To excise the peritoneal sac during TEP, this sheath must be entered by incision and must be separated from the spermatic vessels and vas deferens

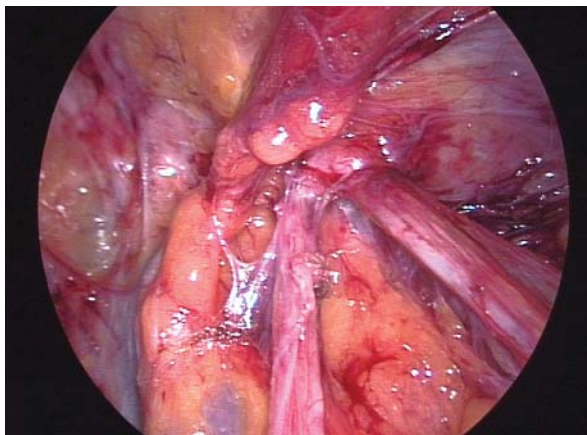


Fig. 5. Recurrent inguinal hernia on right side. The retroperitoneal spermatic sheath was mostly undetectable like in this case. The spermatic vessels and the vas deferens are separated and conjoin at the internal inguinal ring

of this structure depends on the size of the hernia and the period of medical history (the bigger and longer, the thicker it becomes). This structure is likewise present with recurrences after herniorrhaphy.

Discussion

Following the descriptions of the operation techniques of Bassini, Shouldice and other herniorrhaphies the

impression was gained that the inguinal ligament is a stable and rigid structure, which does not change under the tension of the attached muscular and fascial structures. This idea cannot be supported. The changes described by us supply the proof that the inguinal ligament is deflected upward in an arch-shaped way thus extending the femoral canal and the lacuna vasorum. In the literature up to fifteen times as many occurrences of femoral hernias after an inguinal herniorrhaphy are described, without ever going into greater detail of this phenomenon [1]. After our observations the reasons for this lie in the described post-operational changes to the inguinal ligament and the iliopubic tract. Similar changes were also presumed in the literature [2, 3]. Apart from these changes we observed an absence of the Henle loop on recurrent hernias. The explanation for this is that mechanical damage is done to the loop during the primary operation, particularly through the application of stitches to the internal inguinal ring. The retroperitoneal spermatic sheath is described as an extension of the urogenital fascia in the direction of the inguinal canal. It covers the spermatic vessels and the vas deferens and continues into the inguinal canal. [4, 5]. In some cases the retroperitoneal spermatic sheath reaches the lateral abdominal wall, where it then covers the Arteria and Vena circumflexa ilii profunda. In recurrent hernia cases, the retroperitoneal spermatic sheath is mostly undetectable. We hypothesize that the preparation of the hernia in the inguinal canal leads to the destruction of the retroperitoneal spermatic sheath, which later causes atrophy of the remaining part of the sheath. However, with recurrent hernias a lower limit of an atrophic fascia spermatica could not be seen. The tough connective tissue which we often saw on large and persistent primary hernias and which lies upon the inguinal sack has so far not been described in the literature. Perhaps the aetiology for this can be clarified in the future. This covering is also present on recurrent hernias after a herniorrhaphy.

Conclusion

There are many different operational techniques for the treatment of inguinal hernias. This work represents the substantial changes to the inguinal region after a herniorrhaphy. A disadvantage with herniorrhaphies is the increased occurrence of femoral hernias. In our opinion, the reason for this is the described extension

of the lacuna vasorum and the femoral canal due to the changes to the inguinal ligament and ileopubic tract. The described changes can be seen as a good reason for tension-free treatment using hernioplastics instead of using herniorrhaphies.

References

1. Mikkelsen T, Bay-Nielsen M, Kehlet H. Risk of femoral hernia after inguinal herniorrhaphy. *Br J Surg* 2002; 89: 486-8.
2. Balen EM, Ferrer JV, Vicente F i wsp. Recurrences after prosthetic repair of inguinal hernias by the Lichtenstein technique. *Hernia* 2000; 4: 13-6.
3. Lichtenstein IL, Shulman AG, Amid PK. The tension-free repair of groin hernias. In: *Hernia*. Ed. Nyhus LM, Condon RE. Lippincott. Philadelphia 1995; 237-49.
4. Folscher DJ, Leroy J, Jamali FR i wsp. Totally extrafascial endoscopic preperitoneal hernia repair: a merger of anatomy and surgery. The exact description to endoscopically dissect the spermatic fascia. *Hernia* 2000; 4: 223-7.
5. Stoppa R, Diarra B, Mertl P. The retroperitoneal spermatic sheath. An anatomical structure of surgical interest. *Hernia* 1997; 1: 55-9.