

Mid-term and late results of endovascular treatment for symptomatic carotid artery stenosis under proximal protection

Paweł Latacz¹, Marian Simka², Marcin Krzanowski³, Katarzyna Krzanowska³, Paweł Brzegowy⁴, Bartłomiej Łasocho⁴, Tadeusz J. Popiela⁴

¹Department of Neurology, Jagiellonian University Medical College, Krakow, Poland

²Department of Anatomy, University of Opole, Opole, Poland

³Department of Nephrology, Jagiellonian University Medical College, Krakow, Poland

⁴Chair of Radiology, Jagiellonian University Medical College, Krakow, Poland

Videosurgery Miniinv 2021; 16 (1): 175–182
DOI: <https://doi.org/10.5114/wiitm.2020.94519>

Abstract

Introduction: Although filters are still preferred during carotid stenting, proximal protection systems (PPS) are increasingly used during these procedures. PPS seem to be safer than distal systems, especially in symptomatic patients, but evidence supporting their use is limited.

Aim: This was a post hoc survey with 30-day mid-term and long-term follow up, which was aimed at assessment of the safety and efficacy of stenting of the internal carotid artery under PPS in symptomatic patients.

Material and methods: We analysed the results of stenting in 120 symptomatic patients presenting with at least 60% stenosis. Patients were aged 67.9 ± 9.8 years, and 12 patients were older than 80 years. An occlusion of contralateral artery was found in 5 patients and bilateral stenosis in 26 patients. The primary endpoint of this study was the proportion of patients who had new neurological events, including transient ischemic attack and minor or major stroke in 30-day follow-up. The secondary endpoint was a composite of technical and clinical success. During long-term follow-up we assessed new neurological events and stenoses of implanted stents.

Results: The incidence of new neurological events during 30-day follow-up was 0.8%. The rate of technical success defined by secondary endpoint was 100%. Mean internal carotid artery stenosis before and after stent implantation was 93.8 ± 9% and 8.4 ± 6.3%, respectively ($p < 0.001$). Procedural success was achieved in all cases. During long-term follow-up there were two (1.7%) asymptomatic in-stent stenoses and no (0%) new neurological events.

Conclusions: Endovascular management of symptomatic carotid stenosis under PPS is safe, feasible, and appears to be a good alternative to surgical endarterectomy.

Key words: stroke, stenting, carotid stenosis, proximal protection.

Introduction

Surgical endarterectomy and endovascular angioplasty represent established treatment modalities for stenosis of the internal carotid artery, which is responsible for about 20% of cerebral strokes. Nowadays surgical repair is still regarded as the method

of choice, while angioplasty and stenting is an alternative treatment modality [1–6]. The main problem associated with transcatheter angioplasty is cerebral microembolism during endovascular manoeuvres. Although distal protection with filters is primarily used for the protection of cerebral circulation, a proximal protection system, such as the Mo.Ma,

Address for correspondence

Paweł Latacz MD, PhD, Department of Neurology, Jagiellonian University Medical College, University Hospital, 2 Jakubowskiego St, 30-688 Krakow, Poland, phone: +48 12 400 25 51, e-mail: pawlat@me.com

is increasingly used. These systems are characterised by a higher safety profile in comparison with distal protection devices [7, 8]. A proximal protection system seems to be particularly advantageous in symptomatic patients and those older than 80 years. Research has demonstrated that there are fewer microembolic complications after procedures performed under proximal protection in comparison with carotid stenting with the use of distal protection devices. In this retrospective study we analysed early, mid-, and long-term results of carotid angioplasty with stenting under proximal protection in symptomatic patients.

Aim

This post hoc survey, with 30-day mid-term and up to 4.5-year long-term follow-up, was aimed at assessment of safety and efficacy of stenting procedure with the use of proximal protection for the treatment of internal carotid artery (ICA) stenosis in symptomatic patients presenting with at least 60% stenosis of this artery. The primary endpoint of this study was the proportion of patients who, within 30 days of carotid intervention, had a new neurologi-

cal event, including transient ischemic attack (TIA) or minor or major stroke. The secondary endpoint was the mid-term and late composite of technical and clinical success. This success was evaluated 24–48 h after the procedure, and then at 30-day mid-term and late follow-ups, and was defined as a technically successful carotid stenting, which was not followed by death, stroke, or other cardiovascular event, or by a stent occlusion/restenosis.

Material and methods

We analysed results of the treatment of 120 consecutive patients (44 women and 76 men) who were managed by our team from March 2014 to June 2018. The mean age of enrolled patients was 67.9 ±9.8 years, and 12 (10%) patients were aged more than 80 years. All patients presented with at least 60% stenosis of the ICA, demonstrated by means of colour-coded duplex sonography, computed tomography (CT) angiography, or magnetic resonance (MR) angiography. Standard preprocedural management of the patients comprised multidisciplinary assessment, including neurological, vascular, and cardiologic consultations. Potential risks and benefits associated with the planned procedure were discussed with patients, and all of them gave their written, informed consent. The inclusion and exclusion criteria are presented in Table I.

All patients analysed in this study were symptomatic, which meant that they had an ipsilateral neurological ischaemic event during the 60 days before the endovascular procedure. An ischaemic lesion was considered ipsilateral if it occurred in the cerebral tissue supplied by the target carotid artery. Patients were managed at least two days after a neurological event, preferentially on the 7th–14th day, depending on the findings of CT or MRI of the brain and the appearance of cerebral lesions revealed by this test. In this patient cohort the mean time from neurological event to the intervention was 18.7 days.

In addition to the demographic and clinical data, we also analysed angiographic characteristics, such as the presence of coexisting lesions in other arteries supplying the brain, including intracranial stenoses. Also, we assessed the endovascular technique used (type of protection, type of stent, duration of the procedure, and duration of the occlusion of the artery). Patients' characteristics and localisation of vascular lesions are given in Table II.

Table I. Inclusion and exclusion criteria

<p>Inclusion criteria:</p> <ul style="list-style-type: none"> • Symptomatic patient with internal carotid artery stenosis ≥ 60% as defined by duplex ultrasound, angiography or MR angiography • Symptomatic lesions of internal carotid artery is defined as a stenosis associated with ipsilateral TIA, amaurosis fugax, ischaemic stroke or retinal infarction • Unstable symptomatic lesions of carotid artery, a presence (or suspect) of thrombi inside the lesion, and tortuosity of the target artery
<p>Exclusion criteria:</p> <ul style="list-style-type: none"> • Target lesion that has been previously stented • Highly calcified lesions • Occlusion of the contralateral carotid artery without adequate collateral circulation through the circle of Willis (revealed by means of the transcranial Doppler sonography) • An acute ipsilateral stroke • Other severe pathologies of the brain resulting in significant loss of cerebral tissue and/or significant neurological deficits • History of haemorrhagic transformation of ischemic stroke • Severe co-morbidities (such as cancer or decompensated heart failure) • Allergy to aspirin or clopidogrel; to iodinated contrast media • A lack of adequate vascular access

Endovascular procedures were performed by a well-trained interventionalist, with an expertise of over 1000 endovascular procedures already carried out. All procedures were done under local anaesthe-

Table II. Demographic and clinical characteristics of the patients (number of patients: *N* = 120; number of procedures: *N* = 120)

Patients' characteristics	<i>N</i>	Percent
Patients' age, mean ± SD [years]	67.9 ±9.8	
Patients older than 80 year	12	10
Male/female ratio	76/44	
Risk factors:		
Stable coronary heart disease	25	20.8
Arterial hypertension	108	90.0
Diabetes mellitus type 2	34	28.3
Dislipidemia	80	66.7
Cigarette smoking	29	24.2
Renal impairment	5	4.2
Peripheral artery disease	4	3.3
Chronic obstructive pulmonary disease	5	4.2
History of percutaneous coronary angioplasty	13	10.8
History of myocardial infarction	16	13.3
History of transient ischemic attack	12	10.0
History of stroke	108	90.0
Bilateral stenosis of the internal carotid artery	26	21.7
Occlusion of the internal carotid artery	5	4.2
Stenosis of the vertebral artery	9	7.5
Lesion in the left/right internal carotid artery	59/61	49.2/50.8
II/III type of the aortic arch	23	19.2
Degree of stenosis, mean ± SD	93.8 ±14.2	
Time from neurological event to the intervention, mean ± SD [days]	18.7 ±10.2	
Localization of stenosis in the internal carotid artery:		
C1-C2 segment	109	90.8
C3-C4 segment	11	9.2

sia at the vascular access site. Catheter angiography, which was performed before and after angioplasty, evaluated both ipsi- and contralateral cerebral circulation. Except for 4 patients, who were protected with the Gore Flow Reversal System (Gore & Associates, Inc., Flagstaff, AZ, USA); in all remaining patients the Mo.Ma (Medtronic, Minneapolis, MN, USA) system was used. Stent implantations were performed using the technique and armamentarium, which were tailored to the type and anatomy of the lesion. The time of the occlusion of carotid flow by protection systems ranged from 2.5 to 15 min (mean: 6.6 ±2.5 min). Predilatation was performed in 24 out of 120 stenoses (20%). In 6 patients two stents and in 1 patient three stents were implanted, primarily because of a massive protrusion of the plaques through the cells of stents. In 91 (75.8%) patients we used close-cell stents, including dual-layered stents in 29 (24.1%) patients. Details regarding protection devices and the stents utilised in this study, and the presence of embolic material secured by the protection systems, are given in Table III.

Table III. Characteristics of protection systems and stents utilized in 120 procedures in symptomatic patients (120 procedures)

Variable	Number of cases	Percent
Protection systems:		
Mo.Ma (Medtronic, Minneapolis, MN, USA)	116	96.6
Gore Flow Reversal System (Gore & Associates, Inc., Flagstaff, AZ, USA)	4	3.4
Time of occlusions system, mean ± SD [min]	6.6 ±2.5	
Stents:		
Precise (Cordis, Fremont, CA, USA)	29	24.2
Carotid Wallstent (Boston Scientific, Natick, MA, USA)	49	40.8
Cristallo Ideale (Medtronic, Minneapolis, MN, USA)	13	10.8
RoadSaver (Terumo, Tokyo, Japan)	29	24.2
Macroscopically visible embolic material in the protection system:		
Single plaque or thrombus	31	25.8
A little of debris	3	2.5
A lot of debris	3	2.5

All patients received aspirin 75 mg/day and clopidogrel 75 mg/day. These drugs were administered 2–3 days before the planned procedure and then for at least 30 days after the intervention (typically for 3–6 months). During the procedure patients were administered intravenously heparin 100 units/kg. Periprocedural bradycardias were managed with the administration of atropine. Neurological assessment was performed before the procedure and on the first or second postprocedural day. A sonographic follow-up of the target arteries was performed on the first or second postprocedural day, then after 1 and 3 months, and thereafter every 6 months. In the case of a neurological event, an additional sonographic and neurological assessment was performed.

Patients were advised to report any neurological events that occurred during follow-up. Neurological symptoms were categorised as follows: transient ischaemic attack, which was defined as an acute neurological deficit resulting from focal temporary cerebral or retinal ischaemia that lasted less than 24 h; stroke, which was defined as a new cerebrovascular event of ischaemic or haemorrhagic aetiology resulting in cerebral infarction and neurological deficit. Strokes were further classified as: minor – with neurological deficits lasting less than 30 days or lasting longer than 30 days, but presenting with small deficit (up to 4 points in the National Institute of Health Stroke Scale); major – with neurological deficits lasting longer than 30 days; and fatal – a stroke (ischaemic or haemorrhagic) resulting in death.

Statistical analysis

Continuous variables were expressed as means \pm standard deviation (SD); categorical variables were expressed as percentages. Analysis of normality was performed with the Kolmogorov-Smirnov test. Comparison of categorical variables between the groups was performed using the χ^2 test. Comparisons of continuous variables between the two groups were performed using the independent samples *t*-test. Multivariate stepwise backward conditional logistic regression analysis was used to determine independent predictors of risk of intervention. All significant parameters in the univariate analysis were selected in the multivariate model. The significance of the two-tailed *p* was set at *p* < 0.05. Statistical analysis

was performed using the SPSS software (Statistical Package for the Social Sciences (version 25.0 for MacOS, SPSS Inc., Chicago, IL, USA).

Results

The degree of stenosis of the ICA ranged from 60% to 99% (mean \pm SD: 93.8 \pm 14.6%), and the majority of patients presented with over 70% stenosis. An occlusion of contralateral internal carotid artery was found in 5 (4.1%) patients and bilateral stenosis in 26 (21.6%) patients. In all cases the endovascular procedure was successful. All patients completed the 30-day follow-up. There were neither fatalities nor major strokes following the intervention in this patient cohort. The mean stenosis of internal carotid artery before and after stent implantation was 93.8 \pm 14.2% and 8.4 \pm 6.3%, respectively (*p* < 0.001).

An example of a symptomatic patient with bilateral, critical carotid stenosis qualified for angioplasty with the use of a proximal protection system is shown in Photo 1.

The incidence of new neurological events during the 30-day follow-up (the primary endpoint) was 0.8%. This one ipsilateral minor stroke occurred on the fifth postprocedural day in a 62-year-old male, who underwent stenting (Carotid WALLSTENT stent) of the right ICA under protection with the use of the Mo.Ma device. Because the stent was patent, this event probably resulted from a cardiogenic embolism. The rate of technical success defined by the secondary endpoint was 100%.

Five (4.1%) patients developed neurological symptoms after introduction of the protection device, two of them presented with contralateral stenoses of the ICA, but there were no clinical consequences related to this intolerance of proximal protection. Periprocedurally 8 (6.6%) patients developed hypotension, which was managed with intravenous administration of crystalloids, but it did not result in further clinical sequelae. In 2 such patients an additional administration of dopamine was needed. Apart from these rather minor events, there were no serious periprocedural complications. Logistic multivariate analysis revealed some risk factors significantly predisposing for the intolerance of a proximal protection device. These comprised patients' age (intolerance of the introduction of protection device was more often seen in patients older than

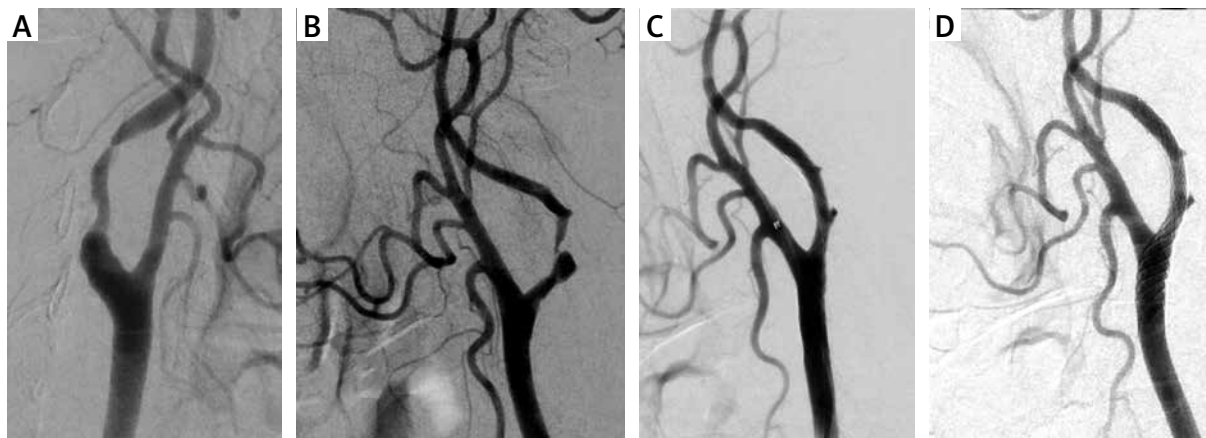


Photo 1. Patient with bilateral critical internal carotid artery stenosis. **A** – Critical, asymptomatic right internal carotid artery stenosis. **B** – Critical, symptomatic left internal carotid artery stenosis. **C** – Optimal angiographic result angioplasty with implantation of a RoadSaver stent in the left carotid internal artery with use of proximal protection Mo.Ma 8F (visible balloon of Mo.Ma system in the external carotid artery). **D** – Final optimal angiographic angioplasty of left internal carotid artery - result after removal of the protection system, with good apposition of the stent in the common and internal left carotid arteries

80 years, HR = 7.55; $p = 0.006$), chronic obstructive pulmonary disease (HR = 4.305; $p = 0.03$), and cigarette smoking (HR = 4.012; $p = 0.04$).

The minimal duration of long-term follow-up was 5 months, and the mean duration was 594 ± 369 days. In 40 cases it was longer than three years; the maximal duration of the follow-up was 4.5 years.

There were no fatalities during the long-term follow-up. Except for the above-described stroke that occurred postprocedurally, there were no neurologic adverse events during follow-up. There was one non-fatal coronary event requiring percutaneous angioplasty. The overall probability of any incident-free survival was 95.8%, and the probability of stroke-free survival was 99.2%. Cumulative probability of restenosis-free survival in the implanted stent was 98.3%, and such a survival regarding coronary events requiring angioplasty was 98.3% (Figure 1). Stents in 117 patients were patent and without significant stenoses. In 2 patients we found an asymptomatic in-stent restenosis. In both patients there were no neurological symptoms during 8-month follow-up after the re-intervention and the stents remained patent. It should be emphasised, however, that although the maximum observation period was over four years, the median duration of follow-up was about 2 years; thus, it is likely that during a longer follow-up the incidence rate of coronary and other non-neurological events will be higher.

Discussion

In our material carotid artery stenting with the use of proximal protection devices in symptomatic patients appeared to be a safe procedure.

Although carotid stenting is still preferentially performed with the use of distal protection, in symptomatic patients a high rate of ischaemic cerebral events after stenting with the use of filters, which in some studies was at the level of 10%, cannot be ignored [1–4, 9]. By contrast, such adverse events associated with stenting under proximal protection are less frequent. Open-label studies reported this risk at the level of 0.9–2.4% [10–13]. Similarly, there were fewer microembolic complications revealed by MRI after procedures performed under proximal protection in comparison with carotid stenting with the use of filters [14–16]. In our study, the Mo.Ma system was the preferred proximal protection device. This system has an established place in the armamentarium available for carotid interventions. In the non-randomised multicentre study ARMOUR, which evaluated a group of 222 patients and utilized the Mo.Ma system, the composite complication rate (comprising: stroke, death, and myocardial infarction) was 2.7%, and the stroke rate during 30 days was 0.9% [12]. In another study the Mo.Ma system was used in 1300 patients. The composite complication rate (comprising stroke and death) at 30-day follow-up was 1.4% (3% in symptomatic

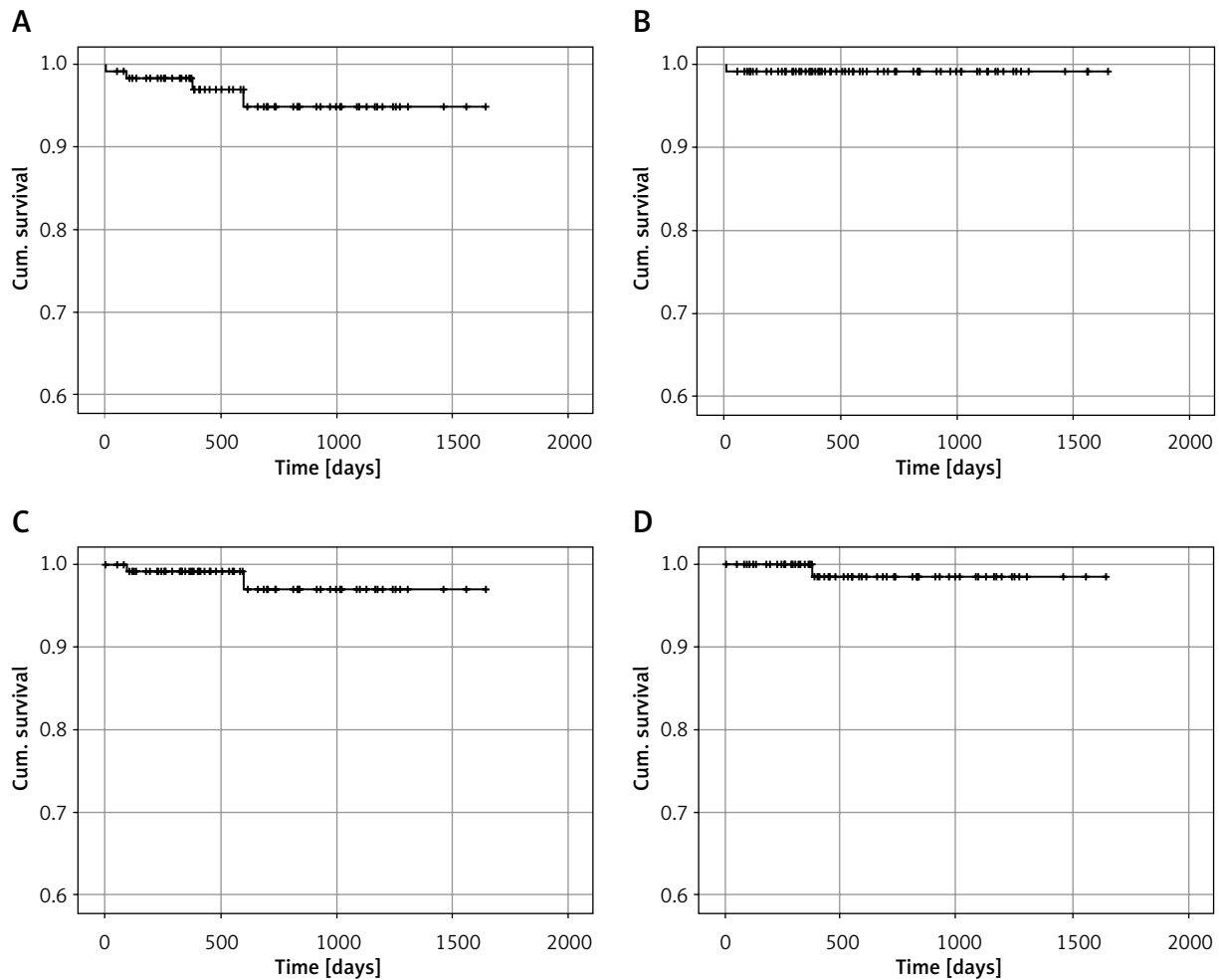


Figure 1. Kaplan-Meier event-free survival curves for symptomatic patients undergoing carotid artery stenting with proximal protection system. **A** – Overall survival free from any events. **B** – Cumulative survival freedom from stroke for all patients. **C** – Cumulative restenosis-free survival. **D** – Cumulative percutaneous coronary intervention-free survival

patients and 0.9% in asymptomatic ones). Of note, in this study a low operator experience (less than 100 procedures performed) was associated with a higher risk of adverse events [17]. Efficacy and safety of an alternative proximal protection system, the Gore Flow Reversal System, have been evaluated in the multicentre prospective, nonrandomised study EMPiRE [18]. This study involved 245 patients, of whom 30% were symptomatic and 16% were older than 80 years. Of note, in this study a contralateral stenosis or occlusion was not the exclusion criterion, and actually 10.5% of patients presented with such an occlusion. In this study the composite complication rate (including stroke, death, myocardial infarction, or TIA) during 30-day follow-up was

4.5%, while the composite complication rate comprising only stroke and death was 2.9% [18]. In another study in which the effectiveness of the Gore Flow Reversal System was assessed compared to distal protection systems, there were fewer lesions in the MRI DWI study, but also a reduction in the number of neurological incidents (comprising stroke, death, and myocardial infarction) in the arm using the proximal protection system [19].

Still, it should be emphasised that the aforementioned trials included both symptomatic and asymptomatic patients, and that the percentage of symptomatic patients in these studies was not higher than 40%. By contrast, in our survey only symptomatic patients were included. Of note, there were

no periprocedural neurological adverse events in our patients, while mid-term follow-up has revealed a complication rate of 0.8%, which is much less in comparison with the other studies. In our opinion, such a low complication rate has resulted from the fact that in our centre the proximal protection was the preferred method for the management of symptomatic patients, even those presenting with critical stenosis or contralateral occlusion [20–22]. In contrast to the results of the meta-analysis performed by Bersin *et al.* [22], in our study adverse events were not more prevalent in patients older than 80 years, except for more frequent intolerance of the protection system.

However, a contralateral occlusion or significant stenosis represents an important limitation of the proximal protection technique. The maximal tolerated time of the occlusion of the ICA by a proximal protection device, according to different authors, should not exceed 2.5–15 min [21]. Of note, in our patient series 5 (4.2%) individuals presented with an occlusion of contralateral internal carotid artery, while 25 (20.8%) patients had severe bilateral stenosis of the ICAs. Neurological symptoms during introduction of the system occurred in 5 patients, including two individuals with bilateral stenosis. Nonetheless, there were no clinical consequences associated with such intolerance. Importantly, all of the aforementioned neurological symptoms occurred during procedures, which were longer than 6–7 min. This further confirms the validity of the 5-minute threshold as the safe time of endovascular carotid revascularisation [21].

The use of closed-cell stents could also account for the low stroke rate in our study. Superiority of the closed-cell stents in comparison with the open-cell ones has already been demonstrated in several trials [23–25]. In 29 patients we implanted modern dual-layered stents (the RoadSaver stents). These stents are optimal in cases of severely narrowed artery and also in cases of distal (C2–C4 segments of the ICA) revascularisation. Good clinical results of carotid stenting with the use of such designed stents have already been reported [26–28]. Finally, an experience of the interventionalists should not be ignored [29]. There seems to be a learning curve with significant drop in the incidence of adverse events after more than 200 procedures performed [29, 30]. Other studies have already reported the expertise of the operator as an independent factor associated with fewer complications. Besides, closed-

cell stents, which are safer but also more difficult to implant, are more willingly used by experienced doctors [24].

We are aware of some limitations of this report. Firstly, our results are based on the retrospective assessment of data from our registry. Secondly, these results were not compared with surgical carotid endarterectomy or with endovascular treatments with the use of filters.

Conclusions

In our patient series the endovascular treatment of symptomatic carotid stenosis under proximal protection was safe and feasible. It appeared to be a good alternative to carotid endarterectomy. Low incidence of serious neurological adverse events was probably related to extensive operator experience, short time of carotid artery occlusion, and tailored use of the closed-cell or dual-layered stents.

Conflict of interest

The authors declare no conflict of interest.

References

1. Mas JL, Chatellier G, Beyssen B, et al. Endarterectomy versus stenting in patients with symptomatic severe carotid stenosis. *N Engl J Med* 2006; 355: 1660–71.
2. Wimmer NJ, Yeh RW, Cutlip DE, et al. Risk prediction for adverse events after carotid artery stenting in higher surgical risk patients. *Stroke* 2012; 43: 3218–24.
3. Bangalore S, Kumar S, Wetterslev J, et al. Carotid artery stenting vs carotid endarterectomy: meta-analysis and diversity-adjusted trial sequential analysis of randomized trials. *Arch Neurol* 2011; 68: 172–84.
4. Massop D, Dave R, Metzger C, et al. SAPHIRE Worldwide Investigators. Stenting and angioplasty with protection in patients at high-risk for endarterectomy: SAPHIRE Worldwide Registry first 2,001 patients. *Catheter Cardiovasc Interv* 2009; 73: 129–36.
5. Brott TG, Hobson RW, Howard G, et al. Stenting versus endarterectomy for treatment of carotid-artery stenosis. *N Engl J Med* 2010; 363: 11–23.
6. Ederle J, Dobson J, Featherstone RL, et al. Carotid artery stenting compared with endarterectomy in patients with symptomatic carotid stenosis (International Carotid Stenting Study): an interim analysis of a randomised controlled trial. *Lancet* 2010; 375: 985–97.
7. Eskandari MK, Najjar SF, Matsumura JS, et al. Technical limitations of carotid filter embolic protection devices. *Ann Vasc Surg* 2007; 21: 403–7.
8. Finol EA, Siewiork GM, Scotti CM, et al. Wall apposition assessment and performance comparison of distal protection filters. *J Endovasc Ther* 2008; 15: 177–85.

9. Hobson RW 2nd, Howard VJ, Roubin GS, et al. Carotid artery stenting is associated with increased complications in octogenarians: 30-day stroke and death rates in the CREST lead-in phase. *J Vasc Surg* 2004; 40: 1106-11.
10. Cremonesi A, Gieowarsingh S, Spagnolo B, et al. Safety, efficacy and long-term durability of endovascular therapy for carotid artery disease: the tailored-Carotid Artery Stenting Experience of a single high-volume centre (tailored-CASE Registry). *Eurointervention* 2009; 5: 589-98.
11. Pieniasek P, Musialek P, Kablak-Ziembicka A, et al. Carotid artery stenting with patient- and lesion-tailored selection of the neuroprotection system and stent type: early and 5-year result from a prospective academic registry of 535 consecutive procedures (TARGET-CAS). *J Endovasc Ther* 2008; 15: 249-62.
12. Ansel GM, Hopkins LN, Jaff MR, et al. Safety and effectiveness of the INVATEC MO.MA proximal cerebral protection device during carotid artery stenting: results from the ARMOUR pivotal trial. *Catheter Cardiovasc Interv* 2010; 76: 1-8.
13. Pieniasek P, Tekieli L, Musialek P, et al. Carotid artery stenting according to the tailored-CAS algorithm is associated with a low complication rate at 30 days: data from the TARGET-CAS study. *Kardiologia Pol* 2012; 70: 378-86.
14. Bijuklic K, Wandler A, Hazizi F, Schofer J. The PROFIL study (Prevention of Cerebral Embolization by Proximal Balloon Occlusion Compared to Filter Protection During Carotid Artery Stenting): a prospective randomized trial. *J Am Coll Cardiol* 2012; 59: 1383-9.
15. Montorsi P, Caputi L, Galli S, et al. Microembolization during carotid artery stenting in patients with high-risk, lipid-rich plaque. A randomized trial of proximal versus distal cerebral protection. *J Am Coll Cardiol* 2011; 58: 1656-63.
16. Cano MN, Kambara AM, de Cano SJ, et al. Randomized comparison of distal and proximal cerebral protection during carotid, artery stenting. *JACC Cardiovasc Interv* 2013; 6: 1203-9.
17. Stabile E, Salemme L, Sorropago G, et al. Proximal endovascular occlusion for carotid artery stenting: results from a prospective registry of 1,300 patients. *J Am Coll Cardiol* 2010; 55: 1661-7.
18. Clair DG, Hopkins LN, Mehta M, et al. Neuroprotection during carotid artery stenting using the GORE flow reversal system: 30-day outcomes in the EMPIRE Clinical Study. *Catheter Cardiovasc Interv* 2011; 77: 420-9.
19. Kajihara Y, Sakamoto S, Kiura Y. Comparison of dual protection and distal filter protection as a distal embolic protection method during carotid artery stenting: a single-center carotid artery stenting experience. *Neurosurg Rev* 2015; 38: 671-6.
20. Hornung M, Bertog SC, Franke J, et al. Evaluation of proximal protection devices during carotid artery stenting as first choice for embolic protection. *EuroIntervention* 2015; 10: 1362-7.
21. Latacz P, Simka M, Popiela T, et al. Early results of endovascular treatment of patients with bilateral stenoses of the internal carotid arteries using proximal protection systems at 30-day follow-up. *Neurol Neurochir Pol* 2017; 51: 375-81.
22. Bersin RM, Stabile E, Ansel GM, et al. A meta-analysis of proximal occlusion device outcomes in carotid artery stenting. *Catheter Cardiovasc Interv* 2012; 80: 1072-8.
23. Bosiers M, de Donato G, Deloose K, et al. Does free cell area influence the outcome in carotid artery stenting? *Eur J Vasc Endovasc Surg* 2007; 33: 135-41.
24. Wodarg F, Turner E, Dobson J, et al. Influence of stent design and use of protection devices on outcome of carotid artery stenting – a pooled analysis of individual patient data. *J Neurointerv Surg* 2018; 10: 1149-54.
25. de Vries EE, Meershoek AJA, Vonken EJ, et al. A meta-analysis of the effect of stent design on clinical and radiologic outcomes of carotid artery stenting. *J Vasc Surg* 2019; 69: 1952-61.
26. Hopf-Jensen S, Marques L, Preiß M, et al. Initial clinical experience with the micromesh Roadsaver carotid artery stent for the treatment of patients with symptomatic carotid artery disease. *J Endovasc Ther* 2015; 22: 220-5.
27. Musialek P, Mazurek A, Trystula M, et al. Novel PARADIGM in carotid revascularisation: Prospective evaluation of All-comer perCutaneous cArOtID revascularisation in symptomatic and Increased-risk asymptomatic carotid artery stenosis using CGuard™ MicroNet-covered embolic prevention stent system. *EuroIntervention* 2016; 12: e658-70.
28. Stabile E, de Donato G, Musialek P, et al. Use of dual-layered stents in endovascular treatment of extracranial stenosis of the internal carotid artery: results of a patient-based meta-analysis of 4 clinical studies. *JACC Cardiovasc Interv* 2018; 11: 2405-11.
29. Ielasi A, Latib A, Godino C, et al. Clinical outcomes following protected carotid artery stenting in symptomatic and asymptomatic patients. *J Endovasc Ther* 2010; 17: 298-307.
30. Latacz P, Simka M, Brzegowy P, et al. Patient- and lesion-tailored algorithm of endovascular treatment for arterial occlusive disease of extracranial arteries supplying the brain: safety of the treatment at 30-day follow up. *Adv Interv Cardiol* 2017; 13: 53-61.

Submitted: 1.03.2020, **accepted:** 29.03.2020