

Laparoscopic splenectomy: posterolateral approach in patients with liver cirrhosis and portal hypertension with platelet count lower than $1 \times 10^9/l$

Guangjin Tian, Deyu Li, Haibo Yu, Yadong Dong, Senmao Mu, Huanzhou Xue

Department of Hepatobiliary Pancreatic Surgery, People's Hospital of Zhengzhou University, Henan Provincial People's Hospital, Zhengzhou, China

Videosurgery Miniinv 2018; 13 (4): 454–459
DOI: <https://doi.org/10.5114/witm.2018.77262>

Abstract

Introduction: Laparoscopic splenectomy for massive splenomegaly secondary to liver cirrhosis and portal hypertension in patients with an extremely low platelet count ($< 1 \times 10^9/l$) presents several challenges. The posterolateral laparoscopic splenectomy approach may be a feasible and safe technique for these patients.

Aim: To evaluate the feasibility and safety of the posterolateral laparoscopic splenectomy approach in patients with platelet counts $< 1 \times 10^9/l$ secondary to liver cirrhosis and portal hypertension.

Material and methods: In the period from January 2013 to December 2016, 11 patients with platelet counts $< 1 \times 10^9/l$ secondary to liver cirrhosis and portal hypertension underwent posterolateral laparoscopic splenectomy in our institution. Pre-, peri-, and postoperative medical managements were reviewed retrospectively.

Results: Patients' median platelet count was $0.7 \times 10^9/l$ at the time of inpatient admission. The median operating time was 75 min, and the median intraoperative blood loss was 30 ml. One patient underwent intraoperative transfusion. The median duration of postoperative hospital stay was 5 days. No intra- or postoperative complications ensued, all patients were followed for 12–32 months (median: 24 months), and none had postoperative complications.

Conclusions: The posterolateral laparoscopic splenectomy approach is a feasible, safe technique in the treatment of patients with platelet counts $< 1 \times 10^9/l$ secondary to liver cirrhosis and portal hypertension.

Key words: laparoscopic splenectomy, liver cirrhosis, platelet count, portal hypertension, posterolateral approach.

Introduction

Laparoscopic splenectomy (LS) was first described by Delaitre and Maignien [1] in 1991 and has become the gold-standard surgical intervention for treating primary hematological diseases, idiopathic thrombocytopenic purpura (ITP), and hypersplenism [2, 3]. The benefits of LS include minimal invasiveness and intraoperative bleeding, less pain, shorter hospital stays, and lower complication rates [4]. Many comparative clinical studies have docu-

mented the effectiveness and safety of LS versus laparotomy [5–9].

Low preoperative platelet counts affect the successful use of LS and are associated with higher morbidity, transfusion requirements, and conversion rates [10]. Therefore, a platelet count of at least $30\text{--}50 \times 10^9/l$ is recommended by most surgeons [11]. Wu *et al.* evaluated severely thrombocytopenic patients with ITP [12]; however, to our knowledge, no studies have discussed the treatment of massive splenomegaly secondary to liver cirrhosis and portal

Address for correspondence

Huanzhou Xue MD, Department of Hepatobiliary Pancreatic Surgery, People's Hospital of Zhengzhou University, Henan Provincial People's Hospital, 7 Wei Wu Road, 450003 Zhengzhou, China, phone: +86 18638548423, e-mail: 525723142@qq.com

hypertension in patients with severe thrombocytopenia. Therefore, we investigated the feasibility and safety of LS in patients with this condition.

Aim

In this study, we intended to evaluate the feasibility and safety of the posterolateral LS approach in patients with liver cirrhosis and portal hypertension, and platelet counts $< 1 \times 10^9/l$.

Material and methods

In the period from January 2013 to December 2016, 231 patients admitted to our hospital were diagnosed with splenomegaly secondary to hepatitis B or C liver cirrhosis and portal hypertension. During the same period, 136 patients underwent open splenectomy or LS, while 11 patients with a preoperative platelet count $< 1 \times 10^9/l$ underwent posterolateral LS. Preoperatively, patients underwent a detailed physical examination, abdominal ultrasonography, abdominal computed tomography, and routine biochemical and hematological tests. We retrospectively reviewed patients' preoperative, perioperative, and postoperative data, and all patients were followed for 12–32 months (median: 24 months). The study protocol was approved by the Institutional Review Board at the People's Hospital of Zhengzhou University (Henan Provincial People's Hospital), and all patients gave informed consent in writing prior to surgery.

Surgical technique

Patients were placed in the supine position, and we used the five-trocar placement technique to create access ports. Following the establishment of pneumoperitoneum, a 10-mm port was placed at the umbilicus, and a 30° laparoscope (Olympus Corporation, Tokyo, Japan) was introduced. The pressure ranged from 13 to 15 mmHg. A 5-, 10-, 12-, and 5-mm port was placed below the xiphoid, at the midpoint between the xiphoid and umbilicus, above the transection of the left anterior axillary line and umbilical horizontal line, and at the transection of the left posterior axillary line and umbilical horizontal line, respectively (Figure 1). These positions were adjustable intraoperatively. A monitor was placed on each side of the patient. The surgeon stood on the right side of the patient, and the first assistant stood on the left.

The splenogastric ligament was dissected using an ultrasonic scalpel (Olympus), and the splenic artery was identified along the upper margin of the pancreatic body and dissected. Arterial inflow was interrupted by applying a polymer Hem-o-lock clip (Teleflex Inc., Morrisville, NC, USA), and venous outflow was left unhindered to reduce splenic size and minimize blood loss during LS. The splenicocolic ligament was dissected, followed by transection of the splenorenal ligament. The splenic pedicle was mobilized along the splenic bed from the lower pole toward the upper pole and from the posterior toward the anterior side of the spleen (Photo 1). The splenodiaphragmatic ligament was then transected. Upon dissection of the splenic pedicle, the primary pedicular vessels were mobilized to a sufficient length using an ultrasonic scalpel, and the primary pedicular vessels were transected and ligated using the Endo-GIA stapling device (blue staples, length: 60 mm, height: 3.5 mm, Covidien/Medtronic, Boulder, CO, USA) (Photo 2). The short gastric vessels were transected and ligated using the Endo-GIA sta-

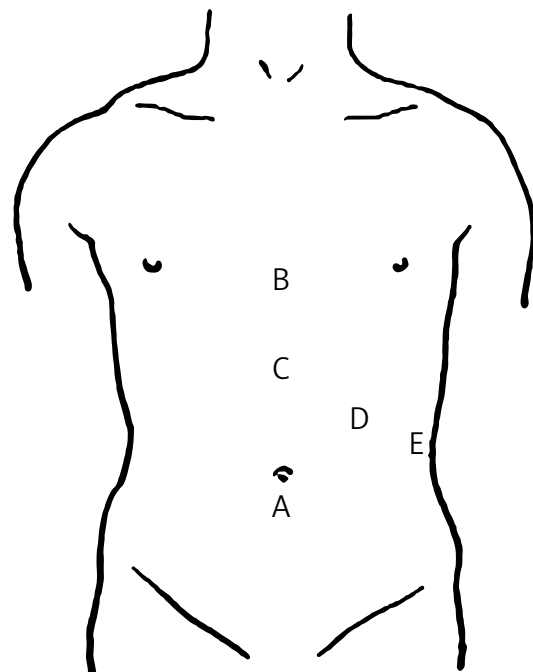


Figure 1. Positions of the trocar ports in laparoscopic splenectomy. A – 10-mm port for the laparoscope, B – 5-mm port for the grasper to expose the splenic hilum, C – 10-mm main manipulation port, D – 12-mm port for the Endo-GIA stapler, E – 5-mm additional manipulation port

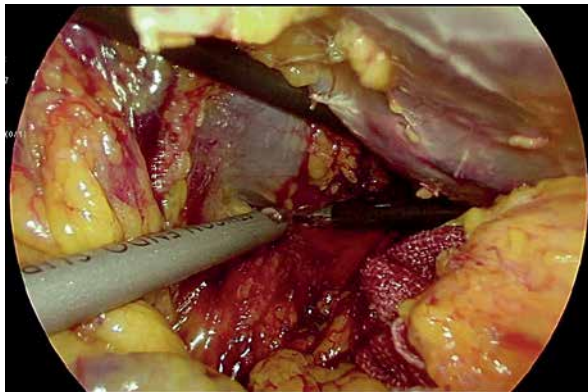


Photo 1. Dissection and transection of the splenic bed via the posterolateral approach

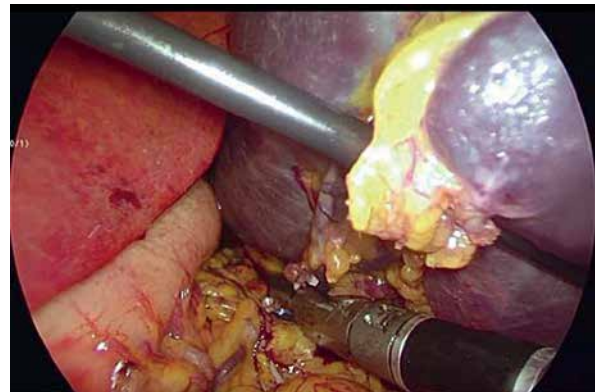


Photo 2. Transection of the primary pedicular vessels using the Endo-GIA stapler

pler (white staples, length: 60 mm, height: 2.5 mm, Covidien/Medtronic) or polymer Hem-o-lock clips (Teleflex). The spleen was divided into 3 or 4 sections which were enclosed in a specimen bag, morcellated, and removed through the 12-mm port for pathological examination. Patients were prescribed aspirin starting on postoperative day 2 to minimize portal thrombosis.

Statistical analysis

IBM SPSS Statistics for Windows, Version 20.0 (IBM Corp., Armonk, NY, USA) was used for the statistical analysis. All categorical data were expressed

as frequency with percentage and were compared using Fisher’s exact test. All numerical data were expressed as medians. We performed trend analyses for certain variables using repeated ANOVA measures. Statistical significance was defined as a *p*-value < 0.05.

Results

Clinical features

The clinical features of the 11 patients are summarized in Table I. The median patient age was 54 years (range: 45–65 years), and 7 (57%) patients were men. On admission, the median platelet count

Table I. Clinical features of all patients undergoing LS

Parameter	Patient											Median
	1	2	3	4	5	6	7	8	9	10	11	
Gender	F	M	M	F	M	F	M	F	M	M	M	–
Age [years]	45	53	64	65	54	49	51	60	57	58	51	54
PLT [$\times 10^9/l$]	0.8	0.6	0.5	0.9	0.8	0.7	0.4	0.3	0.7	0.3	0.8	0.7
Hgb [g/l]	89	92	101	97	96	84	87	112	108	88	97	96.0
WBC [$\times 10^9/l$]	2.5	2.0	1.2	1.9	2.0	1.8	1.0	0.9	1.3	1.2	1.8	1.8
PT [s]	15.6	16.3	17.1	16.5	14.9	14.8	17.5	16.7	15.9	17.7	16.8	16.5
APTT [s]	33.9	34.2	35.1	37.8	38.3	37.6	34.5	38.4	36.5	35.8	36.3	36.3
TT [s]	26.7	25.4	26.8	27.2	28.0	25.5	25.9	25.3	25.9	26.3	27.1	26.3
FIB [g/l]	3.9	3.7	3.9	3.9	3.8	4.0	3.8	4.0	3.6	4.0	3.9	3.9
INR	3.0	3.2	3.1	3.0	2.9	2.7	2.9	2.8	2.9	3.5	3.0	3.0

APTT – activated thromboplastin time, F – female, FIB – fibrinogen, Hgb – hemoglobin, INR – international normalized ratio, LS – laparoscopic splenectomy, M – male, PLT – platelet count, PT – prothrombin time, TT – thrombin time, WBC – white blood cell count.

was $0.7 \times 10^9/l$. Other (median) parameters were hemoglobin level: 96.0 g/l, white blood cell count: $1.8 \times 10^9/l$, prothrombin time: 16.5 s, activated thromboplastin time: 36.3 s, thrombin time: 26.3 s, fibrinogen: 3.9 g/l, and international normalized ratio: 3.0.

Perioperative details

Patients' perioperative details are shown in Table II. All patients received fresh-frozen plasma and cryoprecipitate to maintain a target international normalized ratio of 0.8–1.5 and received one unit of platelets 30 min before LS. No patients underwent conversion to laparotomy. Median operating time was 75 min, and median intraoperative blood loss was 30 ml. Patient 6 received an intraoperative transfusion of two units of packed red blood cells combined with 400 ml of fresh-frozen plasma during LS. The median postoperative hospital stay was 5 days. On postoperative day 3 and at the last visit, the median platelet counts were $537.0 \times 10^9/l$ and $262.0 \times 10^9/l$, respectively. All patients received anticoagulant therapies to avoid portal vein thrombosis, and 2 patients (patients 3 and 6) developed portal vein thrombosis.

Efficacy of laparoscopic splenectomy

Patients' hematological responses are shown in Table III. On postoperative day 3, the median platelet count increased sharply to $537.0 \times 10^9/l$; however, at the last visit, the platelet count was $262.0 \times 10^9/l$. Patients' hemoglobin levels and white blood cell counts also increased. Significant differences were found in changing trends for platelet count, hemoglobin level, and white blood cell count ($p < 0.05$). We saw a non-significant difference in INR changing trends ($p > 0.05$), which changed because of the anticoagulant therapies. No differences were found in other coagulation function regarding changing trends ($p > 0.05$).

Pathological and follow-up outcomes

Pathological examination revealed congestive splenomegaly in all patients. Patients' routine hematological test results were normal, and no postoperative bleeding, pancreatic fistula formation, or deaths occurred. By 3 months postoperatively, portal vein thrombosis had occurred in 2 patients (patients 3 and 6), which resolved with administration of 2.5 mg oral coumarin once daily with dose titration

Table II. Perioperative details for patients undergoing LS

Parameter	Patient											Median
	1	2	3	4	5	6	7	8	9	10	11	
Operative time [min]	80	75	80	75	80	95	75	70	80	75	65	75
Blood loss [ml]	20	30	40	30	20	50	30	20	30	20	10	30
PLT transfusion [U]	1	1	1	1	1	1	1	1	1	1	1	
Other transfusion	–	–	–	–	–	+	–	–	–	–	–	
Conversion	/	/	/	/	/	/	/	/	/	/	/	
PHS [days]	5	4	5	5	6	7	4	5	6	5	4	5
3 days after LS												
PLT [$\times 10^9/l$]	513	540	524	533	521	545	538	546	537	522	565	537.0
Last visit [months]	32	29	26	24	23	25	26	22	20	16	12	24
PLT [$\times 10^9/l$]	268	258	277	254	265	287	251	262	285	254	261	262.0
PVT	–	–	+	–	–	+	–	–	–	–	–	

LS – laparoscopic splenectomy, PHS – postoperative hospital stay, PLT – platelet count, PVT – portal vein thrombosis.

Table III. Laboratory examination before and after LS (medians)

Parameter	Inpatient	LS	3 days after LS	Last visit	P-value*
PLT [$\times 10^9/l$]	0.7	0.7	537.0	262.0	< 0.05
Hgb [g/l]	96.0	100.0	109.0	117.0	< 0.05
WBC [$\times 10^9/l$]	1.8	2.3	15.9	4.8	< 0.05
PT [s]	16.5	15.7	15.9	15.7	> 0.05
APTT [s]	36.3	35.0	36.8	36.4	> 0.05
TT [s]	26.3	25.8	26.2	26.0	> 0.05
FIB [g/l]	3.9	3.6	3.8	3.7	> 0.05
INR	3.0	1.2	3.1	3.2	< 0.05

APTT – activated thromboplastin time, FIB – fibrinogen, Hgb – hemoglobin, INR – international normalized ratio, LS – laparoscopic splenectomy, PLT – platelet count, PT – prothrombin time, TT – thrombin time, WBC – white blood cell count. *Repeated measures analysis of variance.

to maintain a target international normalized ratio of 2.0–3.0 for 1 year.

Discussion

Laparoscopic splenectomy has become the gold-standard procedure for splenectomy [13] in many centers since its introduction in 1992. The indications for LS are primarily hematological diseases, ITP, splenic hamartoma, and hypersplenism. Refinements in laparoscopic techniques and instruments, and increased clinical experience, have resulted in multiple modifications and refinements in LS [14, 15]. Laparoscopic splenectomy procedures are now safer and more efficient [16]; however, much of the literature supports the role of LS in patients with platelet counts $> 30 \times 10^9/l$ [11]. Other than one study by Wu *et al.* evaluating LS to treat severely thrombocytopenic patients with ITP [12], there is little information on LS in patients with very low platelet counts secondary to liver cirrhosis and portal hypertension. Poor visualization, enormous spleen size, and the presence of varicose vessels and coagulation disorders, intraoperative hemorrhage, and severe oozing of blood from the cut edge of the spleen are the biggest challenges in LS in patients with extremely low platelet counts [17, 18]. Whether LS is indicated for patients with liver cirrhosis and portal hypertension with platelet counts $< 1 \times 10^9/l$ remains controversial.

The posterolateral LS approach involves dissection and transection of the perisplenic ligaments from the posterolateral face of the spleen, where the

adipose tissue is loose and there are no perisplenic varices, reducing the frequency of intraoperative bleeding. As a result, the posterolateral approach provides good visualization of the splenic hilum from the posterior side of the spleen. The low frequency of bleeding reduces the rate of conversion to open surgery and shortens the operative time [19]. After transecting the splenic bed, the spleen can be gently manipulated and suspended, providing good visualization of the splenic hilum. The spleen is also pulled downward by gravity, which stretches the gastrosplenic ligament and expands the operative field [20, 21]. These effects permit forward dissection and transection of the gastrosplenic ligament and short gastric vessels, reducing intraoperative hemorrhage. Our results demonstrate that the posterolateral LS approach provides good surgical outcomes, shortens the LS operation time, and reduces intraoperative blood and oozing. Less intraoperative blood loss also minimizes the requirement for blood transfusion.

Excessive dissection may result in massive bleeding and secondary injury. In the posterolateral approach, there is no need for precise transection of the splenic pedicle and no need to reserve enough space for dissection and transection. This holds true especially in the rear or deep parts of the tissue, where it is easy to miss bleeding or to damage the surrounding tissues because of limited vision or exposure. The posterolateral approach also offers good visualization of the pancreatic tail and facilitates its dissection away from the splenic hilum. This, in turn, provides enough space to transect the splenic hilum with the Endo-GIA stapler [21], reducing the

frequency of bleeding and pancreatic fistula. With the Endo-GIA device [22], cutting and stapling are nearly simultaneous, also reducing the risk of bleeding, especially in thick or edematous tissue. As a result, dissection and transection of the splenic pedicle with the stapling device reduces bleeding and minimizes the occurrence of pancreatic tail injury and fistula formation [23, 24]. We dissected the pancreatic tail from the posterior side of the spleen and then transected the primary pedicular vessels with the stapler, reducing the risk of incidental bleeding and shortening the operating time, eliminating the need for excessive dissection, and reducing the risk of pancreatic fistula formation.

Conclusions

The posterolateral LS approach was associated with a good surgical field and no excessive dissection; shortened operation time and hospital stay; and reduced intraoperative blood loss. The posterolateral LS approach is safe and feasible in patients with platelet counts $< 1 \times 10^9/l$ secondary to liver cirrhosis and portal hypertension.

Conflict of interest

The authors declare no conflict of interest.

References

1. Delaitre B, Maignien B. Laparoscopic splenectomy-technical aspects. *Surg Endosc* 1992; 6: 305-8.
2. Esposito C, Schaarschmidt K, Settini A, Montupet P. Experience with laparoscopic splenectomy. *J Pediatr Surg* 2001; 36: 309-11.
3. Bai YN, Jiang H, Prasoon P. A meta-analysis of perioperative outcomes of laparoscopic splenectomy for hematological disorders. *World J Surg* 2012; 36: 2349-58.
4. Kucuk C, Sozuer E, Ok E, et al. Laparoscopic versus open splenectomy in the management of benign and malign hematologic diseases: a ten-year single-center experience. *J Laparoendosc Adv Surg Tech A* 2005; 15: 135-9.
5. Friedman RL, Hiatt JR, Korman JL, et al. Laparoscopic or open splenectomy for hematologic disease: which approach is superior? *J Am Coll Surg* 1997; 185: 49-54.
6. Glasgow R, Yee L, Mulvihill S. Laparoscopic splenectomy: the emerging standard. *Surg Endosc* 1997; 11: 108-12.
7. Watson DI, Coventry BJ, Chin T, et al. Laparoscopic versus open splenectomy for immune thrombocytopenic purpura. *Surgery* 1997; 121: 18-22.
8. Park AE, Birgisson G, Mastrangelo MJ, et al. Laparoscopic splenectomy: outcomes and lessons learned from over 200 cases. *Surgery* 2000; 128: 660-7.
9. Cordera F, Long KH, Nagorney DM. Open versus laparoscopic splenectomy for idiopathic thrombocytopenic purpura: clinical and economic analysis. *Surgery* 2003; 134: 45-52.
10. Chen XD, Peng B, Cai YQ, et al. Laparoscopic splenectomy for patients with immune thrombocytopenia and very low platelet count: is platelet transfusion necessary? *J Surg Res* 2011; 170: 225-32.
11. Habermalz B, Sauerland S, Decker G, et al. Laparoscopic splenectomy: the clinical practice guidelines of the European Association for Endoscopic Surgery (EAES). *Surg Endosc* 2008; 22: 821-48.
12. Wu Z, Zhou J, Pankaj P, et al. Laparoscopic splenectomy for immune thrombocytopenia (ITP) patients with platelet counts lower than $1 \times 10^9/L$. *Int J Hematol* 2011; 94: 533-8.
13. Gigot JF, Etienne J, Lengele B, et al. Elective laparoscopic splenectomy: person experience and literature review. *Semin Laparosc Surg* 1996; 3: 34-43.
14. Su CH, Yin TC, Huang CJ, et al. Laparoscopic splenectomy for splenomegaly using a homemade retrieval BAG. *Videosurgery Miniinv* 2013; 8: 327-33.
15. Cabras F, Fabrizio L, Bracale U, et al. Single incision laparoscopic splenectomy, technical aspects and feasibility consideration. *Videosurgery Miniinv* 2014; 9: 632-3.
16. Kawanaka H, Akahoshi T, Kinjo N, et al. Technical standardization of laparoscopic splenectomy harmonized with hand-assisted laparoscopic surgery for patients with liver cirrhosis and hypersplenism. *J Hepatobiliary Pancreat Surg* 2009; 16: 272-9.
17. Park AE, Birgisson G, Mastrangelo MJ, et al. Laparoscopic splenectomy: outcomes and lessons learned from over 200 cases. *Surgery* 2000; 128: 660-7.
18. Grahn SW, Alvarez J 3rd, Kirkwood K. Trend in laparoscopic splenectomy for massive splenomegaly. *Arch Surg* 2006; 141: 755-62.
19. Trias M, Targar EM, Balague C. Laparoscopic splenectomy: an evolving technique. A comparison between anterior and lateral approaches. *Surg Endosc* 1996; 10: 389-92.
20. Kuriansky J, Ben Chaim M, Rosin D, et al. Posterolateral approach: an alternative strategy in laparoscopic splenectomy. *Surg Endosc* 1998; 12: 898-900.
21. Park A, Gagner M, Pomp A. The lateral approach to laparoscopic splenectomy. *Am J Surg* 1997; 173: 126-30.
22. Trelles N, Gagner M, Pomp A, et al. Laparoscopic splenectomy for massive splenomegaly: technical aspects of initial ligation of splenic artery and extraction without hand-assisted technique. *J Laparoendosc Adv Surg* 2008; 18: 391-5.
23. Vecchio R, Gelardi V, Intagliata E, et al. How to prevent intraoperative risks and complication in laparoscopic splenectomy. *G Chir* 2010; 31: 55-61.
24. Vargun R, Gollu G, Fitöz S, et al. En-bloc stapling of the splenic hilum in laparoscopic splenectomy. *Minim Invasive Ther Allied Technol* 2007; 16: 360-2.

Received: 24.02.2018, accepted: 6.06.2018.