

Hybrid technique for postoperative ventral hernias – own experience

Monika Romanowska, Tomasz Okniński, Jacek Pawlak

Department of General Surgery, John Paul II Specialist Western Hospital, Grodzisk Mazowiecki, Poland

Videosurgery Miniinv 2015; 10 (4): 534–540

DOI: 10.5114/wiitm.2015.55689

Abstract

Introduction: There are many techniques which may be involved in abdominal hernia repair, from classical to tension-free. Treatment of complicated hernias has undergone evolution. Many surgeons consider the laparoscopic method as a method of choice for incisional hernia repair. Sometimes miniinvasive repair of complicated hernia is not so easy to perform. We are convinced that selected patients may benefit from combined open and laparoscopic techniques.

Aim: To present the operating technique and early results of treatment of 15 patients operated on using the 3 hybrid technique.

Material and methods: Fifteen patients suffering from recurrent incisional hernias underwent the hybrid technique for their repair between June 2012 and April 2015. The hybrid technique was performed using synthetic meshes in 14 cases and a biological implant in 1 case.

Results: The early postoperative period was uncomplicated in all cases. Within a maximum follow-up period of 32 months, two deep wound infections were observed.

Conclusions: The hybrid technique may be used in patients with recurrent incisional hernias.

Key words: synthetic materials, recurrent hernia, hybrid technique.

Introduction

Postoperative hernia is the most common complication of abdominal surgery worldwide. Incisional hernias complicate 2% to 20% of laparotomies and depend on the type of surgical technique, the method used to close the abdomen and many factors connected with the patient (age, elevated body mass index, comorbidities, previous surgery) [1, 2]. A high rate of recurrence in 20% to 50% of patients after the primary repair of the defect is another problem [3, 4]. Many complications after an open operation, as well as technological progress, associated with innovations in synthetic materials covered by anti-adhesive substance of the ventral side, have led

to the development of laparoscopic surgery [5, 6]. This method offers many advantages: minimal pain, shorter stay in hospital, quicker return to activities, and ability to identify additional defects in the abdominal wall [7, 8]. But in some difficult cases, defects are very large, and even after laparoscopic repair, patients are unhappy because of the cosmetic appearance of their wound. Moreover, sometimes miniinvasive repair of a complicated postoperative hernia is not easy to perform due to massive adhesions after the primary operation, which is especially dangerous during placement of laparoscopic tools into the abdominal cavity. For these reasons, we are convinced that it is worth combining the two techniques, open and laparoscopic, to maximize the benefits of both methods.

Address for correspondence

Monika Romanowska, Department of General Surgery, John Paul II Specialist Western Hospital, 11 Daleka St, 05-825 Grodzisk Mazowiecki, Poland, phone: +48 605 762 793, e-mail: monika.meszka@gmail.com

Infections associated with incisional hernias are another problem. The use of new materials, such as biological implants, is thought to be the most suitable treatment. Collagen matrix can support tissue regeneration through neovascularization and fibroblastic cell re-population, leading to endogenous collagen formation. The use of biological materials has increased in recent years, despite their high cost and lack of convicting evidence [9–11].

Aim

The aim of the study is to present the combined operating technique and the early results of the treatment of 15 patients using this method in the Department of General Surgery in the John Paul II Specialist Western Hospital in Grodzisk Mazowiecki.

Material and methods

Fifteen patients suffering from complicated incisional hernias underwent a hybrid technique for their repair between 2012 and 2015 (from 1 June 2012 until 31 March 2015) in the Department of General Surgery

of the Specialist Western Hospital in Grodzisk Mazowiecki. The group consisted of 9 men and 6 women, at the average age of 65. Characteristics of patients are presented in Table I. Types of performed operations and postoperative complications are presented in Table II. In 1 case, there was recurrent incisional hernia after cystectomy which was primarily repaired using a Permacol mesh. This postoperative course was complicated by an enterocutaneous fistula (Photo 1). Two patients had recurrent incisional hernias after the operation of sigmoid cancer, also complicated by the appearance of an enterocutaneous fistula, and 1 woman had a large recurrent hernia after the operation of perforated sigmoid diverticulum (Hartmann's procedure) and an anastomosis of the remaining part of the colon afterwards. All cases of enterocutaneous fistulas were revealed at a different time after the operations (Table II). We used drainage and total parenteral nutrition as treatment of all fistulas. This approach was effective, and the fistulas closed after several weeks of such treatment. Another 6 patients suffered from hernias after cholecystectomy complicated by wound infection or had several open

Table I. Characteristics of patients

No.	Gender	Age [years]	BMI [kg/m ²]	Comorbidities
1	Male	80	28.5	Diabetes, hypertension, renal failure, arterial fibrillation chemotherapy in the past (sigmoid cancer)
2	Male	61	25.4	Hypertension
3	Male	76	26.7	Diabetes, hypertension, ischaemic heart disease rheumatoid arthritis
4	Female	52	26.2	Hypertension
5	Female	63	27.3	Hypertension
6	Female	81	29	Diabetes, hypertension, chronic obstructive pulmonary disease, ischaemic heart disease, atrial fibrillation
7	Male	68	31.2	Diabetes, renal failure, hypertension, after two cerebrovascular accidents
8	Female	49	23	
9	Male	75	24.7	Ischaemic heart disease, radiation therapy in the past (laryngeal cancer)
10	Male	78	25.3	Hypertension, ischaemic heart disease, diabetes, rheumatoid arthritis, renal failure
11	Female	63	23.5	Hypertension
12	Male	39	24.1	
13	Male	73	26.1	Diabetes, atrial fibrillation, chronic obstructive pulmonary disease, hypertension
14	Male	65	22	Ischaemic heart disease, diabetes
15	Female	62	28	Ischaemic heart disease, renal failure, hypertension

Table II. Types of performed operations and postoperative complications

No.	Previous operations	Postoperative complications
1	Hartmann's procedure – sigmoid cancer	
	Transverse-rectal anastomosis	Enterocutaneous fistula (6 days after second operation)
	Skin graft	Incisional hernia
	Open hernia repair with synthetic mesh	Recurrence
2	Cystectomy	Incisional hernia
	Open hernia repair with biologic implant (Permacol)	Enterocutaneous fistula (10 days after second operation)
3	Sigmoid resection – sigmoid cancer	Enterocutaneous fistula (7 days after resection)
	Open hernia repair	Recurrence
4	Hartmann's procedure – perforated sigmoid diverticulum	
	Transverse – rectal anastomosis	Incisional hernia
	Open hernia repair	Recurrence
5	Cholecystectomy	Incisional hernia
	Open hernia repair	Recurrence
	Open hernia repair with synthetic mesh	Recurrence
6	Cholecystectomy (appendectomy in the past)	Bleeding
	Relaparotomy	Wound infection, incisional hernia
	Open hernia repair	Recurrence
7	Cholecystectomy	Incisional hernia
	Open hernia repair	Recurrence
	IPOM	Recurrence
8	Laparoscopic cholecystectomy with conversion (hysterectomy in the past)	Bile leakage
	Relaparotomy	Wound infection, incisional hernia
	Open hernia repair	Recurrence
9	Laparoscopic cholecystectomy with conversion	Wound infection, incisional hernia
	Open hernia repair	Recurrence
10	Left nephrectomy (adenocarcinoma)	
	Stomach resection (cancer)	
	Right hemicolectomy (ischaemia of the right colon)	Incisional hernia after right hemicolectomy
	Cholecystectomy and hernia repair	Recurrence
	Open hernia repair with synthetic mesh	Recurrence
11	Appendectomy	Wound infection, incisional hernia
	Open hernia repair	Recurrence
12	Laparoscopy, conversion, appendectomy	Wound infection, incisional hernia
	Open hernia repair	Recurrence
13	Appendectomy	Wound infection, incisional hernia
	Open hernia repair with synthetic mesh	Recurrence

Table II. Cont.

No.	Previous operations	Postoperative complications
14	Appendectomy in the past	
	Hysterectomy 1979	
	Cholecystectomy 1998	
	Peptic ulcer perforation 2001	Huge ventral hernia
15	Appendectomy	Incisional hernia
	Open hernia repair	Recurrence
	IPOM	Bleeding, haemorrhagic shock
	Relaparotomy, removal of mesh	Ventral hernia

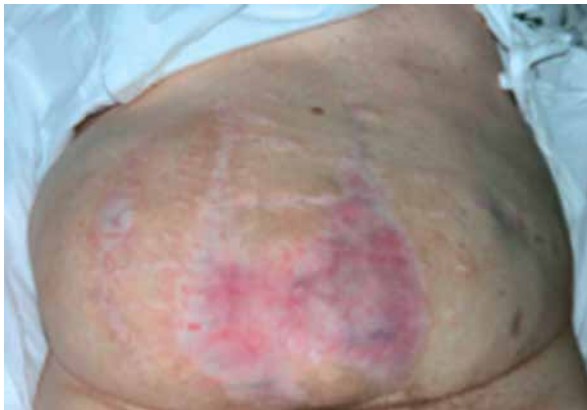

Photo 1. Recurrent hernia after laparotomy and the primary suture repair complicated by wound infection

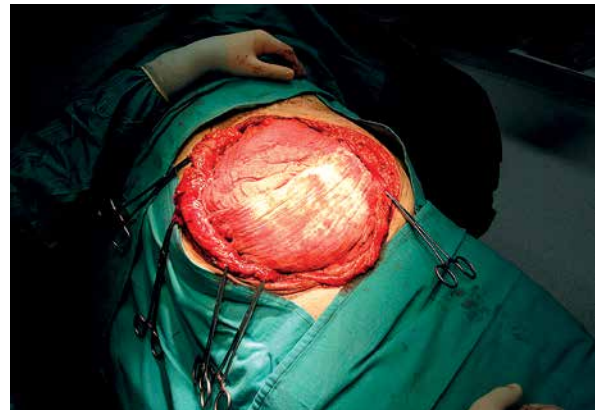

Photo 2. Open part of the operation. Perioperative view after removing large scar

repairs of hernias. In this group there was 1 patient with a body mass index above 31 kg/m², referred to our department from the emergency unit with symptoms suggesting intestinal occlusion. Three patients had recurrent hernia after appendectomy complicated by wound infection and open repair of the hernia afterwards. One patient had a huge hernia after numerous laparotomies (cholecystectomy, hysterectomy, appendectomy, peptic ulcer perforation), and 1 patient after open repair of hernia after appendectomy, laparoscopic intraperitoneal onlay mesh (IPOM) repair of recurrent hernia complicated by haemorrhagic shock requiring removal of the mesh during urgent relaparotomy afterwards.

In 14 cases the combined procedure was performed by using synthetic materials covered from one side (the abdominal cavity) by a substance which creates a thin layer to keep the mesh from adhering to intra-abdominal organs. We used four types of these materials: Ventralight, Parietex,

DualMesh and C-qur. In 1 case a biological implant (Periguard) was used. Sizes of meshes depended on the size of hernias and were approximately 15 cm × 20 cm or 20 cm × 30 cm.

Operating technique

The open part of the operation (laparotomy) ensured extensive and safe adhesiolysis, reduction of the hernia content into the peritoneal cavity, proper placement of the laparoscopic tools and mesh into the peritoneal cavity (Photo 2), minimization of the risk of intestinal perforation, and the closure of the abdominal wall, sometimes using sutures which prevent dehiscence. The next step was the laparoscopic part of the procedure, intraperitoneal placement of the mesh after the reduction of the intraperitoneal pressure to 7–8 mm Hg. The mesh should have appropriate size, covering the actual hernia size edges for at least 5–7 cm, and then it is laparoscopically fixed with transfascial stay stitches (Protac or Absor-

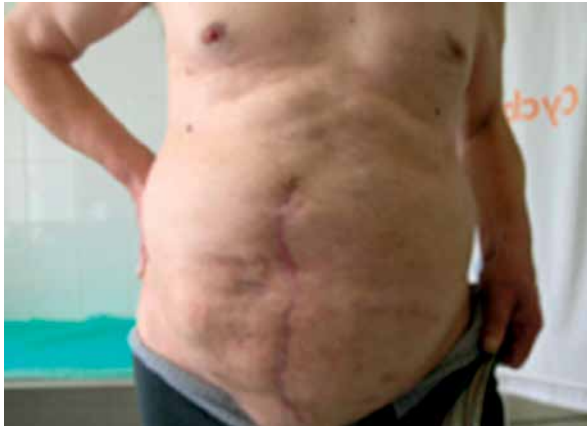

Photo 3. Postoperative appearance 6 months after the hybrid repair

batack). The total operative time ranged from 100 to 180 min.

Results

The best therapeutic and cosmetic result can be achieved by using the combined laparoscopic and open technique. Within a maximum follow-up period of 32 months, in spite of standard antibiotic prophylaxis (one dose of ceftriaxone 30 min before the operation) used in our department, two deep wound infections were observed. In a 65-year-old patient with diabetes and ischaemic heart disease, infection occurred 2 months after hybrid repair with a biological implant (Periguard). Another patient was 78 with diabetes, ischaemic heart disease, renal failure, after cancer surgery (stomach resection) and right hemicolectomy; infection occurred 4 months after hybrid repair with synthetic mesh (Parietex). Both patients were operated on and infected meshes were removed.

In the other cases the postoperative course was uneventful. Moreover, postoperative pain has remained within 2–4 on the Visual Analogue Scale. Within our follow-up period, there were no signs of recurrence of hernia or worsening quality of life.

Discussion

The technological progress achieved in the area of polymerization and production of new synthetic meshes contributes to the improvement of the surgical technique for incisional hernia repair. Open mesh repairs have a recurrence rate of 10% to 20%, but the number of serious complications appear-

ing in the postoperative course (e.g. pain, infection, seroma formation) is rather high. In 1993, LeBlanc and Booth were the first to use a special synthetic mesh in the laparoscopic procedure [12]. It was a big step in the treatment of ventral hernia, and from that time the miniinvasive mesh repair has rapidly become accepted among general surgeons for multiple reasons. It has a remarkably low recurrence rate across many series. Moreover, many authors have highlighted the lower incidence of perioperative complications and shorter hospital stay [13–16]. Another value of the laparoscopic procedure is the improved visualization offered by modern optical tools to reduce the incidence of missed hernias and easy fixation of a large mesh to the abdominal wall. The benefits of laparoscopy in obese patients with regards to exposure and decreased wound complications make this technique ideal. However, there are still some problems connected with complicated, large incisional hernias, including the frequency of seromas, unchanged scar appearance, and massive adhesions after previous operations (especially dangerous during placement of laparoscopic tools into the abdominal cavity). We are convinced that these problems could be solved by combining the two surgical techniques. The open technique ensures safe adhesiolysis, minimizing perforation of abdominal organs, the ability to place a large mesh into the abdominal cavity, and better cosmetic appearance of a single midline incision (Photo 3). According to initial reports of some authors, by using the combined technique, the ultimate results would be the minimal recurrence and hospital stay similar to laparoscopic mesh repair [17–20]. Nowadays, in our department the combined technique is the method of choice for the repair of complicated, recurrent incisional hernias. Unfortunately, the very high costs of the operation and synthetic materials needed limit the opportunities to perform this method.

Despite considerable improvements in incisional hernia treatment, contaminations or infections associated with incisional hernias remain a challenge for many surgeons. The use of innovative materials, such as biological implants, is thought to be a suitable choice in such situations. Recently, the list of biologic available materials is getting longer. They differ based on their source (human or animal), composition (dermal, pericardial or submucosa) and methods of processing (stripping, cross-linking). Biological grafts are acellular collagen matrices implant-

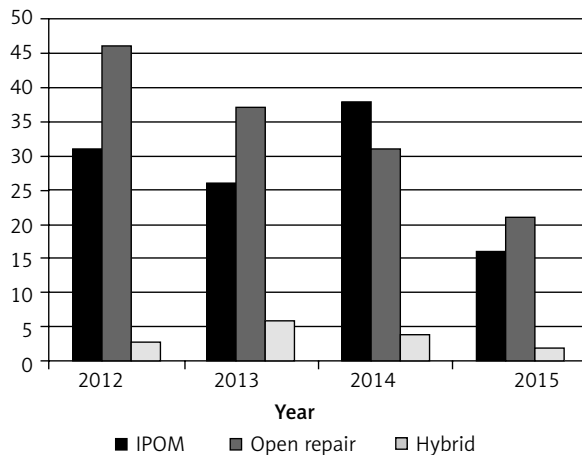


Figure 1. Distribution of open, IPOM and hybrid techniques in our department

ed during hernia repair to facilitate native tissue incorporation. Some authors report use of biological implants in hernia repair in a potentially contaminated or infected surgical field [9, 21–23]. In our research one deep infection was observed after hybrid implantation of bovine pericardium cross-linked with glutaraldehyde (Periguard) in a patient with higher risk of infection. Systemic antibiotic therapy was not used as routine in this case because we were convinced that it was not necessary.

Conclusions

The authors are convinced that it is impossible to compare the results presented in the article to a group of patients treated using other methods. Patients operated on using the hybrid technique comprise a small, specially selected group, often with many comorbidities, after numerous complicated operations including open or laparoscopic hernia repair. The distribution of open, IPOM and hybrid techniques in our department between 2012 and 2015 is presented in Figure 1. Moreover, anatomical location of the defects, the type of mesh and the fixation methods used in the hybrid technique may differ from the ones used in open or laparoscopic IPOM.

In our view, the combined technique presented in this report proved to be an optimal and safe solution in cases of recurrent, complicated, large incisional or ventral hernias. A longer follow-up period is required to evaluate the effectiveness of the method. We are also convinced that more evidence is needed in order to determine situations where expensive meshes might be justified.

Conflict of interest

The authors declare no conflict of interest.

References

- Mackiewicz Z. The modern treatment of ventral hernias. PZWL, Warsaw 2006; 152-9.
- Jankins E, Yom V, Melman L, et al. Clinical predictors of operative complexity in laparoscopic ventral hernia repair: a prospective study. *Surg Endosc* 2010; 24: 1872-7.
- Lee Y, Iqbal A, Vitamvas M, et al. Is it safe to perform laparoscopic ventral hernia repair with mesh in elderly patients? *Hernia* 2008; 12: 239-42.
- Romańczuk M, Mitura K, Wróblewski T. A comparison of methods and results of ventral incisional hernia repair. *Videosurgery Miniinv* 2006; 1: 95-100.
- Wysocki A, Budzyński P. Implants in surgery of hernias. *Med Prakt* 2010; 1: 9-15.
- Janczak D, Litarski A, Merenda M. Use of synthetic mesh in abdominal wall hernias repair. *Polimery w Medycynie* 2011; 41: 13-8.
- Carlson MA, Frantzides CT, Shostrom VK, et al. Minimally invasive ventral herniorrhaphy: an analysis of 6,266 published cases. *Hernia* 2008; 12: 9-22.
- Sajid MS, Bokhari SA, Mallick AS, et al. Laparoscopic versus open repair of incisional/ventral hernia: a meta-analysis. *Am J Surg* 2009; 197: 64-72.
- Mariette C, Briez N, Denies F, et al. Use of biological mesh versus standard wound care in infected incisional ventral hernias, the SIMBIOSE study: a study protocol for a randomized multicenter controlled trial. *Trials* 2013; 14: 131 (<http://www.trials-journal.com/content/14/1/131>).
- Campanelli G, Catena F, Ansaloni L. Prosthetic abdominal wall hernia repair in emergency surgery: from polypropylene to biological meshes. *World J Emerg Surg* 2008; 3: 33.
- El-Hayek KM, Chand B. Biologic prosthetic materials for hernia repairs. *J Long Term Eff Med Implants* 2010; 20: 159-69.
- LeBlanc K, Booth WF. Laparoscopic repair of incisional abdominal hernias using expanded polytetrafluoroethylene: preliminary findings. *Surg Laparoscopic Endosc* 1993; 3: 39-41.
- McKinlay RD, Park A. Laparoscopic ventral incisional hernia repair: a more effective alternative to conventional repair of recurrent incisional hernia. *J Gastrointest Surg* 2004; 8: 670-4.
- Bencini L, Sanchez LJ, Bofii B, et al. Incisional hernia repair retrospective comparison of laparoscopic and open techniques. *Surg Endosc* 2003; 17: 1546-51.
- Śmietański M, Bigda J, Iwan K, et al. Assessment of usefulness of different tacks in laparoscopic ventral hernia repair (IPOM). *Surg Endosc* 2007; 21: 925-8.
- Trojanowski P, Kwiatkowski A, Paśnik K, et al. Modern methods of treatment of incisional hernias. *Pol Merk Lek* 2009; 26: 569-71.
- Griniatsos J, Yiannakopoulou E, Tsechpenakis A, et al. A hybrid technique for recurrent incisional hernia repair. *Surg Laparosc Endosc Percutan Tech* 2009; 19: 177-80.
- Ji Y, Zhan X, Wang Y, et al. Combined laparoscopic and open technique for the repair of large complicated incisional hernias. *Surg Endosc* 2013; 27: 1778-83.

19. Neff M, Cantor B, Geins WP. Laparoscopic-assisted primary repair of a complicated ventral incisional hernia. *JSL* 2005; 9: 241-4.
20. Staikes N, Quasebarth M, Brunt LM. Hybrid ventral hernia repair: techniques and results. *Hernia* 2013; 17: 627-32.
21. Alaedeen DI, Lipman J. The single-staged approach to the surgical management of abdominal wall hernias in contaminated fields. *Hernia* 2006; 11: 41-5.
22. Bilsel Y, Abci I. The search for ideal hernia repair: mesh materials and types. *Int J Surg* 2012; 10: 317-21.
23. Montgomery A. The battle between biological and synthetic meshes in ventral hernia repair. *Hernia* 2013; 17: 3-11.

Received: 7.06.2015, **accepted:** 20.10.2015.