

Incidence of true short esophagus among patients submitted to laparoscopic Nissen fundoplication

Marcin Migaczewski, Anna Zub-Pokrowiecka, Agata Grzesiak-Kuik, Michał Pędziwiatr, Piotr Major, Mateusz Rubinkiewicz, Marek Winiarski, Michał Natkaniec, Andrzej Budzyński

Second Department of General Surgery, Jagiellonian University Medical College, Krakow, Poland

Videosurgery Miniinv 2015; 10 (1): 10–14

DOI: 10.5114/wiitm.2015.48571

Abstract

Introduction: The last two decades have observed development of surgical treatment of benign conditions of the gastroesophageal junction (GEJ), including anti-reflux surgery, due to the growing popularity of the laparoscopic approach. Migration of the fundoplication band and recurrent hiatal hernia are a result of the lack of correct diagnosis and appropriate management of the so-called short esophagus. According to various authors, short esophagus is present in up to 60% of patients qualified for anti-reflux surgery. However, some researchers question the existence of this condition.

Aim: To analyze the prevalence of short esophagus in patients subjected to laparoscopic Nissen fundoplication.

Material and methods: The study included 202 patients who were subjected to laparoscopic Nissen fundoplication.

Results: As many as 96% of the patients qualified for the surgical treatment showed supradiaphragmatic location of the high pressure zone. The extent of GEJ protrusion ranged from 0 cm to 3 cm (mean: 2 cm). The extent of dissection within the mediastinum was determined by the level of GEJ protrusion, and ranged from 5 cm to 12 cm (mean: 6 cm). Upon complete mobilization of the esophagus within the mediastinum, no cases of significantly shortened esophagus, precluding downward retraction of at least a 2.5-cm segment below the diaphragmatic crura, were documented. Therefore, none of the patients required Collis gastroplasty.

Conclusions: The presence of “true” short esophagus is a sporadic finding among patients qualified for anti-reflux surgery. Mediastinal dissection of the esophagus and its mobilization at an appropriate, individually defined level seems a sufficient treatment in the vast majority of these patients.

Key words: laparoscopy, Nissen fundoplication, antireflux surgery, short esophagus.

Introduction

The last two decades have observed development of surgical treatment of benign conditions of the gastroesophageal junction (GEJ), including anti-reflux surgery, due to the growing popularity of the laparoscopic approach [1–3]. Despite the unquestioned superiority of the less invasive approach over the classical one in the management of gastroesophageal reflux disease (GERD) and hiatal

hernia, some of its flaws, inter alia recurrent herniation, have still not been eliminated. According to many authors, migration of the fundoplication band and recurrent hiatal hernia are a result of the lack of correct diagnosis and appropriate management of the so-called short esophagus [4]. Undoubtedly, unambiguous diagnostic criteria of the latter condition are problematic [5]. According to various authors, short esophagus is present in up to 60% of patients qualified for anti-reflux surgery [6]. Howev-

Address for correspondence

Marcin Migaczewski MD, PhD, Second Department of General Surgery, Jagiellonian University Medical College, 21 Kopernika St, 31-501 Krakow, Poland, phone: +48 12 424 82 00, e-mail: marcinmigaczewski@onet.pl

er, some other researchers question the presence of this condition [7].

Although some authors proposed criteria suggesting the presence of short esophagus already at the preoperative stage, according to most researchers, the definitive diagnosis of this condition can be established no earlier than intraoperatively [6].

In patients in whom the presence of short esophagus was unambiguously confirmed, Collis gastroplasty remains the procedure of choice.

Aim

The aim of this study was to analyze the prevalence of short esophagus in patients subjected to laparoscopic Nissen fundoplication due to GERD and hiatal hernia.

Material and methods

The study included 202 patients who were subjected to laparoscopic Nissen fundoplication at the 2nd Department of General Surgery, Jagiellonian University Medical College, between January 2004 and January 2014. A total of 172 patients were qualified for surgery due to GERD, and the remaining 30 due to presence of hiatal hernia other than sliding (type I). The latter group included 5 patients with type II (paraesophageal) hernia, 15 with type III (mixed) hernia, and 10 with “upside down stomach” (type IV) hernia. Surgical treatment was preceded by a meticulous preoperative examination. Each patient was subjected to gastroscopy, and mucosal biopsy specimens were obtained whenever Barrett’s esophagus was suspected. Moreover, esophageal manometry

and contrast esophageal radiography were performed in every individual, along with pH-metry or pH-impedance in ambiguous cases. Finally, computed tomography of the abdominal cavity and chest was conducted whenever intrathoracic protrusion of organs, other than the stomach, was suspected.

The fundoplication procedure was carried out by three operators with the patient placed in a supine, so-called Fowler’s (reverse Trendelenburg) position, with abducted lower limbs and the surgeon standing in between. Initially, a manual fan retractor inserted through a 10 mm trocar was used to retract the left hepatic lobe. In recent years, however, it was replaced by an automatic Nathanson retractor, mounted on an operating table and inserted into the abdominal cavity via the opening in the central epigastrium, following a 5 mm trocar.

The procedure commenced with dissection of the diaphragmatic crura. After initial mobilization of the esophagus, the level to which the area of the GEJ protruded into the mediastinum was determined. Intraoperative gastroscopy was performed in ambiguous cases, in order to locate the top of the gastric folds. Upon adhesiolysis, the esophagus was mobilized, with a part of the stomach protruding into the thorax, if necessary. Upon opening the omental sac, short gastric vessels were cut with a harmonic knife in order to fully mobilize the gastric fundus. Dissection of the esophagus with a dissector and a harmonic knife was continued up to a level that enabled its free downward retraction and reconstruction of at least a 2.5-cm abdominal segment (Photos 1 and 2). The second stage consisted of plasty of the hernial orifice. In most patients, diaphragmatic crura were

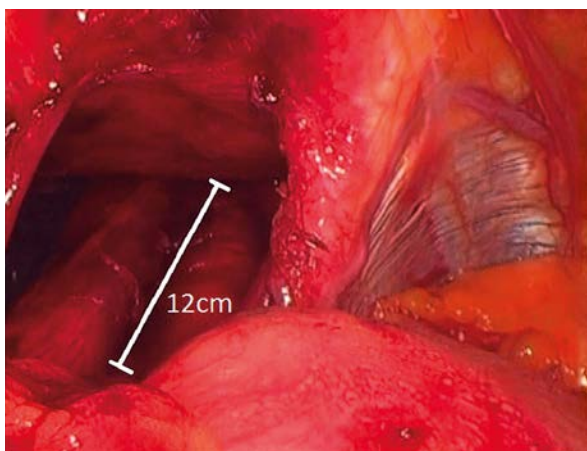


Photo 1. The extent of the esophagus dissection within the mediastinum

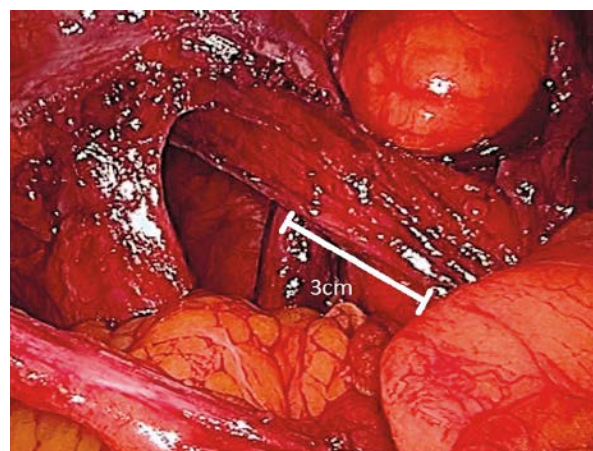


Photo 2. The length of the abdominal part of the esophagus after dissection within the mediastinum

connected with non-absorbable 2.0 polyfilament sutures. During the first period of using the laparoscopic technique, diaphragmatic crura of patients with large hiatal hernias were connected with a combination of single and Z-type sutures. In the last few years, however, only single sutures have been used in most patients. The last stage of the procedure included formation of the fundoplication band from a mobilized gastric fundus, which was wrapped around the newly formed abdominal segment of the esophagus. The band was fixed with 3–4 single sutures, with the first suture passing through the esophagus muscularis for the purpose of additional stabilization.

Outcomes of the treatment were determined with a quality of life survey developed exclusively for the purposes of this study.

Results

As many as 96% of the patients qualified for the surgical treatment showed supradiaphragmatic location of the high pressure zone. The average pressure at the level of the lower esophageal sphincter (LES) was 6.2 mm Hg (range: 0–26 mm Hg), and average length of the high pressure zone was 1.3 cm (range: 0–2.2 cm). A total of 188 (93%) patients showed intraoperative evidence of hiatal hernia and protrusion of the GEJ. The extent of GEJ protrusion ranged from 0 cm to 3 cm (mean: 2 cm). In 23 patients, the GEJ was not protruded above the esophageal hiatus. In another 50 individuals, however, the extent of protrusion was determined at 3 cm, thus satisfying the diagnostic criterion of a significantly shortened esophagus. The extent of dissection within the mediastinum was determined by the level of GEJ protrusion, and ranged from 5 cm to 12 cm (mean: 6 cm) (Photo 1). Upon complete mobilization of the esophagus within the mediastinum, no cases of significantly shortened esophagus, precluding downward retraction of at least a 2.5-cm segment below the diaphragmatic crura, were documented. Therefore, none of the patients required Collis gastroplasty.

All 202 patients were subjected to laparoscopic Nissen fundoplication. None of them required conversion to an open procedure. The surgery lasted between 35 min and 270 min (mean: 94 min). No cases of perioperative mortality were recorded. Pleural injury was the only intraoperative complication documented in our series. The right and left pleura

was injured in 7 (3.5%) and 6 (3%) patients, respectively. All the pleural injuries were closed with single sutures, with no need for conversion or drainage.

During a 1- to 112-month follow-up (mean: 63 months), recurrent hiatal hernia with migration of the fundoplication band into the mediastinum was documented in 5 out of 202 (2.5%) patients. Laparoscopic revision was performed in 2 of these patients with satisfactory outcomes. The remaining 3 subjects did not consent to reoperation, due to the asymptomatic character of the recurrence.

Discussion

Laparoscopic surgery has assumed the dominant position in the treatment of many benign conditions of the GEJ. Precise exposure of the esophageal hiatus region becomes possible both due to different positioning of the surgical team, as compared to a classical procedure, and due to the parameters of the laparoscopic video channel itself. Different angle of vision, obtained, inter alia, by the use of so-called oblique laparoscopes, completely changes the possibilities of visualizing the area of diaphragmatic crura connection, even under unfavorable anatomical conditions (e.g. in obese patients and/or in persons with low costal arches). Also, the possibility of stable retraction of the left hepatic lobe with retractors mounted on an operating table, e.g. the Nathanson hook, is important for an operator's comfort. The laparoscopic approach is invaluable during the mediastinal stage of dissection. Both excellent exposure and precise laparoscopic instruments enable safe dissection of paraesophageal tissues within a bloodless surgical field, which is of vital importance in the case of a markedly shortened esophagus. During initial attempts of laparoscopic fundoplication, the extent of dissection was limited to mobilization of the esophagus solely at the hiatal level. Currently, surgical authorities recommend extending the procedure to a markedly higher level. However, opinions on the extent of esophageal mobilization within the mediastinum are conflicting. According to Dallemagne, the esophagus should be mobilized up to 5–7 cm above the hiatus [8], and Swanstrom suggested continuing dissection to the level of the lower pulmonary veins [9]. High mobilization of the esophagus enables the reconstruction of a sufficiently long abdominal segment, being a vital component of the anti-reflux barrier. In our opinion, the level of esoph-

ageal mobilization should not be arbitrarily stated, but defined intraoperatively, depending on the transposition present in a given patient. High mobilization of the esophagus and tight closure of the diaphragmatic crura are postulated to prevent the complication that most commonly necessitates reoperation, i.e. migration of the fundoplication band into the mediastinum.

In our opinion, a degree of esophageal shortening is present in virtually all patients with hiatal herniation, both with type I hernia and with larger hiatal defects. Frequently, the mobilization and retraction of the esophagus to the abdominal cavity in patients with upside down stomach (type IV) hernia are easier than in individuals with a long history of GERD and many episodes of esophagitis. The difficulties reported in the latter cases are mostly associated with the presence of adhesions to mediastinal tissues, resulting from chronic inflammation of the esophageal wall.

The situation in which the esophagus is shortened to a degree that precludes formation of a sufficiently long abdominal segment without an additional elongation procedure is another issue. Such cases are referred to as the so-called true short esophagus. However, published data on the prevalence of this condition are inconclusive: while according to some authors this pathology is present in up to 60% of patients qualified for anti-reflux surgery, others have questioned the existence of true short esophagus [6, 7]. Although some researchers defined criteria pointing to the presence of short esophagus already at a preoperative stage, according to most authors, the definitive diagnosis can be established no earlier than intraoperatively [6]. Persistent reflux disease can be associated with enhanced fibrosis of paraesophageal tissues, resulting from chronic inflammation of the esophageal wall. This can lead to stabilization of the proximally protruded esophagus and development of true short esophagus. Another postulated etiological factor of this condition is the presence of large hiatal defects, leading to protrusion of the esophagus and, not infrequently, also nearly the entire stomach into the thorax. The presence of a large hernia can be suspected whenever no high pressure zones are documented on esophageal manometry and/or decreased peristalsis of the distant body of the stomach is observed at the hiatal level [6]. Endoscopic evidence of advanced inflammatory lesions or Barrett's metaplasia constitutes the least

reliable, but still proposed, indication of significant shortening of the esophagus [6]. However, in most authors' opinion, the definitive diagnosis of short esophagus can be established no earlier than intraoperatively. Currently, one postulated diagnostic criterion of short esophagus is protrusion of the GEJ 1.5 cm above the level of the esophageal hiatus, present despite complete mobilization of the esophagus within the mediastinum. The exact location of the GEJ can be determined accurately by means of intraoperative gastroscopy. Another, perhaps the most convincing but still poorly objective, determinant of the diagnosis is the impossibility of slightly (at least 2.5–3 cm) retracting the GEJ below the diaphragm, after complete mobilization of the esophagus [10]. Undoubtedly, the lack of an unambiguously defined level of esophageal mobilization within the posterior mediastinum constitutes a challenge, and thus the extent of dissection is determined mostly by the experience and skills of the operator. Our present findings suggest that, in most cases, the possibility of esophageal retraction below the hiatus is determined by proper surgical technique and appropriately high mobilization of the esophagus within the mediastinum. This statement is also supported by the small number of failures in the form of recurrent hiatal herniation documented in our series.

Increased risk of potential complications, proportional to the extent of manipulation within the thoracic tissues, may constitute a potential flaw of high esophageal mobilization. There are available data depicting intraoperative injuries to virtually all anatomical structures located at the vicinity of the esophageal hiatus: pleura, esophagus, aorta, thoracic duct, spleen, and stomach [6, 11, 12]. However, we did not document any complications requiring immediate reoperation. Pleural injuries, not leading to pneumothorax or requiring drainage placement, predominated among intraoperative complications documented in our series.

An appropriate procedure of esophageal elongation, most commonly Collis gastroplasty, is required in unique cases. Although Collis gastroplasty undoubtedly constitutes an effective technique of esophageal elongation, its serious disadvantages should also be emphasized. The most significant flaw is persistent impairment of the anti-reflux effect, resulting mostly from gastric acid secretion and affected self-clearance of a newly formed esophageal segment [13]. Also the risk of progressive

Barrett's metaplasia was previously reported. Thus, some authors postulate limiting the use of this procedure to patients with recurrent herniation [13]. However, according to other researchers, the laparoscopic Roux-en-Y gastric bypass (LRYGB), typically performed in bariatric surgical patients with signs of reflux, should be conducted in the case of recurrent herniation [14]. Further research seems to be required to resolve these discrepancies.

Conclusions

The presence of "true" short esophagus is a sporadic finding among patients qualified for anti-reflux surgery. Mediastinal dissection of the esophagus and its mobilization at an appropriate, individually defined level seems a sufficient treatment in the vast majority of these patients.

Acknowledgments

The publication of this article was supported by Faculty of Medicine, Jagiellonian University Medical College, Leading National Research Centre (KNOW) 2012–2017.

Conflict of interest

The authors declare no conflict of interest.

References

1. Wróblewski T, Skalski M, Ziarkiewicz-Wróblewska B, et al. New antireflux surgical technique in GERD treatment. *Videosurgery Miniinv* 2007; 2: 139-44.
2. Wróblewski T, Skalski M, Ziarkiewicz-Wróblewska B, et al. Progress in surgical treatment of reflux disease. *Videosurgery Miniinv* 2006; 1: 121-4.
3. Migaczewski M, Grzesiak-Kuik A, Pędziwiatr M, Budzyński A. Laparoscopic treatment of type III and IV hiatal hernia – authors' experience. *Videosurgery Miniinv* 2014; 9: 157-63.
4. Low DE, Unger T. Open repair of paraesophageal hernia: reassessment of subjective and objective outcomes. *Ann Thorac Surg* 2005; 80: 287-94.
5. Luketich JD, Grondin SC, Pearson FG. Minimally invasive approaches to acquired shortening of the esophagus: laparoscopic Collis-Nissen gastroplasty. *Semin Thorac Cardiovasc Surg* 2000; 12: 173-8.
6. Horvath KD, Swanstrom LL, Jobe BA. The short esophagus: pathophysiology, incidence, presentation, and treatment in the era of laparoscopic antireflux surgery. *Ann Surg* 2000; 232: 630-40.
7. Lugaesi M, Mattioli S, Aramini B, et al. The frequency of true short oesophagus in type II-IV hiatal hernia. *Eur J Cardiothorac Surg* 2013; 43: e30-6.
8. Dallemagne B, Weerts J, Markiewicz S, et al. Clinical results of laparoscopic fundoplication at ten years after surgery. *Surg Endosc* 2006; 20: 159-65.
9. Swanstrom LL. Management of patients with gastroesophageal reflux disease and esophageal or gastric dysmotility. *J Gastrointest Surg* 2001; 5: 448-50.
10. Peters JH, Heimbucher J, Kauer WK, et al. Clinical and physiologic comparison of laparoscopic and open Nissen fundoplication. *J Am Coll Surg* 1995; 180: 385-93.
11. Hwang PF, Ospina KA, Lee EH, Rehring SR. Unconventional management of chyloascites after laparoscopic Nissen fundoplication. *JLS* 2012; 16: 301-5.
12. Yano F, Omura N, Tsuboi K, et al. Thoracic aortic injury during laparoscopic fundoplication for reflux esophagitis. *Int J Surg* 2008; 6: 490-2.
13. Jobe BA, Horvath KD, Swanstrom LL. Postoperative function following laparoscopic collis gastroplasty for shortened esophagus. *Arch Surg* 1998; 133: 867-74.
14. Stefanidis D, Navarro F, Augenstein VA, et al. Laparoscopic fundoplication takedown with conversion to Roux-en-Y gastric bypass leads to excellent reflux control and quality of life after fundoplication failure. *Surg Endosc* 2012; 26: 3521-7.

Received: 30.09.2014, **accepted:** 18.11.2014.