

Learning process by video cases – our first laparoscopic conversion of VBG to CRnYGB including technical problems and complication management

Wojciech K. Karcz¹, Cheng Zhou², Goran Marjanovic¹, Birte Kulemann¹, Carolin Kayser¹, Simon Küsters¹

¹Department of General and Visceral Surgery, University of Freiburg, Germany

²Department of Miniinvasive Surgery, No. 1 Hospital of Wuhan, China

Videosurgery and other miniinvasive techniques 2009; 4 (4): 158-163

Abstract

The number of bariatric surgical procedures performed each year is growing worldwide. The techniques and our knowledge have changed and new indications for surgical metabolic procedures have appeared. Patients with type II diabetes, who might also be treated with surgical therapies in the future, exemplify that the number of patients in need of a metabolic procedure might grow enormously. We have learned already that not all of our procedures were well chosen and some do not fit the patients' needs and behaviour. Some patients need to be re-operated to improve the outcome. Each department has its own re-operation rate and it is known to be as high as 20%. At our metabolic centre at Freiburg University, we see patients after bariatric surgery from various other departments. Sometimes we consider a re-operation when the patient reports complaints or a bad outcome. The development and improvement of diagnostic procedures and the establishment of guidelines for bariatric surgery is one of our main courses. The problem of indicating a re-operation and agreement with the patient about the medical approach are the most important matters. We would like to present the technical procedure and discuss problems and possible improvements of the following revisionary intervention: transformation of a vertical banded gastroplasty into a laparoscopic conventional Roux-en-Y gastric bypass. We will concentrate on the procedure technique and not discuss the indications for the gastric bypass procedure in general.

Key words: metabolic surgery, bariatric surgery, redo surgery, vertical banded gastroplasty, gastric bypass, 3D MSCT gastric volumetry.

Introduction

Bariatric re-operations are technically demanding. Although mortality rates are as low as 0.02-1%, the re-operation rate, especially after vertical banded gastroplasty (VBG), is as high as 56% in some series [1-3]. The real re-operation rate however is not known as there is no official register and most published series are relatively small compared to the enormous number of primary surgical procedures. The most

common indication for a re-operation is insufficient weight loss or weight regain [4-6]. Nevertheless, some patients present with persistent or recurrent abdominal complaints. There are also patients who are suffering from other problems caused by the implant (in the case of VBG or gastric banding) or from too-effective operating methods resulting in a too-strong restriction or too-strong malabsorption, leading to malnutrition. All these complaints might affect the patient's quality of life and thus be

Address for correspondence:

Wojciech K. Karcz, MD, Department of General and Visceral Surgery, University of Freiburg, Hugstetter Strasse 55, DE-79106 Freiburg, Germany, phone +49 761 270 2806, fax +49 761 270 2804, e-mail: konrad.karcz@uniklinik-freiburg.de

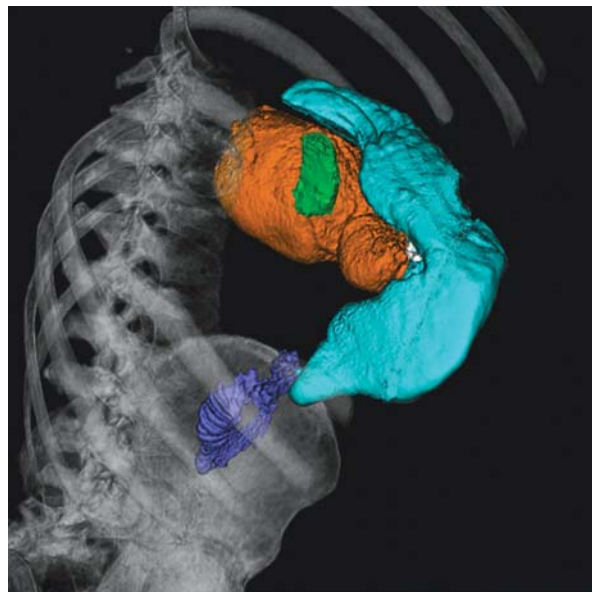


Figure 1. 3D-MSCT volume rendering image after VBG. Orange: dilated pouch, cyan: stomach, green: oesophagus, blue: duodenum

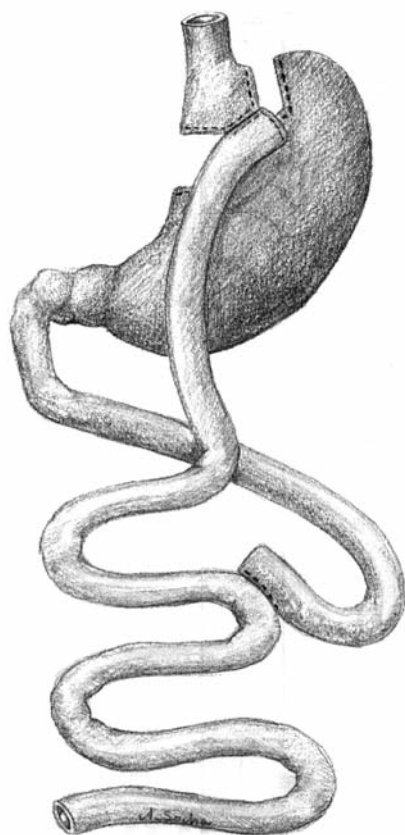


Figure 3. Schedule of the conventional Roux-en-Y gastric bypass

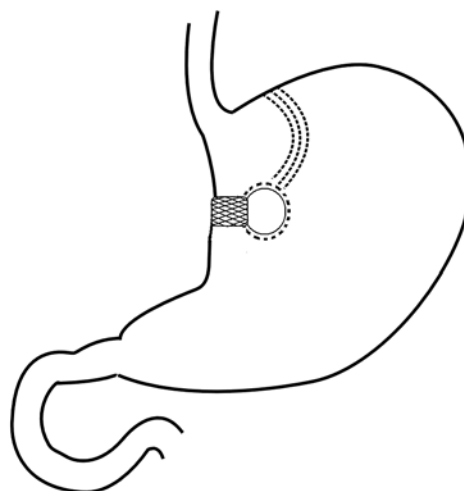


Figure 2. Schedule of the VBG with a dilated gastric pouch

reflected in a decrease of QoL scores such as the BAROS (Bariatric Analysis And Reporting Outcomes System) [7, 8].

Our first laparoscopic revision after VBG was performed in a 36-year-old man operated on 18 years before. He was examined in our outpatient department because of regaining weight. He gained about 2 kg per month for over 4 months. We performed multi-slice computed tomography (MSCT) of the abdomen including stomach volumetry and 3-dimensional rendering. It was shown that the vertical pouch was dilated with a persistent vertical stapler line (Figures 1, 2). The patient told us that he started to eat sweets as a result of a stressful situation half a year ago. Because of a BMI of 32, ongoing regain of weight, the eating behaviour and a low BAROS, we decide to laparoscopically convert the VBG into a proximal conventional RnYGB.

Surgical method (Movie) and practical comments

The laparoscopic conventional gastric bypass (LCRYGB) technique is used as a standard procedure (Figure 3).

All advanced VBG redo procedures prior to this one were done via laparotomy in our department. The procedure was recorded to allow a postoperative evaluation and to develop a modern learning process. One year later we introduced the recording system for all laparoscopic procedures in our department. In the

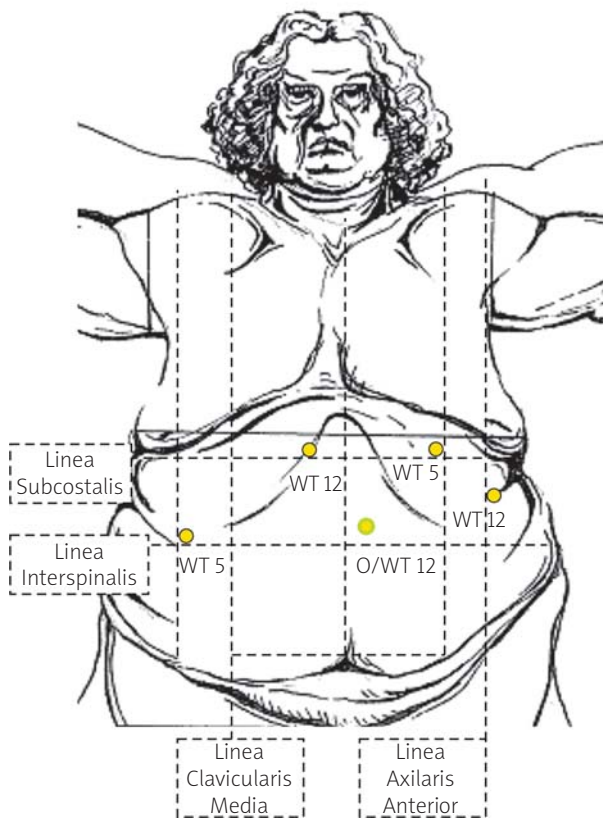


Figure 4. Trocar placement for BRnyGB. RT 5: retractor trocar 5 mm, WT 12: working trocar 12 mm, WT 5: working trocar 5 mm, O12: optical trocar 12 mm

following text we describe how the procedure was planned and performed and you can see the procedure and comments in the movie presentation. The whole operation time was 3 h 23 min. All complications and difficulties in this case are presented in the video (Movie).

In the majority of our patients, we perform the operation as a two-surgeon procedure. With the patient in the lithotomic position, and the operating table in a 30 to 40 degree reverse Trendelenburg tilt, the surgeon stands between the patient's legs with one assistant on the left side of the patient. The capnoperitoneum is insufflated with a 12 mm separator trocar. The residual abdominal pressure is much higher in obese patients (8-10 mmHg) than in patients with normal weight (2-5 mmHg). When a pressure of 14 mmHg is reached, we start exploration of the region of interest using a 30-degree optic (HD Endo-Eye™, EndoALPHA™, Olympus, Hamburg, Germany). The

space in the left or right upper quadrant should be available for additional trocars, in a position similar to primary LRYGBP. In this case, omental adhesions to the anterior abdominal wall were to be expected, as the primary procedure was performed via laparotomy. After placement of two work trocars in the upper abdomen, all adhesions were removed with the harmonic scalpel (Ethicon, Norderstedt) (Movie).

It is possible to use monopolar or bipolar instruments (J. Himpens or D. Krawczykowski), as well as the LigaSure™ (5 mm V, or Advanced) (J.S. Azagra, R. van Velthoven, W.K. Karcz). Each of these techniques is safe when used routinely by the surgeon.

After placement of two more working trocars located as shown in Figure 4, we started preparation of the lesser gastric curve. Adhesions between the liver and the gaster, mainly the area of the banding and the vertical stapler line, were seen. In this case, it was not hard to separate them. For that reason we decided to prepare the lesser gastric curve and to reach the bursa omentalis (Movie).

Nowadays in our department the dissection is started in the region of the Hiss angle with the LigaSure Advanced™ (Covidien, Dublin; Valley Lab, Boulder, Colorado) just above the first short gastric artery to present the left crus of the diaphragm.

We wanted to stay close to the stomach wall above the Dacron mesh of the VBG. Here a perforation of the thin gastric pouch wall was made almost immediately and the 32F gastric tube, which was placed in order to mark the stomach pouch, could be clearly seen in the perforation. We thus changed our plan and decided to make the stomach pouch smaller. We went under the stomach from the right side, crossed under the pouch and separated the upper part of the VBG (Figure 5) (Movie).

We first planned to leave the banding and to create only a new small gastric pouch and leave the remnant stomach in place with the remnant part of the VBG pouch being drained in the stomach.

After the bursa omentalis was reached, the anatomical situation was clear. The bursa omentalis itself was not changed and we did not have significant bleeding.

When we later analyzed the film, we noticed that our problems could be reduced by modifying the technique, which required a small extension of the procedure: After separation of the adhesions, the large curvature of the stomach could be dissected and the bursa omentalis would be opened like in a sleeve

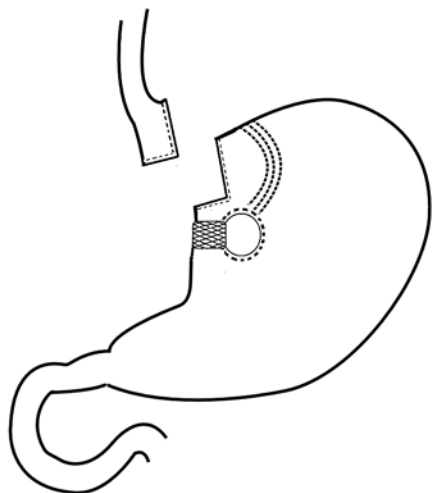


Figure 5. Schedule after stomach pouch reduction. The rest of the VBG pouch is drained into the remnant stomach

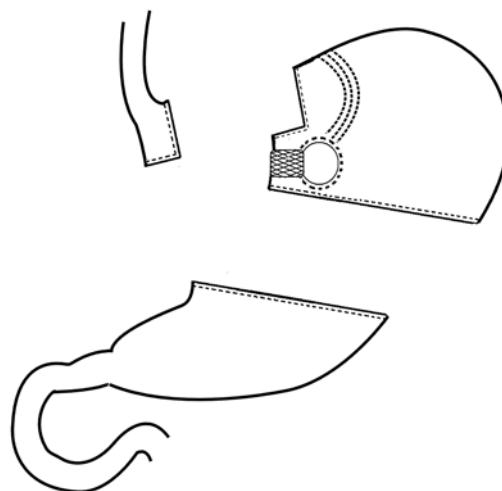


Figure 6. Schedule after resection of the residual VBG pouch and the fundus as an logical operative alternative to Figure 4

gastrectomy. The whole fundus should be separated from the omentum majus including the short gastric arteries. Then the adhesions in the bursa omentalis should be much easier to identify and to separate. Also the banding should be easier to identify and the vertical TA90B stapler line should be more clearly visible. Then a horizontal dissection of the stomach should be performed, using the linear Endo-GIA (Covidien, Dublin) with 60 mm staplers and blue cartridge. This dissection should be placed distal to the banding. The lesser stomach curvature and left diaphragm crus preparation is then easier to perform. The formation of the new stomach pouch with resection of the dilated part of the old VBG pouch and the fundus is then easier to perform technically (Figure 6). Others had similar problems with this type of re-operation. At the First Atlantic meeting of Advanced Laparoscopy, K. Higa presented cases where he used the same technique. Three months later we performed the next conversion of a VBG into a LCRnYGB exactly as described above. The operation time was reduced to 2 h and 7 min. Apart from multiple adhesions, we had no technical problems.

Then we began the dissection in the region of the small curvature of the stomach, 5-6 cm below the cardia and towards the left crus, in order to create a new vertical gastric pouch based on a lesser curvature. Achieving enough space, three linear Endo-GIA 60 mm staplers with blue cartridges are

used to completely transect the stomach after the removal of the 32F calibration tube. The distal pouch with the iatrogenic perforation was also resected. This technique enables adequate direct visualization and thus objective evaluation of the anterior and posterior aspects of the pouch and the distal stomach for leaks or bleeding, as well as a visual estimation of the pouch size. The distal part of the old residual VBG pouch with the banding was not resected (Movie).

An alimentary limb according to Roux is created by dividing the jejunum 50 cm below the ligament of Treitz with a 45-mm Endo-GIA stapler with white vascular cartridge, then transposition of the jejunal alimentary limb in an antecolic and antegastric position is performed. In patients with an extremely thick greater omentum, an additional division of the omentum is performed with a LigaSure dissector. As the next step, the gastroenteroanastomosis (GEA) is created with a 30-mm Endo-GIA stapler and defect closure with running absorbable suture and second-layer closure are performed (Figures 7, 8).

There are three main methods for performing the GE anastomosis. One was used in our re-operation. A hand running suture end to side, 2 cm long, with two-layer closure of 2-0/3-0 Vicryl (L. Lemmens, K. Higa) is also very popular. The most common method is to perform the end-to-side anastomosis with a CEEA 25 mm Stapler (Covidien, Dublin) (B. Dillemans, W.K. Karcz).

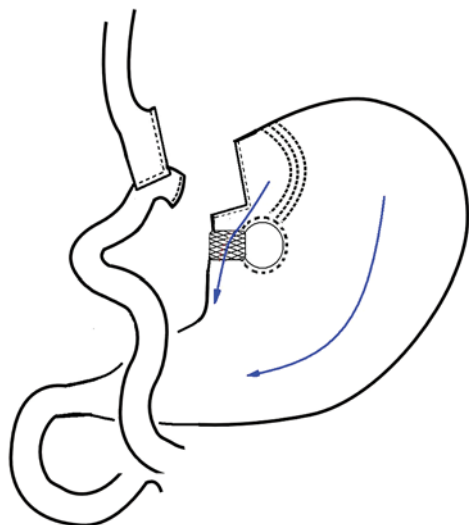


Figure 7. Schedule of our redo procedure: transformation of VGB into CRnYGB

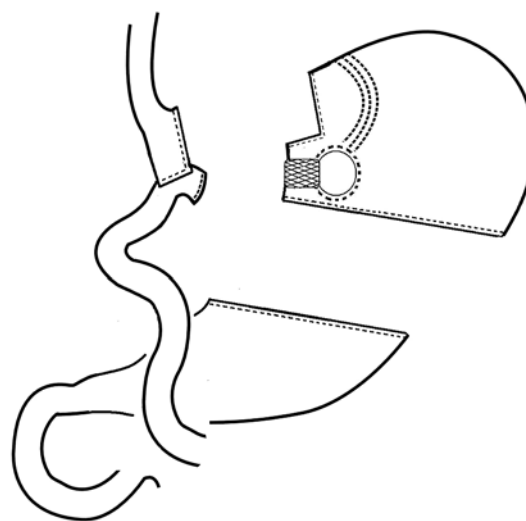


Figure 8. Schedule of the transformation of VGB into CRnYGB after technical changes

A 32 F tube is used to calibrate the stomach opening. Afterwards, the integrity of the anastomosis is tested for leakage by using methylene blue insufflation through the gastric tube and placement of the bowel clamp on the intestinal limb distal to the anastomosis. A side-to-side stapled jejunojejunostomy (EEA) is created typically 150 cm below the GEA with one 45-mm Endo-GIA stapler, and the opening for the stapler is closed with running absorbable suture (Movie).

The EE anastomosis could also be performed with no hand sewing in the M or W technique using three Endo-GIA staplers, two for the anastomosis and one for closure of the intestinal defect (M. Gagner, R. Weiner). The second option is to use a 60 mm cartridge to perform the anastomosis and another stapler to close the defect (B. Dillemans).

Prevention of internal hernias is achieved by closing the gap between the alimentary jejunal limb and transverse mesocolon with interrupted nonabsorbable sutures. The area of the GEA is drained with a Blake drain, and the operation is finished without closure of any abdominal fascial openings and an absorbable skin suture.

Discussion

Revisionary surgery after VGB is known to be mostly performed in an open fashion. As ruptures of

the stapler line were common, the typical revisionary procedure was the restapling of the vertical suture line or the complete separation of the pouch and remnant stomach with a GIA stapler [2]. Fobi *et al.* used the gastric bypass as a revisionary procedure. He reformed the vertical gastric pouch, left the banding in place and performed the bypass. This led to the development of the primary banded Roux-en-Y gastric bypass procedure [9]. It is also possible to perform a sleeve gastrectomy with resection of the banding [10]. Weiner *et al.* proposed performing the Scopinaro procedure after VGB: The distal stomach with the banding is resected, the vertical stomach pouch is connected to the alimentary limb and an intestinal reconstruction with formation of a 50 cm common channel is performed. In our opinion, all of these techniques can be used as revisions after VGB except for the restoration of the VGB [2, 11]. It is reported that the re-VGB shows even higher revision rates than the primary VGB [2]. The procedure should be individually chosen and discussed in interdisciplinary teams. The BAROS should be evaluated in all patients. Contraindications should be considered prior to all redo procedures. All of our patients underwent a psychological and endocrinological examination and each patient underwent thorough medical examination including 3D MSCT stomach volumetry [12]. Himpens' procedure schedule can be used as an orientation to the

surgical options which exist [13]. To improve and shorten the learning curve, we introduced the monthly Videosurgery Conference, where intra-operative complications and rare cases are discussed. To improve practical skills, all our residents have to attend the videosurgery course (40 h in the Videosurgical Lab) and five different Pig Labs during residency training. The development of our School of Videosurgery (SVS) allows us to introduce technical innovations and shorten the learning curve for new procedures, not only for fellows but also for residents in standard videosurgical cases.

References

1. Maggard MA, Shugarman LR, Suttorp M, et al. Meta-analysis: surgical treatment of obesity. *Ann Intern Med* 2005; 142: 547-59.
2. van Gemert WG, van Wersch MM, Greve JW, Soeters PB. Revisional surgery after failed vertical banded gastroplasty: restoration of vertical banded gastroplasty or conversion to gastric bypass. *Obes Surg* 1998; 8: 21-8.
3. Marsk R, Jonas E, Gartzios H, et al. High revision rates after laparoscopic vertical banded gastroplasty. *Surg Obes Relat Dis* 2009; 5: 94-8.
4. Gawdat K. Bariatric re-operations: are they preventable? *Obes Surg* 2000; 10: 525-9.
5. Gagner M, Gentileschi P, de Csepel J, et al. Laparoscopic reoperative bariatric surgery: experience from 27 consecutive patients. *Obes Surg* 2002; 12: 254-60.
6. Calmes JM, Giusti V, Suter M. Reoperative laparoscopic Roux-en-Y gastric bypass: an experience with 49 cases. *Obes Surg* 2005; 15: 316-22.
7. Oria HE, Moorehead MK. Bariatric analysis and reporting outcome system (BAROS). *Obes Surg* 1998; 8: 487-99.
8. Oria HE, Moorehead MK. Updated Bariatric Analysis and Reporting Outcome System (BAROS). *Surg Obes Relat Dis* 2009; 5: 60-6.
9. Fobi MA. Placement of the GaBP ring system in the banded gastric bypass operation. *Obes Surg* 2005; 15: 1196-201.
10. Elazary R, Hazzan D, Appelbaum L, et al. Feasibility of sleeve gastrectomy as a revision operation for failed silastic ring vertical gastroplasty. *Obes Surg* 2009; 19: 645-9.
11. Schouten R, van Dielen FM, van Gemert WG, Greve JW. Conversion of vertical banded gastroplasty to Roux-en-Y gastric bypass results in restoration of the positive effect on weight loss and co-morbidities: evaluation of 101 patients. *Obes Surg* 2007; 17: 622-30.
12. Karcz WK, Kuesters S, Marjanovic G, et al. 3D-MSCT Gastric pouch volumetry in bariatric surgery-preliminary clinical results. *Obes Surg* 2009; 19: 508-16.
13. Karcz WK, Baumann T, Marjanovic G, Kuesters S. To have or not to have the ring: early and late surgical complications after banded Roux-en-Y gastric bypass. *Videosurgery and other miniinvasive techniques* 2008; 2: 53-65.