

Technical problems in laparoscopic sleeve gastrectomy

Tomasz Szewczyk, Przemysław Janczak, Michał Duszewski, Bogdan Modzelewski

Department of Gastroenterological, Oncological and General Surgery, Medical University of Lodz

Videosurgery and other miniinvasive techniques 2009; 4 (3): 95-101

Abstract

Introduction: Laparoscopic sleeve gastrectomy has been used as an isolated bariatric operation since a few years ago. In October 2007 a consensus was established, acknowledging sleeve gastrectomy as a bariatric procedure.

Aim: To analyze technical difficulties occurring during the procedure, as well as intraoperative and early postoperative complications.

Material and methods: Between October 2006 and June 2009 in the Department of Surgery 331 such procedures were done. A standardized operating technique was used. Mean BMI of patients was 46.14 kg/m². Mean age was 49.2 years. Eighty-four men and 247 women were operated on. During the procedure, a 34 Fr tube was inserted into the stomach to ensure adequate diameter and volume reduction with 60 mm long green linear mechanical staplers. The staple line was enforced with additional continuous suture.

Results: In 1.2% of patients bleeding from the port incision that required additional action was seen, while 3.93% had bleeding from the staple line (requiring clipping in 3.32% and stitch in 0.6%). There were no splenic injuries. No conversions to open operation occurred. Patients were mobilized in the evening of the day of surgery (mean time from the operation 7 h). Three patients (0.9%) had suture failure in the cardia area diagnosed on the first day after operation. One of them was treated laparoscopically, the other two by laparotomy. There were two deaths: in one patient of sepsis after suture leakage and in the other of cardiac infarction on the 4th day after the operation.

Conclusions: Laparoscopic sleeve gastrectomy can be considered a safe method, and can be recommended as a method of surgical treatment for obesity.

Key words: laparoscopic sleeve gastrectomy, technical problems, complications.

Introduction

Laparoscopic sleeve gastrectomy (LSG) initially was used as a stage of more complicated bariatric procedures: the first step of duodenal switch (DS) [1-4]. Laparoscopic sleeve gastrectomy has been performed as a solitary bariatric procedure for a few years [5]. It is classified as a restrictive procedure, yet influence on hormonal homeostasis of the body is discussed more and more often. The latter effect seems to result from elimination of the source of ghrelin, P/D1 cells in the gastric fundus [6-8]. Weight reduction results not only from simple

limitation of the amount of ingested food, but also from accelerated gastric transit time and from other, not yet quite identified factors [9]. In spite of its extensiveness (resection of 80-90% of the stomach), the procedure does not seem to present a technical challenge to an experienced laparoscopic surgeon. Effects of weight loss after LSG are satisfactory. In case of failure, when weight reduction is too small after sleeve gastrectomy, a second step procedure, i.e. Roux-en-Y gastric bypass or DS, is always feasible.

Address for correspondence:

Tomasz Szewczyk MD, PhD, 50 Banachiewicza St, 91-162 Lodz, phone 501 040 081, fax +48 42 679 10 91, e-mail: tomasz.szewczyk@umed.lodz.pl

Aim

The aim of the study is to assess sleeve gastrectomy and analyse intraoperative and early post-op (occurring until day 5) complications.

Material and methods

Between October 2006 and June 2009, three hundred and thirty-one laparoscopic sleeve gastrectomies were performed in the Department of Surgery. There were 247 women and 84 men with a mean age of 49.2 (18-65) years and with average body mass index (BMI) of 46.14 (33.83-70.4 kg/m²) in this group (Table I).

Prior to admission, patients had chest X-ray, EKG, gastroscopy and thyroid hormones taken and were assessed by a psychologist. After admission, on the pre-operative day, anti-coagulation prophylaxis (standard dose low molecular weight heparin) and anti-secretory drugs were administered. Prior to the procedure, every patient had a nasogastric tube put in. Surgery was performed under general anaesthesia

by a team of a surgeon, two assistants and a scrub nurse. Positioning of the surgical team is shown in Figure 1. Pneumoperitoneum was accomplished with an incision in the left hypo-chondriac area lateral to the midclavicular line, where a Veress needle was placed. Standard pressure of 15 mm Hg was maintained, increased to 20 mm Hg in some cases with difficult access, especially at the gastric fundus and angle of His. Trocars were distributed 15 cm from the xiphisternum; their localization is shown in Figure 2. After pneumo-peritoneum was created, a camera port was placed blindly a little to the right from the midline. All remaining ports were placed with visual control. Ten millimetre trocar for laparoscope (30° optics), 10 mm for liver retractor, 5 mm for assistant's grasper, and 12 or 15 mm working tool ports (diameter depended mostly on the staplers that were used) were applied. Green magazines (with 4.8 or 4.1 mm staple length – depending on the manufacturer), golden (3.8 mm) and blue ones (3.5 mm) 60 mm long were utilized. Tissues were dissected with Ligasure or a harmonic scalpel.

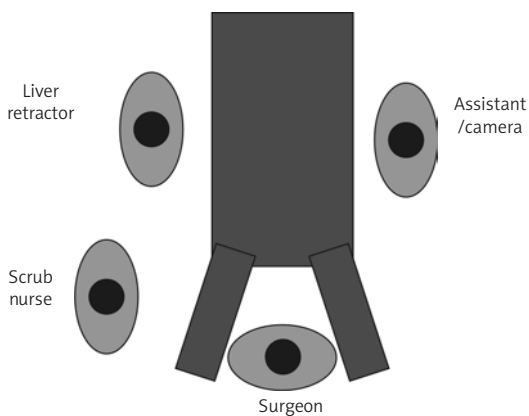


Figure 1. Positioning of the operative team

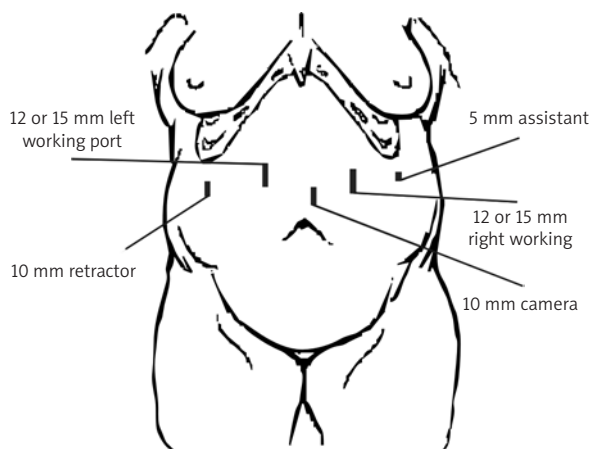


Figure 2. Trocar positioning

Table I. Demographic data

Parameter	Men	Women	Total
Number	84 (25.38%)	247 (74.62%)	331
Age [years]	41.4 (20-62) (SD 10.91)	38.4 (18-65) (SD 10.92)	49.2 (18-65) (SD 10.9)
BMI [kg/m ²]	49.47 (37.24-70.4) (SD 8.49)	45.07 (33.83-65.74) (SD 6.96)	46.14 (33.83-70.4) (SD 7.57)
Body weight [kg]	155.62 (112-240) (SD 27.56)	125.83 (90-190) (SD 19.96)	133.05 (90-240) (SD 25.42)

After pneumoperitoneum was achieved and trocars were placed, the patient was laid in an anti-Trendelenburg position at 30-40° angle with the floor. Inspection of the abdominal cavity and release of adhesions (as needed) were done. The liver was elevated with the retractor. Preparation was begun at the distal third of the stomach from the greater curvature. The omental bursa was opened and preparation was continued under visual control towards the angle of His, cutting adipose tissue and vessels running from the gastric wall towards the gastro-epiploic vessels arch. Particular care was taken when short gastric vessels were cut from the spleen. The left diaphragmatic crus was visualized each time. Tissues were then dissected towards the duodenum, finishing 5 cm from the pylorus. Adhesions between the posterior gastric wall and the pancreas were freed. After the greater curvature was liberated, the anaesthesiologist removed the nasogastric tube and introduced a 34 French tube via the oral cavity. The tube was passed through the pylorus with graspers and visual control. This tube was used for calibration of the gastric remnant with linear staplers, excising the major part of the stomach with greater curvature, moving from the antrum towards the cardia. When significant bleeding from the section line occurred, a clip or haemostatic suture was applied. Running manual suture (Biosyn 0) invaginated the mechanical staple line. Suturing began from the cardia and ended at the prepyloric area. Haemostasis was controlled and water-tightness checked with methylene blue given to the gastric tube by the anaesthesiologist. Peritoneal drainage was then placed in proximity to the cardia through the 5-mm trocar site. The excised part of the stomach was removed through the site of the rightmost working tool port. Skin incisions were closed with interrupted sutures.

The patient remained in the ICU for one day, and was administered 3000 ml of *i.v.* fluids, analgesics and antibiotic prophylaxis. Mobilization was begun on the operative day evening. Peritoneal drainage was removed on day 4. Oral fluids were started on the 5th day. Mean total hospital stay was 6 days. Demographic data, duration of the procedure and number of stapler loads used were statistically analyzed with standard descriptive methods and correlation coefficient when appropriate.

Results

Additional incision and trocar were necessary in 3 patients: in 2 cases it was a 5 mm port for a grasper to retract adipose tissue from the splenic region. The port was placed above one of the existing ports. In one patient, an additional 15 mm working port was introduced (rightmost from the operator's point of view) above the existing one.

Average operation time was 75 min (30-170 min, SD = 22.17). A mean of 5.47 stapler magazines were used (4-9, SD = 0.82). Correlation coefficient of duration of the procedure and patient's BMI was $r = -0.0856$ (the relation is shown in Figure 3) and of BMI and the number of staplers used $r = 0.23$ and was statistically significant at $p < 0.05$ (shown in Figure 4). No conversion was necessary, nor was any lesion of the spleen seen. No deaths occurred during surgery. When the stomach was sectioned,

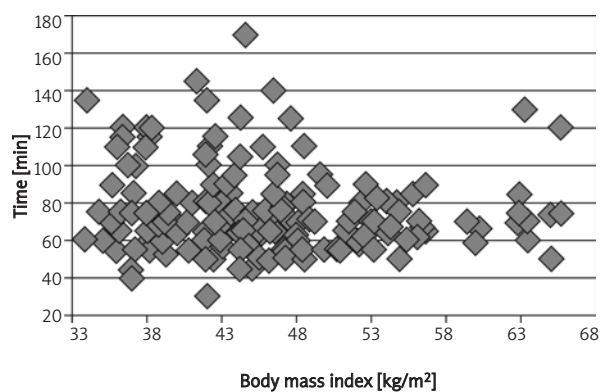


Figure 3. Correlation of operation time and patient's BMI

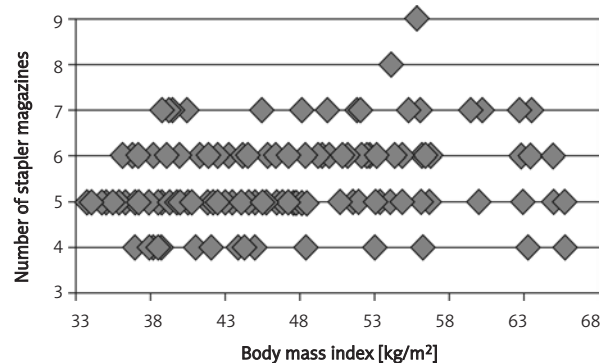


Figure 4. Correlation of the number of stapler magazines used and patient's BMI

Table II. Complications

	No.	Percent	Means of treatment
Bleeding from gastric section line	13	3.93	11 patients (3.32%) – clip placement 2 patients (0.6%) – haemostatic suture
Rupture of the liver edge (from the retractor)	3	0.9	Did not require any treatment
Severe bleeding from trocar site	4	1.2	Wound revision, haemostatic suture
Leak from gastric suture (diagnosed within 24 h)	3	0.9	1 patient – laparoscopy 2 patients – laparotomy
Abdominal wall haematoma with anaemization and jaundice	1	0.3	Antibiotic
Total	24	7.25	
Death	2	0.6	1 patient – sepsis and multi-organ failure from leakage from suture line 1 patient – extensive cardiac infarction

arterial bleeding that required additional action was seen in 13 patients (3.93%). Bleeding was dealt with using a metal clip in 11 cases (3.32%) and with haemostatic suture in the remaining 2 (0.6%). Minor (1-2 cm) rupture of the liver margin from the liver retractor was seen in 3 patients (0.9%) but required no treatment. No leak was observed during intra-operative control of water tightness. Mean blood loss was 35 ml (5-180 ml). Severe bleeding from the trocar site after port removal was seen in 4 patients (1.2%). In two patients (0.6%) it occurred from the right 15 mm working port, in one (0.3%) it was from the left working trocar, and in one from the 10 mm liver retractor port. In each of these cases wound revision was necessary with additional suture.

One hundred and ninety-two patients (58%) were mobilized within 12 h from surgery, and 327 patients (98.78%) were able to stand up without assistance within 24 h. Peristaltic movements were observed after 24 h in 314 patients (94.86%), assessed as active in 115 patients (34.74%) and slow in 199 (60.12%). In all remaining patients movements could be auscultated within 3 days. Two hundred and thirty-five patients (70.99%) had laxation within 4 days from surgery.

Leak from the suture line was confirmed with X-ray after oral water-soluble contrast administration in 3 patients (1.2%) on the first post-op day. In all patients the leakage was located in proximity to the gastroesophageal junction, 5 mm from the beginning of the suture line, and was 1-2 mm wide. All patients underwent emergency re-operation, one laparoscopic and the remaining two laparotomy.

A 30% decrease in haematological parameters was observed in one patient on the 2nd post-op day. In parallel, she had an increase in bilirubinaemia to 5 mg/dl. Abdominal ultrasound showed abdominal wall haematoma 250 × 189 × 100 mm wide at the rightmost working trocar site, which was treated with ice compress and antibiotic therapy.

All complications are shown in Table II.

Two patients (0.6%) expired in the early post-operative period. Leakage from the suture line treated with open re-intervention with additional suture, peritoneal lavage and drainage was the cause of decease in one patient. Death occurred on the 5th day after primary surgery from sepsis and multi-organ failure. Another patient died on the 4th day from massive cardiac infarction.

Discussion

Laparoscopic sleeve gastrectomy (LSG) in the beginning was just a step of a more sophisticated bariatric procedure – DS. Since 2002, it has been performed as a solitary procedure, although international consensus was achieved no sooner than 2007 [5]. Any patient with morbid obesity can undergo this operation and co-morbidities (diabetes, arterial hypertension, metabolic syndrome) are not a contraindication for such treatment. For patient qualification and work-up for LSG, similar criteria as for other bariatric procedures apply.

The patient and OR team position shown in Figure 4 allows for two-handed manipulation and is implemented by the majority of surgeons who perform this procedure. The patient is put in the anti-

Trendelenburg position only after pneumoperitoneum has been forged and some authors say only the first (optical) port is introduced in the supine position [9-14].

Number, size and location of trocars are variable and depend on the surgeon's preferences. Placement of the liver retractor is usually the most variable and results from the type of the appliance and adopted surgical technique. When technical problems occur, additional ports should be introduced to allow safe preparation, particularly in 'risky' regions, for instance when dissecting short gastric vessels or visualization of the left crus of the diaphragm [9-19].

After the learning curve has been passed, operation time is maintained within 60-80 min and usually is not dependent on the patient's BMI or on the number of staple loads shot, i.e. size of the stomach. Factors affecting duration of surgery are technical conditions throughout preparation of the greater curvature, especially visibility and accessibility of the angle of His region and short gastric vessels as well as the area of the left crus of the diaphragm, which should always be seen. These mainly depend on body fat distribution – visceral adiposity [10, 11, 14, 17, 18, 20].

There are notions in the literature on utilization of various size tubes for calibration of the internal diameter of a newly formed sleeve. Today this procedure is never done with placement of the suture line 15 mm away from the lesser curvature [15], without tube calibration, yet tubes number 60, 52, 48, 44 Fr are still applied. No. 34 or 32 Fr tube is used most often, as such diameter of the remnant stomach was proved to result in the best body weight reduction [3, 9, 10, 12-18, 20-26].

There is no consensus on which brand of staplers ought to be moved. Most popular appliances by renowned companies have similar groups of opponents and supporters. Still, they differ only in minor technical details and the final result is identical and handling by a surgeon is very similar. In our material, we did not notice any difference while using different brands of staplers.

Although the idea of the procedure is identical, technical details differ from surgeon to surgeon. Some authors say they start preparation 5-6 cm from the pylorus and progress towards the angle of His. The point where preparation of the greater curvature is begun is of limited importance but meticulous dissection of the subcardial region with visualization of the left diaphragmatic crus and avoidance of passing

the pylorus line are of utmost significance. Distance from the pylorus in the literature falls within 0-10 cm. Creating the sleeve and then liberating greater curvature is an interesting technique, which however does not have many followers [9, 11, 13-21, 24-26].

Stapler magazines used for sleeve creation are green, golden and blue, 60 mm long or shorter. Some authors use only green loads, with always the same staple length. There are studies of gastric wall thickness along the suture line which advise each time to adjust the length of staples (i.e. colour of stapler magazine) to a particular patient [9, 11-14, 18, 19, 21, 24-28]. Additional overlays in the stapler allow better haemostasis and avoid additional tightening suture but they are economically not justified in Polish reality [13, 17, 21, 26].

Placement of additional suture strengthening staple line continues to be discussed. Some authors believe it to be a redundant manoeuvre, extending operation time. Others claim this suture gives additional haemostasis and results in less suture line leakage [9-12, 15, 20, 24]. Another option is placement of 20-24 interrupted sutures instead of the continuous one [18].

Control of water tightness with methylene blue, drainage of the cardia region, and removal of the resected part of the stomach through one of the trocar site incisions ends every procedure [9-11, 13-15, 20, 21, 25]. Intraoperative complications occur rarely and according to the literature their frequency does not exceed a few per cent [3, 29]. Bleeding from the sectioned stomach wall is described most often (one must remember that the idea of the staples is not to impair tissue blood supply), yet it is easily controllable with an additional clip or suture. Blood loss in such situations is irrelevant and does not exceed several dozen millilitres [13, 15, 20-22, 26]. Damage to neighbouring organs is seldom described. Surprisingly, despite preparing in close proximity to the spleen, sometimes in difficult technical conditions (a lot of fat tissue, poor visibility, minute distance from the gastric fundus to the spleen) lesion to this organ is extremely rare and mostly limited to small damage of the capsule, which is easily controlled with fibrin sponge [13, 18]. Haemorrhages from the abdominal integument at trocar sites are far more dangerous. In extreme situations when unnoticed, they may call for re-intervention or result in abdominal wall haematoma, which once infected becomes a source of extensive abscess. One must remember that in

super-obese patients tegumental haematoma may be a few litres in volume and absorption of erythrocyte decay products can result in haemolytic jaundice [14].

Early leakage from the suture line is also described only in a few patients, even in large cohort studies. They usually occur in proximity to the gastroesophageal junction or at the meeting point of two stapler magazines. Operative treatment (laparoscopic or open) with suturing of the leak, anastomosis with Roux loop or gastrectomy is always necessary. Oesophageal prosthesis and tissue glue are some interesting options, too [4, 12-14, 17, 19, 21, 26, 30].

Post-op heart rate on the day of surgery has extreme diagnostic and prognostic value. Post surgery it is usually low, anywhere between 60 and 90 beats per minute. Sudden acceleration of the heartbeat indicates complications and urges the surgeon to search for a cause, which is usually bleeding or leakage.

Patients after laparoscopic procedures can be mobilized early and return of bowel peristalsis occurs early. As part of anti-coagulation and atelectasis prophylaxis and for its positive effect on lung ventilation it is of crucial importance for patients. Early return of GI tract contractility results in adequate stomach emptying which prevents increase in pressure within the stomach, which could potentially cause a leak of gastric content through the suture line and formation of fistula. The gastric tube is left after surgery in a few centres. Early oral feeding is preferred, starting with liquids and introducing solid food within a couple of days.

Perioperative mortality occurs rarely and its frequency does not exceed one per cent. It results from the surgery and from preoperative comorbidities (cardiac deaths) or from complications of obesity (thrombosis, pulmonary embolism) [16, 17].

Conclusions

- 1) Laparoscopic sleeve gastrectomy is a safe procedure with only a minimal number of intra- and perioperative complications.
- 2) Because of its advancement, LSG ought to be done in selected bariatric centres by surgeons experienced in laparoscopic surgery.

References

1. Dadan J, Iwacewicz P, Hady HR. Nowe trendy w chirurgii bariatrycznej. *Videosurgery and other miniinvasive techniques* 2008; 3: 66-70.
2. Stanowski E, Pańnik K. Chirurgiczne leczenie otyłości – aktualny stan wiedzy. *Videosurgery and other miniinvasive techniques* 2008; 3: 71-86.
3. Trybull A, Frask A, Michalik M. Resekcja rękawowa żołądka. *Videosurgery and other miniinvasive techniques* 2008; 3: 205-9.
4. Hamoui N, Anthone GJ, Kaufman HS, Crookes PF. Sleeve gastrectomy in the high-risk patient. *Obes Surg* 2006; 16: 1445-9.
5. Deitel M, Crosby RD, Gagner M. The First International Consensus Summit for Sleeve Gastrectomy (SG), New York City, October 25-27, 2007. *Obes Surg* 2008; 18: 487-96.
6. Pereferrer FS, Gonzalez MH, Rovira AF, et al. Influence of sleeve gastrectomy on several experimental models of obesity: metabolic and hormonal implications. *Obes Surg* 2008; 18: 97-108.
7. Kojima M, Hosoda H, Date Y, et al. Ghrelin is a growth hormone-releasing acylated peptide from stomach. *Nature* 1999; 402: 656-60.
8. Nakazato M, Murakami N, Date Y, et al. A role for ghrelin in the central regulation of feeding. *Nature* 2001; 409: 194-8.
9. Melissas J, Koukouraki S, Askoxylakis J, et al. Sleeve gastrectomy: a restrictive procedure? *Obes Surg* 2007; 17: 57-62.
10. Bernante P, Foletto M, Busetto L, et al. Feasibility of laparoscopic sleeve gastrectomy as a revision procedure for prior laparoscopic gastric banding. *Obes Surg* 2006; 16: 1327-30.
11. Givon-Madhala O, Spector R, Wasserberg N, et al. Technical aspects of laparoscopic sleeve gastrectomy in 25 morbidly obese patients. *Obes Surg* 2007; 17: 722-7.
12. Dapri G, Vaz C, Cadiere G.B, Himpens J. A prospective randomized study comparing two different techniques for laparoscopic sleeve gastrectomy. *Obes Surg* 2007; 17: 1435-41.
13. Nocca D, Krawczykowsky D, Bomans B, et al. A prospective multicenter study of 163 sleeve gastrectomies: results at 1 and 2 years. *Obes Surg* 2008; 18: 560-5.
14. Skrekas G, Lapatsanis D, Stafyla V, et al. One year after laparoscopic "tight" sleeve gastrectomy: technique and outcome. *Obes Surg* 2008; 18: 810-3.
15. Roa PE, Kaidar-Person O, Pinto D, et al. Laparoscopic sleeve gastrectomy as treatment for morbid obesity: technique and short-term outcome. *Obes Surg* 2006; 16: 1323-6.
16. Gumbs A, Gagner M, Dakin G, Pomp A. Sleeve gastrectomy for morbid obesity. *Obes Surg* 2007; 17: 962-9.
17. Weiner RA, Weiner S, Pomhoff I, et al. Laparoscopic sleeve gastrectomy – influence of sleeve size and resected gastric volume. *Obes Surg* 2007; 17: 1297-305.
18. Braghetto I, Korn O, Valladares H, et al. Laparoscopic sleeve gastrectomy: surgical technique, indications and clinical results. *Obes Surg* 2007; 17: 1442-50.
19. Mui WL, Ng EK, Tsung BY, et al. Laparoscopic sleeve gastrectomy in ethnic obese chinese. *Obes Surg* 2008; 18: 1571-4.
20. Rubin M, Yehoshua RT, Stein M, et al. Laparoscopic sleeve gastrectomy with minimal morbidity early results in 120 morbidly obese patients. *Obes Surg* 2008; 18: 1567-70.
21. Silecchia G, Boru C, Pecchia A, et al. Effectiveness of laparoscopic sleeve gastrectomy (first stage of biliopancreatic diversion with duodenal switch) on co-morbidities in super-obese high-risk patients. *Obes Surg* 2006; 16: 1138-41.

22. Himpens J, Dapri G, Cadie're GB, et al. A prospective randomized study between laparoscopic gastric banding and laparoscopic isolated sleeve gastrectomy: results after 1 and 3 years. *Obes Surg* 2006; 16: 1450-6.
23. Baltasar A, Serra C, Perez N, et al. Re-sleeve gastrectomy. *Obes Surg* 2006; 16: 1535-8.
24. Vidal J, Ibarzabal A, Nicolau J, et al. Short-term effects of sleeve gastrectomy on type 2 diabetes mellitus in severely obese subjects. *Obes Surg* 2007; 17: 1069-74.
25. Yehoshua RT, Eidelman LA, Stein M, et al. Laparoscopic sleeve gastrectomy – volume and pressure assessment. *Obes Surg* 2008; 18: 1083-8.
26. Ou Yang O, Loi K, Liew V, et al. Staged laparoscopic sleeve gastrectomy followed by Roux-en-Y gastric bypass for morbidly obese patients: a risk reduction strategy. *Obes Surg* 2008; 18: 1575-80.
27. Baker RS, Foote J, Kemmeter P, et al. The science of stapling and leaks. *Obes Surg* 2004; 14: 1290-98.
28. Elariny H, González H, Wang B. Tissue thickness of human stomach measured on excised gastric specimens from obese patients. *Surg Technol Int* 2005; 14: 119-24.
29. Santoro S. Technical aspects in sleeve gastrectomy. *Obes Surg* 2007; 17: 1534-5.
30. Serra C, Baltasar A, Andreo L, et al. Treatment of gastric leaks with coated self-expanding stents after sleeve gastrectomy. *Obes Surg* 2007; 17: 866-872.