

Percutaneous radiofrequency ablation combined with chemoembolization in hepatocellular carcinoma: assessment of palliative treatment

Maciej Jaworski¹, Olgierd Rowiński¹, Andrzej Cieszanowski¹, Marek Krawczyk², Bogusław Najnigier²

¹2nd Department of Clinical Radiology, Medical University of Warsaw

²Department of General, Transplantation and Liver Surgery, Medical University of Warsaw

Videosurgery in other miniinvasive techniques 2009; 4, 2: 59–66

Abstract

Introduction: In palliation of hepatocellular carcinoma the best results are obtained in tumours not bigger than 3 cm with alcohol injections and thermoablation. Tumours exceeding 5 cm are most often treated with chemoembolization. Our experience with combination of chemoembolization and percutaneous thermoablation is presented below.

Aim: Assessment of factors which influence outcomes and usefulness of this treatment method.

Material and methods: The study group consisted of 25 patients with HCC. Four methods of visualization were applied: MRI, ultrasound, power Doppler and DSA done before the procedure, one day after, and repeated every 4 weeks. Completeness of the procedure, tumour size and vascularization as well as liver blood flow were assessed.

Results: Forty-five combined procedures were performed. Complete remission was achieved in 5 (20%) cases. Foci of hepatocellular carcinoma were shown to shrink after exposure to combined therapy ($p < 0.01$). Smaller size tumours were statistically more likely to decrease with applied therapy ($r = -0.41$). Combination therapy proved to decrease blood supply of the tumour ($p < 0.01$).

Conclusions:

1. Combination of chemoembolization and percutaneous thermoablation for non-resectable hepatocellular carcinoma is relatively minimally invasive and allows for palliative therapy of the tumour.
2. Combination procedure inhibited tumour growth or decreased tumour size in all studied cases.
3. Complete response is unlikely with combination therapy and is as low as 20%.
4. Response to chemoembolization and thermoablation combination therapy depends on tumour size and not on tumour vascularization.
5. Contrast-enhanced MRI and ultrasound with power Doppler option are very helpful in monitoring of the patient after combination therapy.

Key words: hepatocellular carcinoma, radiofrequency ablation, transcatheter arterial chemoembolization, liver disease.

Introduction

Liver resection is a method of choice for hepatocellular cancer (HCC) [1]. Since a significant number of patients are not eligible for surgical treatment, palliative methods were developed:

chemotherapy, infusion chemotherapy, chemoembolization and, when the tumour can be accessed percutaneously, alcoholization and numerous forms of thermoablation. The best palliation is achieved in single nodules up to 3 cm in diameter with alcoholization and thermoablation [2, 3]. In large

Address for correspondence

Maciej Jaworski, 28 Arctowskiego St # 4, 02-784 Warszawa, phone 510 217 606, e-mail: maciej.jaworski@medicover.pl

tumours, exceeding 5 cm, and in multifocal changes the best results, in terms of patient survival, are obtained with selective chemoembolization [4]. In this study a combination of chemoembolization and thermoablation was used to attain a better therapeutic effect than monotherapy. Herein, results of combination therapy for non-resectable HCC are presented.

Aim

Assessment of the efficacy of palliative combination therapy with chemoembolization and thermoablation of HCC and review of factors affecting treatment results were the main aims of this study.

Table I. Cirrhosis staged with Child-Pugh score

Patients	No. of patients	A	B	C
Women	9	6	3	0
Men	10	7	2	1
Total	19	13	5	1

Table II. Size of liver tumours

Patients	Single nodule	Multiple nodules	Tumour size [mm]
Women	12	2	38-50
Men	7	4	39-52
Total	19	6	38-52

Table III. Parameters applied in MRI

Sequence	Pictures retrieved	TR/TE (or TEeff)	Flip	TI	LE	TF	NSA	BO	GW [mm]	Matrix
T2 Dual TSE	T2W	1800/(40/120)	90	–	2	12	2	+	5-7	256
T2 STIR	T2W	1800/100	90	150	1	16	3	+	5-7	256
T1 Dual Echo GRE	T1W	212/(2.3/4.8)	80	–	2	–	1	–	7	256
T1 2D GRE	T1W	183/1.8	80	–	1	–	1	–	7	256

TR – time of repetition, TE – time of echo, TEeff – effective time of echo, flip – deviation angle, TI – inversion time, LE – number of echoes, TF – turbo factor, NSA – number of signal averages, BO – respiratory gating, GW – layer thickness

Material and methods

A group of 25 patients was selected, including 14 women (56%) and 11 men (44%) aged 62-82 years. In 19 cases (76%) diagnosis of HCC was confirmed histologically. Two tumours were recurrences found 8 and 14 months after liver resection. In 6 cases (24%) diagnosis was made on typical clinical course and results of visual studies (CT, MRI, ultrasound) and laboratory findings including serum concentration of α -fetoprotein [5]. In 19 cases (76%) liver cirrhosis was diagnosed; disease was staged with Child and Pugh scale (Table I) [6].

Patients presented with concomitant infections: HIV in 14 cases (56%) and HCV in 8 (32%). Four patients suffered from insulin-dependent diabetes. No portal thrombosis was found. Tumours were characterized as unifocal and multifocal. Tumour size was measured in millimetres of the longest axis; in multimodal changes the diameter of the tumour chosen for combination therapy was given. Data are presented in Table II.

Prospective study with four diagnostic methods: magnetic resonance imaging (MRI), ultrasound, power/colour-angio-power (CPA) Doppler, subtraction angiography/digital subtraction angiography (DSA). Parameters applied in MRI are shown in Table III.

Scheme of studies

The scheme of performed studies:

Studies performed prior to the treatment

- 1) MRI without and with intravenous contrast and assessment of:
 - number of tumours,
 - location of lesions,

- tumour size,
 - tumour vascularization (dynamic assessment): 0 – no vascularization, 1 – limited vascularization of the marginal portion of the tumour, 2 – substantial vessel dividing within central part of the tumour;
- 2) ultrasound, CPA, assessment of:
- number of lesions,
 - size of foci,
 - tumour vascularization: 0 – no vascularization, 1 – limited vascularization of the marginal portion of the tumour, 2 – substantial vessel dividing within central part of the tumour;
- 3) serum α -fetoprotein;
- 4) subtraction arteriography, assessment of:
- number of lesions,
 - tumour vascularization: 0 – no vascularization, 1 – limited vascularization of the marginal portion of the tumour, 2 – substantial vessel dividing within central part of the tumour.

Qualification for the therapy was made by a team consisting of a surgeon and intervention radiologist trained in both procedures. Only patients ineligible for operative treatment were included in the programme.

Chemoembolization

Chemoembolization was done under local anaesthesia through femoral access at the segmental or subsegmental level. The lesion was gradually filled with 50 mg : 10 ml doxorubicin and lipiodol emulsion via a selective, coaxial catheter. The amount of emulsion was maximized for the vascular bed of the embolized tumour. Additionally, afferent vessels were closed with particles of Spongostan. When disseminated satellite lesions preventing selective embolization were present, cytostatic/lipiodol emulsion was administered unselectively to the lobar branch of the hepatic artery or to the proper hepatic artery itself.

Thermoablation

Thermoablation: percutaneous radiofrequency ablation (RFA) was performed within 72 hours following chemoembolization in local anaesthesia, with anaesthetist participation to administer sedation whenever necessary. All procedures were guided with ultrasound with CPA and real-time 3D guidance options. The tip of an active applicator was

placed in the central part of the tumour, then the lesion was soft-coagulated with high frequency current. Length of active tips of applicators was 15-20 mm, power of the generator was set at 40-60 Watts and duration of the procedure was 10-30 minutes. Procedures were accomplished with Brechtold Elektrotom HiTT 106 apparatus with continuous physiological saline infusion through automated syringe and active applicator.

Control after treatment

- 1) following chemoembolization:
 - a) subtractive angiography to assess tumour vascularization,
 - b) CPA, ultrasound with assessment of tumour vascularization;
- 2) following thermoablation:
 - a) CPA, ultrasound with assessment of tumour vascularization;
- 3) 3-4 weeks after treatment:
 - a) MRI without and with contrast to assess tumour size and its vascularization,
 - b) CPA ultrasound with measurement of tumour size and vascularization,
 - c) serum concentration of α -fetoprotein;
- 4) every 4 weeks – ultrasound and CPA to measure tumour size and assess vascularization.

Therapy was assessed according to the following criteria:

- progression of the disease – increase in tumour size of 25% and/or new hepatic lesion,
- stabilization of disease – decrease in tumour size of less than 50% or increase of less than 25%,
- partial response – decrease in tumour size of more than 50%,
- complete response – complete remission of the tumour.

Effectiveness of the therapy was assessed in control studies 3-4 weeks after the procedures:

- 1) radical procedure:
 - ultrasound CPA – no blood flow seen within the tumour mass,
 - MRI without and with contrast – no tumour enhancement seen after contrast injection;
- 2a) non-radical procedure, acceptable result:
 - ultrasound CPA – pathological vessels seen in marginal portion of the tumour,
 - MRI with and without contrast – marginal tumour enhancement after contrast injection;

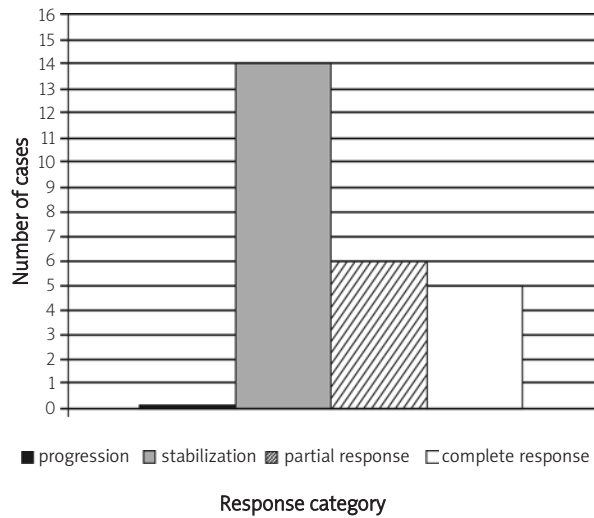


Figure 1. Tumour response to combination therapy

2b) non-radical procedure, insufficient result:

- ultrasound CPA – pathological vessels seen in central portion of tumour,
- MRI with and without contrast – central tumour enhancement after contrast injection.

When pathological vessels were seen on ultrasound and/or MRI in the areas exposed to treatment, patients were admitted for the repeat procedure and evaluation:

- after non-radical procedure with acceptable result, whenever technical possibility to repeat the procedure (sufficient area for RFA applicator placement) occurred; until then, patients were controlled with ultrasonography and assessment of tumour vascularization every 4 weeks;
- after non-radical procedure with insufficient result immediately after an unacceptable result was found.

Results

Forty-five combined chemoembolization and thermoablation procedures were performed in a group of 25 patients. Six tumours were evaluated as poorly vascularized in both ultrasound power angiography and MRI. Twenty patients had repeated procedures and then were followed as scheduled after the first cycle of treatment.

Complete response was diagnosed when total affected area turned necrotic, without enhancement after contrast infusion in MRI and lack of pathological blood flow in ultrasound CPA. Complete response was reached in 5 cases (20%). In all remaining cases we were able to achieve stabilization of disease or a partial response (Figure 1).

Foci of the HCC exposed to combination therapy with chemoembolization and radioablation have statistically been shown to shrink. For Student's

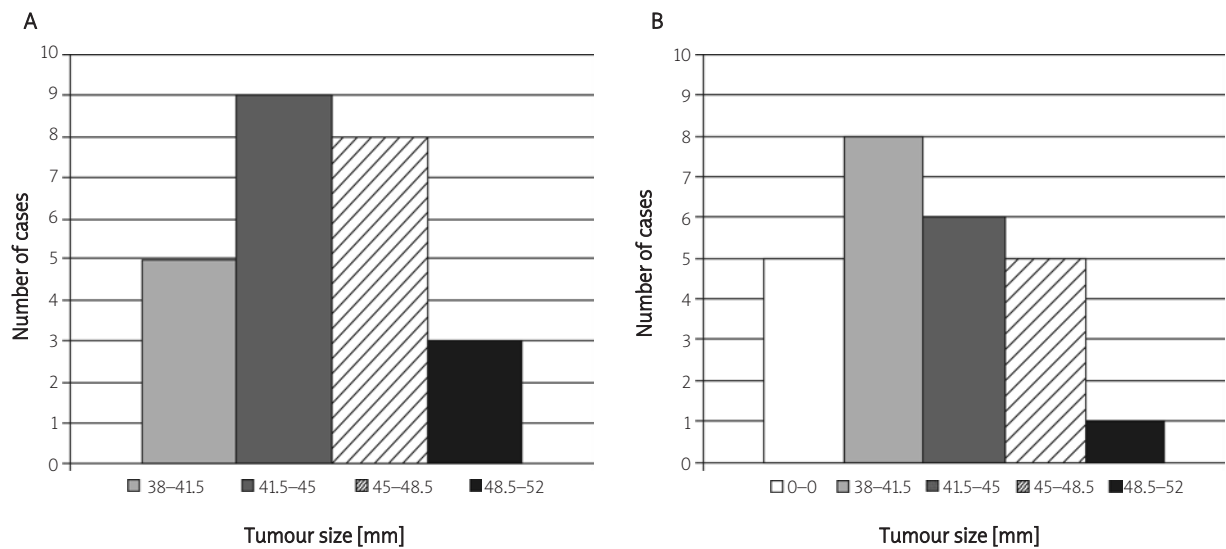


Figure 2. Tumour size: A) before treatment and B) after treatment

t test, the result of *t* statistics was $t = 9.84$ at $p < 0.01$ (Figure 2).

Smaller tumours have been statistically proven to decrease their size more easily ($r = -0.41$, Figure 3).

Combination therapy decreased tumour vascularization (χ^2 statistic 21.89 with two degrees of freedom and $p < 0.01$, Figure 4).

Effectiveness of the procedure was independent from tumour vascularization prior to the treatment in linear regression analysis. Decrease of α -fetoprotein from 1400-29000 to 20-20 000 mg/dl was found in all cases. Extreme values were seen when a single lesion was chosen and treated in *a priori* multi-focal disease. In single nodules α -fetoprotein concentration was 20-210 mg/dl.

Procedure-related complications encountered in this trial were mostly insignificant and included:

- 1) post-chemoembolization – temporary nausea and vomiting, increase in body temperature, and one case (2%) of pseudoaneurysm in the site of femoral artery puncture was noted,
- 2) post-thermoradioablation – temporary pain at the site of electrode introduction and intra-abdominal abscess requiring drainage was needed in one case (2%).

Discussion

Hepatocellular cancer is the most common form of primary liver cancer. According to the literature, it accounts for 4% of all malignant neoplasms [7].

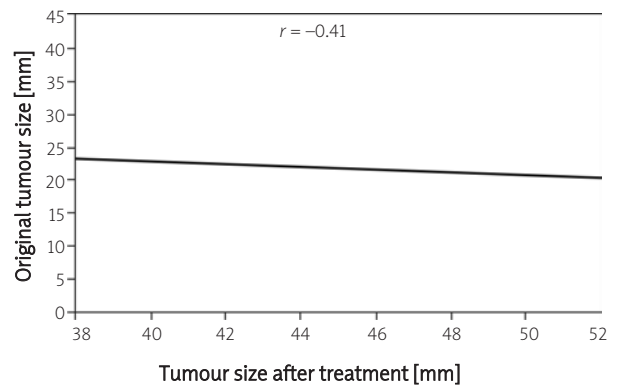


Figure 3. Tumour size after therapy in relation to its original diameter

Surgical resection is a treatment of choice for HCC, yet only 10-20% of cases qualify for this method. The remaining majority cannot be treated with surgery. Multifocal nature of tumours and advanced liver cirrhosis are the main causes of unresectability [8]. When no treatment is administered, according to prognostic analysis by Okuda, even in the least advanced cases mean survival time does not exceed 6 months from diagnosis [9]. Elimination of a substantial proportion of patients from surgical treatment led to the development of alternative, non-operative methods. These include: chemoembolization, percutaneous ethanol injection (PEI), and thermoablation, i.e. destruction of tissue with

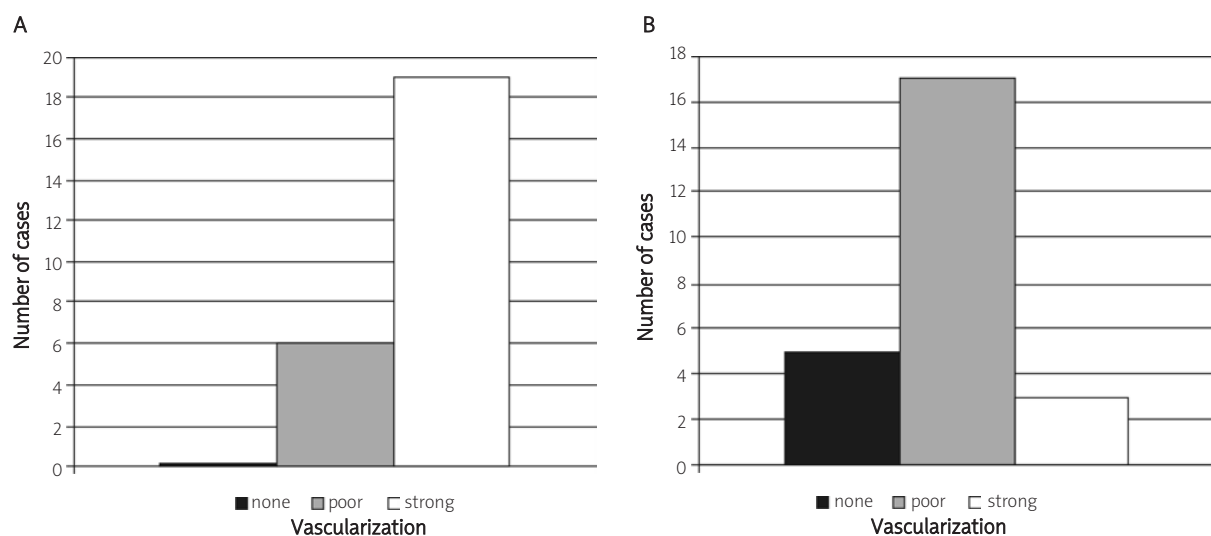


Figure 4. Tumour vascularization: A) before treatment and B) after treatment

high or low (cryoablation) temperature. High temperatures are applied most often and are generated by radio frequency waves (radioablation, radiofrequency ablation – RFA) or by microwaves [11, 12]. Hepatocellular cancer is characterized by well-developed blood supply from the arterial vascular system of the liver. In comparison to other primary and secondary (other than endocrine metastases) tumours, HCC is characterized by a substantial network of pathological vessels. There are however forms poorly and only marginally supplied with blood, that do not develop any web of blood vessels. In any case, 90% of blood supply of HCC comes in from the hepatic artery [13, 14]. This is totally different from the liver parenchyma, receiving 75% of its supply from the portal circulation [15]. For these reasons, embolization of the hepatic artery can result in necrosis of tumour cells without significantly affecting remnant liver parenchyma. This finding scientifically justified and gave birth to chemoembolization procedures. Then, beneficial properties of lipiodol were confirmed: it embolizes the tumour at the level of the sinusoids (preventing both arterial and portal inflow) and exerts a selective cytotoxic effect on HCC cells [16, 17]. Lipiodol is now the most popular embolizing agent used as a selective carrier of cytostatics, which, once emulsified, reach an extremely high concentration within the tumour mass.

As HCC develops mostly in a cirrhotic liver (76% of cases in the material of this study), preservation of liver parenchyma is of vital importance [18]. In segmental and subsegmental selective chemoembolization, a therapeutic effect was attained due to physical properties of lipiodol and high local concentration of a cytostatic. This effect is augmented by closure of afferent arterial vessels. Various cytostatics are used at different centres, yet in comparative multicentre studies the effects of diverse cytostatics were equal [19]. The key question is precision of the performed procedure [20].

Another, relatively new method of liver tumours' palliation is RFA. The procedure consists of accurate placement of an applicator in the very centre of the tumour or sequential puncturing of overlapping areas of the larger tumour. Applicators, which in fact are radio antennas causing ion oscillations and thus generate extreme temperatures, are positioned transcutaneously or with laparoscopic guidance. Best therapeutic results are obtained in

proximity to an applicator, and effective diameter of necrosis rarely exceeds 3 cm. The most important factors which limit this method are loss of generated heat with blood flow in major vessels adjacent to the lesion, and non-homogeneous nature of tumours and surrounding tissue, which prevents uniform wave propagation [21]. Too low or too high temperature (above 100°C) at the tip of an applicator is an undesired effect – it causes charring of adherent tissues which prevents wave propagation. To eliminate this phenomenon, cooling of applicators with fluid or tapering their temperature with elongated exposure time is used [22]. To increase the area of necrosis, anchor-shaped tips or combined sets of 2-3 united applicators or, as in this study, continuous infusion of saline are used. In the latter case, physiological saline solution is continuously infused with an automated syringe connected to a wave generator; the solution leaks out to the surrounding tissue through perforations in the applicator. Thus, new portions of ions are available and penetration of the fluid increases the area of therapeutic effect of generated radio waves [23, 24].

Integration of chemoembolization and thermoablation methods was based on the idea to exclude the tumour from hepatic blood circulation, saturate it with homogeneous cytostatic emulsion with lipiodol and, as a consequence, create a better environment for larger tumour necrosis attained in second step of thermoablation [25].

Widely accepted WHO criteria were applied for the assessment of the therapeutic results in this study. Five cases (20%) of complete response is rather low in comparison to contemporary literature [26-28]. Yet, in all remaining patients stabilization of the disease or a partial response was observed. We believe that imprecise execution of the second stage of combination therapy, i.e. thermoablation, induced a low rate of complete remission. In each case the first stage, i.e. chemoembolization, was completed with technical success. In multi-focal disease and in suspicion of satellite changes on DSA, after the regular part of chemoembolization was completed, an additional dose of lipiodol with cytostatic was administered unselectively into the remnant liver parenchyma, which gave B-presentation ultrasound aberrances during needle positioning for radioablation. Another reason was difficulty in RFA monitoring due to overlap of hyperechoic tumour after chemoembolization and hyperechoic, thermoablation-

generated foci of necrosis. In tumours exceeding 40 mm, the sonographic picture during follow-up was aberrated from asymmetric saline penetration into surrounding tissues [29]. The authors, who presented better results, treated smaller tumours, up to 3 cm, or used a longer time lag – up to 2 weeks from chemoembolization to RFA [27, 30].

Analysis of treatment results has proven statistically, with probability of $p < 0.01$ for Student's t test, that HCC tumours shrink when exposed to combination therapy. It was also shown that smaller tumours have a better chance of remission than large ones and are more susceptible to this method of treatment. In all patients a statistically significant decrease of α -fetoprotein in serum was observed after the procedure.

In our study blood flow determination with ultrasound CPA and assessment of tumour vascularization with contrast MRI and DSA were completely convergent [31]. In direct angiographic control complete cessation of arterial-phase blood flow within the tumour was shown in all cases. To assess tumour vascularization, simple stratification of tumours into 3 groups (with substantial, poor and no vascularization) was made. Prior to the procedure 6 tumours were assigned to the poorly vascularized group. Change in blood supply was an effect of the performed procedure. After analysis of study results we can state that lack of arterial flow in embolized tumours was transient in the majority of cases. To achieve maximal effectiveness, procedures should be repeated until a satisfactory result is obtained.

Conclusions

1. Combination therapy with chemoembolization and percutaneous thermoablation for inoperative HCC are relatively minimally invasive procedures allowing palliative treatment of the neoplasm.
2. Inhibition of tumour growth or decrease in tumour mass was achieved in nearly all cases after combination treatment.
3. Complete tumour resolution after combination treatment is as low as 20%.
4. Effectiveness of combination therapy with chemoembolization and thermoablation depends on tumour size and is independent from its vascularization.
5. Visual studies MRI with contrast and ultrasound with power Doppler option are highly applicable in monitoring of patients after combination treatment.

Acknowledgments

Study supported from Ministry of Science and Higher Education grant 2 PO5C 009 26.

References

1. Bismuth H, Chiche L, Adam R, et al. Liver resection versus transplantation for hepatocellular carcinoma in cirrhotic patients. *Ann Surg* 1993; 218: 145-51.
2. Livraghi T, Giorgio A, Marin G, et al. Hepatocellular carcinoma and cirrhosis in 746 patients: long-term results of percutaneous ethanol injection. *Radiology* 1995; 197: 101-8.
3. Lencioni RA, Allgaier HP, Cioni D, et al. Small hepatocellular carcinoma in cirrhosis: randomized comparison of radiofrequency thermal ablation versus percutaneous ethanol injection. *Radiology* 2003; 228: 235-40.
4. Dalla Palma L. Diagnostic imaging and interventional therapy of hepatocellular carcinoma. *Br J Radiol* 1998; 71: 808-18.
5. Choi BI, Park JH, Kim BH, et al. Small hepatocellular carcinoma: detection with sonography, computed tomography (CT), angiography and Lipiodol-CT. *Br J Radiol* 1989; 62: 897-903.
6. Pugh RN, Murray-Lyon IM, Dawson JL, et al. Transsection of oesophagus for bleeding oesophageal varices. *Br J Surg* 1973; 60: 646-9.
7. Okuda K. Epidemiology. In: Livraghi M, Makuuchi M, Buscarini L. *Diagnosis and treatment of hepatocellular carcinoma*. Greenwich Medical Media, London 1997; 3-15.
8. Cha CH, Ruo L, Fong Y, et al. Resection of hepatocellular carcinoma in patients otherwise eligible for transplantation. *Ann Surg* 2003; 238: 315-21.
9. Okuda K, Obata H, Nakajima Y, et al. Prognosis of primary hepatocellular carcinoma. *Hepatology* 1984; 4 (1 Suppl): S3-6.
10. Najnigier B, Nyckowski P, Wróblewski T, et al. Wyniki zastosowania krioablacji jako metody umożliwiającej rozszerzenie zakresu leczenia operacyjnego złośliwych nowotworów wątroby. *Wideochirurgia i inne techniki małoinwazyjne* 2008; 3: 157-71.
11. Yamamoto J, Okada S, Shimada K, et al. Treatment strategy for small hepatocellular carcinoma: comparison of long-term results after percutaneous ethanol injection therapy and surgical resection. *Hepatology* 2001; 34: 707-13.
12. Xu HX, Lu MD, Xie XY, et al. Prognostic factors for long term outcome after percutaneous thermal ablation for hepatocellular carcinoma: a survival analysis of 137 consecutive patients. *Clin Radiol* 2005; 60: 1018-25.
13. Ackerman NB. Experimental studies on the circulatory dynamics of intrahepatic tumor blood supply. *Cancer* 1972; 29: 435-9.
14. Satoh M, Yamada R. Experimental and clinical studies on hepatic artery embolization for treatment of hepatoma. *Nippon Igaku Hoshasen Gakkai Zasshi* 1983; 43: 977-1005.

15. Lauth WW, Greenway CV. Conceptual review of the hepatic-vascular bed. *Hepatology* 1987; 7: 952-63.
16. Kan Z. Dynamic study of iodized oil in the liver and blood supply to hepatic tumors: an experimental investigation in several animal species. *Act Radiol Suppl* 1996; 408: 1-25.
17. Kan Z, Wallace S. Sinusoidal embolization: impact of iodized oil on hepatic microcirculation. *J Vasc Interv Radiol* 1994; 5: 881-6.
18. Fried MW. Treatment of hepatocellular carcinoma: medical options. *Liver Transpl Surg* 1998; 4 (5 Suppl 1): S92-7.
19. Bezzi M. Chemoembolization and embolization in general. CIRSE 1996 summary report. *Cardiovasc Interv Radiol Suppl* 1996; 19: 218.
20. Uchida H, Matsuo N, Sakaguchi H, et al. Segmental embolotherapy for hepatic cancers: keys to success. *Cardiovasc Interv Radiol* 1993; 16: 67-71.
21. McGhana JP, Dodd GD 3rd. Radiofrequency ablation of the liver: current status. *AJR Am J Roentgenol* 2000; 176: 3-16.
22. Ni Y, Miao Y, Mulier S, et al. A novel „cooled-wet” electrode for radiofrequency ablation. *Eur Radiol* 2000; 10: 852-4.
23. Goldberg SN, Gazelle GS, Dawson SL, et al. Tissue ablation with radiofrequency using multiprobe arrays. *Acad Radiol* 1995; 2: 670-4.
24. Goldberg SN, Gazelle GS, Solbiati L, et al. Radio-frequency tissue ablation: increased lesion diameter with perfusion electrode. *Acad Radiol* 1996; 3: 636-44.
25. Buscarini L, Buscarini E, Di Stasi M, et al. Percutaneous radiofrequency thermal ablation combined with transcatheter arterial embolization in the treatment of large hepatocellular carcinoma. *Ultraschall Med* 1999; 20: 47-53.
26. Kitamoto M, Imagawa M, Yamada H, et al. Radiofrequency ablation in the treatment of small hepatocellular carcinoma: comparison of radiofrequency effect with and without chemoembolization. *AJR Am J Roentgenol* 2003; 181: 997-1003.
27. Yamakado K, Nakatsuka A, Takaki H, et al. Early-stage hepatocellular carcinoma: radiofrequency ablation combined with chemoembolization versus hepatectomy. *Radiology* 2008; 247: 260-6.
28. Yamakado K, Nakatsuka A, Ohmori S, et al. Radiofrequency ablation combined with chemoembolization in hepatocellular carcinoma: treatment response based on tumor size and morphology. *J Vasc Interv Radiol* 2002; 13: 1225-32.
29. Rhim H, Lee M, Kim YS, et al. Planning sonography to assess the feasibility of percutaneous radiofrequency ablation of hepatocellular carcinoma. *AJR Am J Roentgenol* 2008; 190: 1324-30.
30. Yamakado K, Nakatsuka A, Akeboshi M, et al. Combination therapy with radiofrequency ablation and transcatheter chemoembolization for the treatment of hepatocellular carcinoma: short-term recurrences and survival. *Oncol Rep* 2004; 11: 105-9.
31. Lim HS, Jeong YY, Kang HK, et al. Imaging features of hepatocellular carcinoma after transcatheter arterial chemoembolization and radiofrequency ablation. *AJR Am J Roentgenol* 2006; 187: W341-9.