

Dynamic Thebesian veins anomaly in a patient with recurrent tako-tsubo-like syndrome

Mateusz Drabczyk^{1,2}, Zofia Kampka^{1,2}, Małgorzata Cichoń^{1,2}, Michał Holeccki³, Katarzyna Mizia-Stec^{1,2,4}, Maciej Tomasz Wybraniec^{1,2,4}

¹First Department of Cardiology, School of Medicine in Katowice, Medical University of Silesia, Katowice, Poland

²Upper Silesia Medical Centre, Katowice, Poland

³Department of Internal, Autoimmune and Metabolic Diseases, Medical University of Silesia, Katowice, Poland

⁴Members of European Reference Network ERN GUARD-HEART, Amsterdam, Netherlands

Adv Interv Cardiol 2024; 20, 1 (75): 119–120
DOI: <https://doi.org/10.5114/aic.2024.136409>

A 75-year-old female patient was referred to the department of cardiology on account of dyspnea at rest of several days duration. Past medical history revealed an episode of tako-tsubo with non-obstructive, tortuous coronary arteries 11 years ago (Figures 1 A, C), complicated by an episode of acute decompensated heart failure. Following the acute event, the patient was asymptomatic and received merely antihypertensive medications. On admission the patient presented with an irregular heart rate of 110 bpm, blood pressure of 110/70 mm Hg, peripheral edema and pulmonary congestion. The ECG showed atrial fibrillation without significant ST-segment abnormalities. Transthoracic echocardiography revealed left ventricle ejection fraction (LVEF) of 20% with dyskinesia of the apical segments of the left ventricle and normal chamber dimensions without left ventricular hypertrophy or right ventricular overload. Laboratory tests showed elevated and stable troponin T level, elevated N-terminal-pro-B-type natriuretic peptide (2456 pg/ml) and features of stage III chronic kidney disease. Invasive coronary angiography disclosed tortuous left coronary artery without significant coronary stenoses within epicardial coronary vessels and prominent Thebesian veins draining blood directly to the left ventricle (Figures 1 B, D), which were not visible during the initial study 11 years previously. Following intensive heart failure pharmacotherapy, including disease-modifying drugs and intravenous loop diuretics, relief of heart failure symptoms and significant improvement of LVEF to 50% were achieved. The likely cause of the cardiovascular decompensation episodes was identified as tako-tsubo-like syndrome. Following successful management, the patient was discharged with a referral for electrical cardio-

version of atrial fibrillation, which was successfully performed 4 weeks following initial hospitalization.

The Thebesian veins may serve as a minor, alternative pathway for venous drainage of the myocardium with the direct emptying of blood into the heart chambers, which contributes to the physiological right-to-left shunting of circulation. With their enlargement or increased quantity, pathological left-to-left shunting becomes possible, creating a loop-like pathway that redirects blood from the aorta to the coronary arteries, then back into the left ventricle, and once again into the aorta. This represents a form of coronary stealing, leading to reduced myocardial perfusion and the manifestation of anginal symptoms or even acute coronary syndrome [1]. The present case is a unique tako-tsubo-like presentation of Thebesian veins-related myocardial steal phenomenon. Primary tako-tsubo syndrome is characterized by dominant acute cardiac symptoms leading to hospitalization, potentially triggered by emotional or physical stress, which may be undisclosed upon admission, while secondary tako-tsubo affects hospitalized patients on top of the existing medical or surgical condition [2]. Although a surge in catecholamine levels plays a crucial role in tako-tsubo pathogenesis, microvascular dysfunction or myocardial steal phenomenon may also trigger tako-tsubo-like syndrome [3]. The present case highlights the possible dynamic nature of Thebesian veins anomaly, which was present in the index coronary angiography, but was absent in the former study.

Conflict of interest

The authors declare no conflict of interest.

Corresponding author:

Dr. Maciej Tomasz Wybraniec, First Department of Cardiology, School of Medicine in Katowice, Medical University of Silesia, Katowice, Poland; Upper Silesia Medical Centre, Katowice, Poland, phone: +48 32 359 88 90, e-mail: maciejwybraniec@gmail.com

Received: 2.01.2024, **accepted:** 8.01.2024, **online publication:** 15.03.2024.

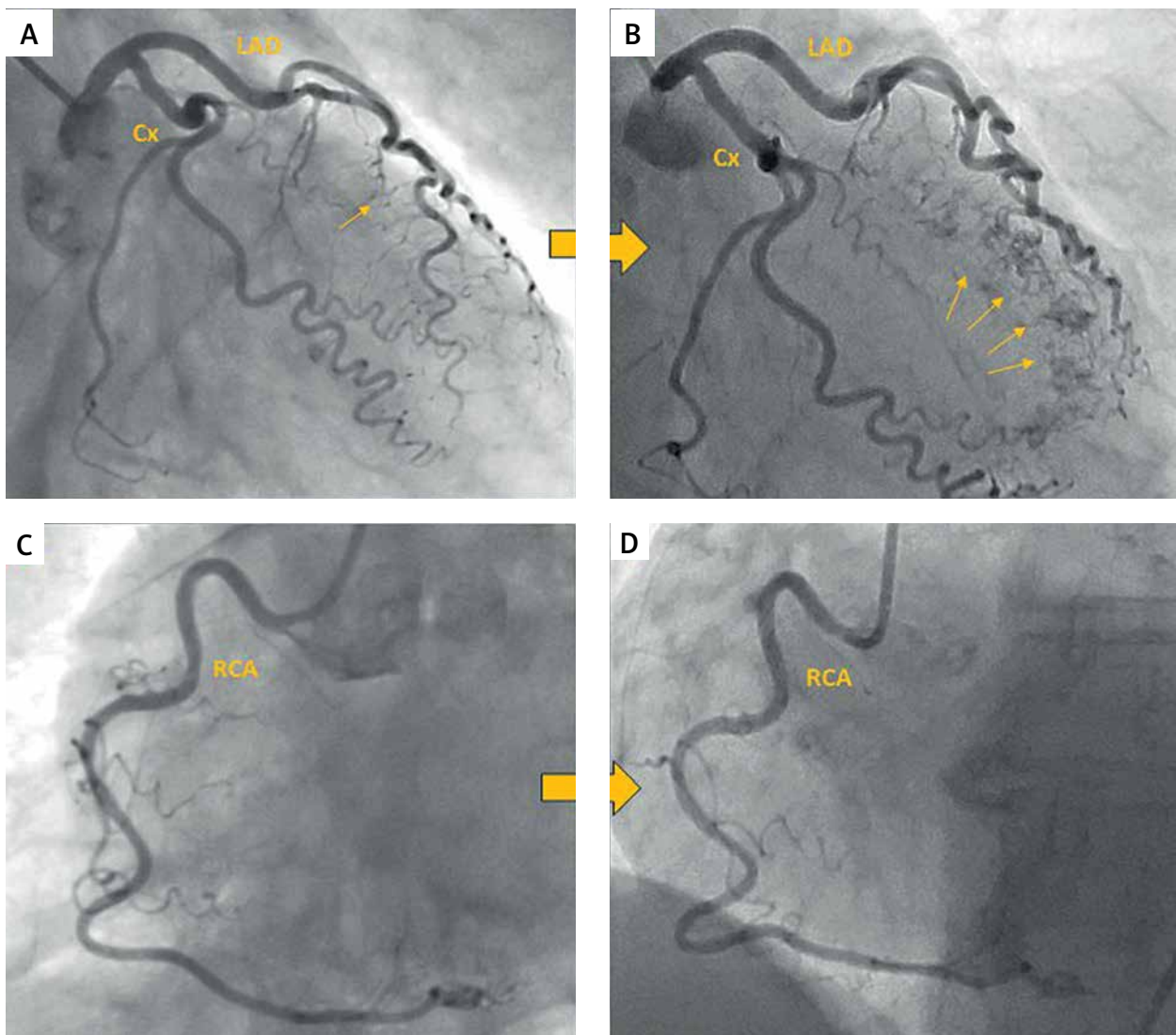


Figure 1. Prominent Thebesian vein system developing within ten-year period reflected by invasive coronary angiography. **A** – coronary angiography; left anterior oblique (LAO) 30°; caudal (CAU) 15°; tortuous course of left coronary artery without significant lesions; no visible Thebesian veins on coronary angiography in 2012; **B** – coronary angiography; LAO 30°; CAU 15°; prominent Thebesian veins on coronary angiography in 2023; **C, D** – coronary angiography; LAO 45°; stable image of right coronary angiography without visible anomaly

References

1. Dixit P, Shah R, Agrawal Y, et al. Prominent Thebesian veins in association with takotsubo cardiomyopathy. *Cureus* 2021; 13: e16204.
2. Lyon AR, Bossone E, Schneider B, et al. Current state of knowledge on Takotsubo syndrome: a position statement from the taskforce on takotsubo syndrome of the Heart Failure Association of the European Society of Cardiology. *Eur J Heart Fail* 2016; 18: 8-27.
3. Ghadri JR, Templin C. The InterTAK Registry for Takotsubo syndrome. *Eur Heart J* 2016; 37: 2806-8.