

Symptoms of hypovolemic shock during the induction of general anaesthesia in a patient with large vascular malformation — an adverse effect of propofol and sevoflurane?

Dawid Wiszniewski¹, Przemysław Przewratil², Andrzej Piotrowski¹

¹*Department of Intensive Therapy and Anaesthesiology, II Chair of Paediatrics, Maria Konopnicka Teaching Hospital No. 4 in Łódź, Medical University of Łódź, Poland*

²*Department of Paediatric Surgery and Oncology, M. Konopnicka Teaching Hospital No. 4, Medical University of Łódź, Poland*

Abstract

Background: Venous malformations are the second most common congenital vessel anomaly. In our hospital, we conduct up to 30 sclerotherapies with 1–3% aethoxysclerol annually in children of all ages. The procedure is invasive and painful and therefore requires general anaesthesia.

Case report: A 16-year-old girl underwent sclerotherapy of a vast vascular malformation of her left leg, pelvis, abdominal cavity and thorax. After induction of general anaesthesia and positioning for the procedure, she presented with hypotonic shock with sinus tachycardia and sudden decrease in her $E_T\text{CO}_2$. Her skin became pale and cold. The venous malformation became distended. The incident was caused by redistribution of the blood to the malformation, which is believed to have been triggered by the volatile anaesthetic. After discontinuation of the sevoflurane, modification of anaesthesia and the administration of ephedrine and fluids, hypotonia was successfully treated. The patient's state was stabilised, her clinical measurements returned to normal, and the procedure was continued. Her later course was uneventful. Blood gas analysis in post-anaesthesia care unit revealed mild, compensated metabolic acidosis. No electrolyte abnormalities were present.

Conclusion: Volatile anaesthetics and propofol decrease the systemic vascular resistance and cause vasodilatation. Our patient presented with hypotonic shock due to the redistribution of blood to the dilated venous malformation, which developed after the use of standard concentration of sevoflurane. Intravenous anaesthetics were administered during induction and might have increased that effect. Although we found no similar reports, we believe that patients with vast venous malformations can experience such complications after the use of volatile anaesthetics, especially in high concentrations.

Key words: venous malformation, child; general anaesthesia, complications, intraoperative hypotension; hypovolemic shock, symptoms

Anaesthesiology Intensive Therapy 2014, vol. 46, no 3, 175–179

Venous malformations are among the most common congenital vascular anomalies; their incidence is second only to capillary malformations (known also as post wine stains). Our Department of Paediatric Surgery and the Vascular Anomalies Outpatient Department address comprehensive diagnostic procedures and the treatment of these anomalies. Approximately 20–30 sclerotherapies of venous malformations are performed annually in children of all

ages. These procedures are carried out using 1–3% aethoxysclerol, which is a proven, safe and standard method of treatment for such lesions. Because of age and the invasiveness of this procedure, patients require general anaesthesia.

CASE REPORT

A 16-year-old girl, weighing 46 kg, was admitted to the Department of Paediatric Surgery for elective partial

sclerotherapy of an extensive venous malformation. The lesion spread over the left lower limb, the region of the pelvis minor, abdominal cavity and some of the thorax (Fig. 1) involving the internal structures; prior to the procedure, its extent was assessed using single-phase MRI without anaesthesia. The anomaly was found to start at the height of the left scapula angle and extend to the region below the pelvis. Anteriorly, it involved the subcutaneous tissue, straight and oblique abdominal muscles plus the regions below them, adhering directly to the intestinal loops. Posteriorly, the malformation involved the subcutaneous tissue, part of the extensor dorsi and the gluteus maximus muscle. Although MRI did not visualise the regions of the pelvis and lower limb, they were also known to have lesion involvement. Figures 2 and 3 present MRI scans of the regions that were performed later.

On the day preceding the procedure, the patient underwent standard preoperative assessment and was scheduled for general anaesthesia. Her history and information from the questionnaire that the parent completed did not reveal any medical problems apart from the underlying disease. Likewise, the family history was insignificant. In the past, the girl underwent several procedures under short-term intravenous general anaesthesia without intubation and these were uneventful; the only exception was arthroscopy performed in another hospital, which

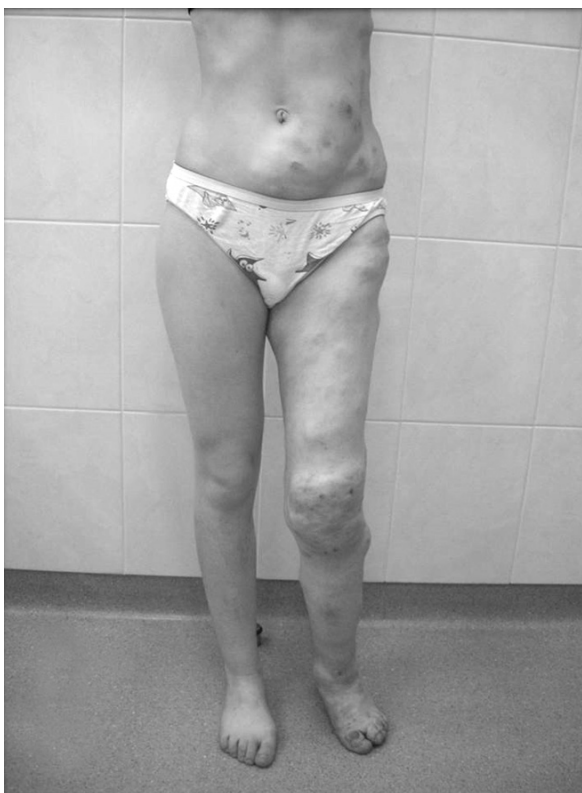

Figure 1. Venous malformation — external appearance

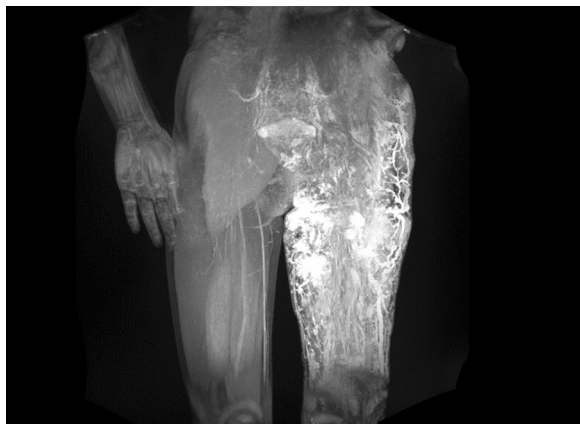


Figure 2. MRI scan of a vascular malformation

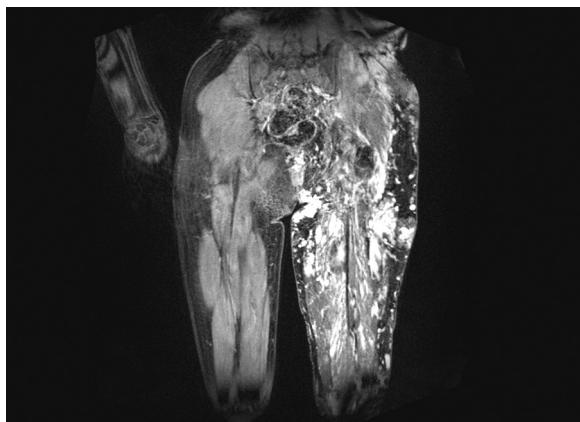


Figure 3. MRI scan with contrast

was discontinued due to abundant bleeding. The physical examination showed deformities of the hypogastrium, hip, lower limb and skin discolorations associated with the malformation.

On the procedure day, fasting was ensured. Thirty minutes before admission to the operating suite, the patient was premedicated (15 mg of midazolam, oral). In the operating theatre, standard monitoring was started with: ECG, SpO₂ and non-invasive blood pressure (NIBP). Two intravenous cannulas were inserted, one for general anaesthesia and another on the back within the region of the malformation to administer the sclerosing material. General anaesthesia was induced intravenously with atropine (0.4 mg), fentanyl (0.1 mg), propofol (100 mg), and atracurium (30 mg). Once the appropriate level of anaesthesia and muscle relaxation of the skeletal muscles was obtained, tracheal intubation was performed with a 6.5 mm endotracheal tube. The location of the tube was verified. After intubation, the following parameters were monitored: heart rate (HR) 125 min⁻¹, NIBP 120/75 mm Hg, SpO₂ 99%, and CO₂ pressure in E_tCO₂ 38 mm Hg (5 kPa).

The lungs were ventilated with an oxygen-air mixture, 1:2. The initial flow of fresh gases was 6 L min^{-1} and was reduced to 3 L min^{-1} . Anaesthesia was maintained with 2 vol% sevoflurane. The concentrations of the inspiratory and expiratory gases were monitored. The crystalloid infusion was initiated (500 mL of Ringer's solution) at a moderate rate. The patient was placed on the right side with her legs elevated up to 20° . During draping of the operating field, the skin and lips became pale. The SpO_2 reading was disturbed and irregular. The carotid pulse was poorly palpable, accelerated; there was no pulse on the peripheral vessels. The patient developed sinus tachycardia, 150 min^{-1} , without arrhythmias. Shortly, NIBP became undetectable and E_TCO_2 decreased to 32 mm Hg. Large violet tumours within the regions of the lower leg, thorax and abdomen were observed, which were significantly wider than before the procedure. Action was taken to restore suitable arterial pressure and to stabilise the patient's condition. The lungs were ventilated with pure oxygen with the flow of 6 L min^{-1} . The supply of sevoflurane was discontinued. Naloxone (0.4 mg) and ketamine (125 mg) (in fractionated doses) were administered. After the above interventions, the HR was found to be 150 min^{-1} and arterial pressure 85/50 mm Hg. Ephedrine, i.v. 15 mg in 5 mg doses was administered. The additional i.v. line was inserted. A quick infusion of 6% solution of hydroxyethylated starch was started (Voluven, Fresenius Kabi, Germany). Ten minutes after the initiation of resuscitation procedures, the arterial pressure increased to 145/90 mm Hg, heart rate stabilised below 130 min^{-1} , and E_TCO_2 increased to 38 mm Hg. Because the general condition was stabilised, the procedure was continued; phlebography and sclerotisation of the venous malformation of the back region using 2% aethoxysclerol (foam) were performed. Sevoflurane in a lower dose (1 vol%) was used for inhalational maintenance. The later course of the procedure was uneventful; NIBP was stable at the level of 105/65 mm Hg, HR 108 min^{-1} . Ninety minutes after the induction of anaesthesia, the patient was extubated, awoken and transferred to the PACU. The following was recommended: continuous monitoring of the general condition, HR, SpO_2 , NIBP, and body temperature and the additional infusion of 1000 mL of Ringer's solution. Blood gas analysis in the PACU revealed compensated metabolic acidosis — pH 7.34, BE -5.5 mmol L^{-1} , and HCO_3^- 20.2 mmol L^{-1} . The haematocrit was 28%, and there were no electrolyte or glycaemic disorders. The acid-base balance test was repeated in the evening and showed the following: pH 7.39, BE -4.5 mmol L^{-1} , and HCO_3^- 19.1 mmol L^{-1} . After haematological consultation and three successive uneventful days of hospitalisation, the girl was discharged home; follow-up in the vascular anomalies outpatient department was recommended in a month.

DISCUSSION

In the patient we anaesthetised, hypotonia was most likely caused by redistribution of blood from the systemic circulation to the venous malformation. The incident occurred immediately after the initiation of sevoflurane supply, which, together with its known vasodilating effect, must have caused this complication. The patient received earlier propofol and atracurium, which could have increased hypotension. Case reports regarding anaesthesia in patients with extensive vascular anomalies are extremely rare. Surgical and diagnostic procedures in such patients are a challenge to operators and anaesthesiologists. Vascular malformations are diverse with respect to their type and extent of structures involved. Therefore, patients have to be thoroughly evaluated individually; in many cases, various imaging and laboratory examinations are needed to anticipate possible complications and choose the optimal method of anaesthesia for each individual. Another problem is the coexistence of vascular anomalies with other disorders and defects, resulting in syndromes, e.g., Klippel-Trenaunay [1] or Sturge-Weber syndrome. In such cases, the method of anaesthesia is also determined by the accompanying diseases [2, 3]. Surgery-related complications in the form of haemorrhages (including massive ones) were described by Barbara and Wilson [4], who retrospectively analysed 134 general and 2 block anaesthetic procedures that were performed in 82 patients over the period of 8 years in the Mayo Clinic College of Medicine in Rochester (USA). The procedures were carried out in patients with the Klippel-Trenaunay syndrome (KTS). KTS is a rare congenital malformation; its incidence is 1:27,500 births. It consists of the triad of venous malformations or varicose veins, capillary malformations of neurovascular structures, and bony or soft tissue hypertrophy of the affected areas. The analysis considered procedures in patients who underwent operations due to the underlying diagnosis; the majority of patients were young Caucasians, ASA I or II. The major problems we observed were blood loss (33% of cases) with the mean volume of bleeding of $740 \pm 2739 \text{ mL}$. The range of the blood loss volumes was 20–18000 mL with a median 75 mL. A significant blood loss was found in 6 and massive loss in 2 patients. The use of a cuff for controlled ischemia did not statistically affect the losses. Moreover, there was no need for fluid therapy that was more intense than the standard one (except in cases with high blood loss). Although there are some similarities between the cases that were analysed by Barbara and Wilson and our case (e.g., the use of ketamine as the main anaesthetic), the key difference is the diagnosis. There is a strong analogy between the location as well as extent of angioma and KTS; however, the lack of KTS diagnosis in our patient does not allow us to treat those patients and our patient as the same. It seems that the distribution-related disorders

could have been caused by the opening of connections between malformations and the systemic circulation, which might have been induced by general anaesthetics. Differences in the disease picture and diagnosis in our patient might suggest the lack of such effects of anaesthetics in patients with KTS [4].

The Kasabach-Merritt syndrome (KMS), first described in 1940, is associated with large haemangiomas and thrombocytopenia. The latter is directly related to the presence of vascular anomaly. The mechanism of the development of these disorders is still discussed. Kawahara and colleagues [5] paid attention to the problems that occur during anaesthesia in patients diagnosed with this syndrome. One report presented a case of a 20-month-old girl with KMS who underwent the cryosurgical procedure to remove the angioma from her face. The case differed from ours in the diagnosis, treatment and location of angioma; therefore, the anticipated anaesthesiological difficulties were different (in lesions within the face difficulties related to maintaining patent airways, ventilation and intubation should mainly be considered). The authors did not observe any complications and the aim of the study was to observe the potential risks and preventive measures that have to be undertaken before anaesthetising the patient who is diagnosed with KMS. One of the risks mentioned was substantial enlargement of angioma resulting from changes in the patient's position. This factor seems to have been relevant in our case. The location and large size of vascular anomaly additionally caused systemic disturbances (shock and metabolic acidosis). In our case, we did not observe thrombocytopenia or clotting disturbances, which were described in the Kasabach-Merritt syndrome.

Volatile anaesthetics reduce the systemic vascular resistance in a dose-dependent manner, which is associated with their depressive effect on arterial blood pressure and can easily be observed during anaesthesia [6]. A similar effect is exerted by propofol [7] and the combination of both of these agents can have a synergistic effect, leading to the distribution of blood to pathological vascular regions through the previously closed connections. This can result in distributive hypotonia that is evidenced by changes in the size of vascular anomaly in our patient. Azma and co-workers [8], in their animal study, demonstrated the inhibitory effect of sevoflurane on the bradykinin-induced increased concentration of calcium ions, which in practice can be inhibition of the physiological reaction to hypotension. In another animal study, Yamaguchi and colleagues [9] showed the inhibitory effects of sevoflurane on constriction of the muscular layer due to the action of noradrenaline and fenylefrin (thus, the effects are dependent on stimulation of the alpha-adrenergic receptor).

In our patient, NIBP normalised, and the resuscitation procedures involved both the intravenous supply of ephed-

rine and temporary withdrawal of sevoflurane. The way vascular anomalies behave during anaesthesia requires further analysis, especially when the effects of sevoflurane are not explicit. Nakamura et al. and Yoshida and Okabe [10, 11] reported inhibitory effects of volatile anaesthetics on blood vessel relaxation dependent on the endothelium.

The authors from Toronto described circulatory collapse in an 11-year-old child with Klippel-Trenaunay-Weber syndrome and a large venous malformation of the left lower limb. Circulatory collapse occurred during sclerotisation with 40 mL of 83% ethanol solution performed under general anaesthesia with a laryngeal mask airway [12]. Based on the clinical course and ultrasound findings, including transoesophageal US, the patient was diagnosed with an acute incident of pulmonary hypertension with right ventricular failure, resulting in an increased alveolar to arterial gradient (PaO_2 80 mm Hg at supply of 100% O_2), mixed metabolic-respiratory acidosis and circulatory arrest. The differential diagnosis excluded pulmonary embolism, which is a rare complication of sclerotisation with ethanol. The trachea was intubated, and resuscitation led to quick return of spontaneous circulation. The complications in the present report were caused by the injection of ethanol. Nevertheless, this was the only incident that the authors observed during their many years of practice in the centre where approximately 100 sclerotherapies are performed annually. Considering this, the authors believe that the risk of such incidences is extremely low and there are no indications for routine invasive monitoring of circulatory functions. The authors did not describe the changes in the appearance or size of vascular malformation. Hypotension and shock in our patient were not caused by the injection of ethanol and occurred before the administration of the sclerosing material. The similar course of the complication inclines us to draw an additional conclusion. Each patient with vascular anomaly should be assessed individually to determine the grounds and indications for the invasive monitoring of circulatory functions and for endotracheal intubation as the most reliable method of maintaining a patent airway.

Patients with vascular anomalies are predisposed to various types of complications. Few publications address these perioperative problems, which is partially due to the rarity of diseases and partially due to the fact that critical events are a low percent of these problems; hence, the problem is extremely rare. However, the occurrence of complications in each case is life threatening and requires prompt resuscitation management. The starting point for further research can be the factor triggering the opening of connections between the patient's circulation and venous malformations, which do not infrequently have large sizes. Patients with venous malformations live without haemodynamic disorders or significant clotting impair-

ments for many years. The changes in the body positions, stress and minor injuries do not lead to the immediate reaction with a course that is similar to the one described by us. However, impairment of specific homeostasis initiates the cascade of life-threatening processes, which requires definite action. General anaesthesia and the use of anaesthetics that affect the cardio-vascular system seem to be a relevant risk factor. Modern volatile anaesthetics and the majority of intravenous anaesthetics reduce the systemic vascular resistance and arterial pressure. Their effects on the mechanisms dilating vessels are multi-directional and this reaction requires further analysis. According to many authors, patients with large venous malformations have "two circulations". Uncontrolled opening of their connections may be due to several overlapping factors, i.e., stress, hormonal reaction, injury or pharmacological agents, and can lead to unexpected and disastrous effects. The use of ketamine seems to be a beneficial alternative to propofol and volatile agents [13].

References:

1. *Servelle M*: Klippel and Trenaunay's syndrome. 786 operated cases. *Ann Surg* 1985; 201: 365–373.
2. *De Leon-Casasola OA, Lema MJ*: Anesthesia for patients with Sturge-Weber disease and Klippel-Trenaunay syndrome. *J Clin Anesth* 1991; 3: 409–413.
3. *Batra RK, Gulaya V, Madan R, Trikha A*: Anaesthesia and the Sturge-Weber syndrome. *Can J Anaesth* 1994; 41: 133–136.
4. *Barbara DW, Wilson JL*: Anesthesia for surgery related to Klippel-Trenaunay syndrome: a review of 136 anesthetics. *Anesth Analg* 2011; 113: 98–102.
5. *Kawahara M, Takeshita T, Akita S*: Anesthetic management of a patient with Kasabach-Merritt syndrome. *Anesth Prog* 1987; 34: 17–19.
6. *Eger II EJ, Eisenkraft JB, Weiskopf RB*: The pharmacology of inhaled anesthetics Healthcare Press Chicago 2002: 158–159.
7. *Pensado A, Molins N, Alvarez J*: Effects of propofol on mean arterial pressure and systemic vascular resistance during cardiopulmonary bypass. *Acta Anaesthesiol Scand* 1993; 37: 498–501.
8. *Az-ma T, Fujii K, Yuge O*: Inhibitory effect of sevoflurane on nitric oxide release from cultured endothelial cells. *Eur J Pharmacol* 1995; 289: 33–39.
9. *Yamaguchi A, Okabe E*: Effect of sevoflurane on the vascular reactivity of rabbit mesenteric artery. *Br J Anaesth* 1995; 74: 576–582.
10. *Nakamura K, Terasako K, Toda H et al.*: Mechanisms of inhibition of endothelium-dependent relaxation by halothane, isoflurane and sevoflurane. *Can J Anaesth* 1994; 41: 340–346.
11. *Yoshida K, Okabe E*: Selective impairment of endothelium-dependent relaxation by sevoflurane: oxygen free radicals participation. *Anesthesiology* 1992; 76: 440–447.
12. *Wong GA, Armstrong DC, Robertson JM*: Cardiovascular collapse during ethanol sclerotherapy in a pediatric patient. *Paediatr Anaesth* 2006; 16: 343–346.
13. *Oklü E, Bulutcu FS, Yalçın YH et al.*: Which anesthetic agent alters the hemodynamic status during pediatric catheterization? Comparison of propofol versus ketamine. *J Cardiothorac Vasc Anesth* 2003; 17: 686–90.

Corresponding author:

Dawid Wiszniewski, MD
M. Konopnicka Teaching Hospital No. 4
Sporna 36/50, 91–738 Łódź, Poland
e-mail: wiszniewski_dawid@o2.pl

Received: 25.04.2014

Accepted: 30.05.2014