

# Noninvasive ventilation in difficult endotracheal intubation: systematic and review analysis

Igor Barjaktarevic<sup>1</sup>, Antonio M. Esquinas<sup>2</sup>, Frances Mae West<sup>3</sup>, Jeffrey Albores<sup>4</sup>, David Berlin<sup>5</sup>

<sup>1</sup>*Division of Pulmonary and Critical Care Medicine, David Geffen School of Medicine at UCLA, Los Angeles, California, USA*

<sup>2</sup>*Intensive Care and Noninvasive Ventilatory Unit, Hospital Morales Meseguer, Murcia, Spain*

<sup>3</sup>*Division of Pulmonary and Critical Care Medicine, Sidney Kimmel Medical College, Thomas Jefferson University, Philadelphia, Pennsylvania, USA*

<sup>4</sup>*Advanced Pulmonology Associates, Self Medical Group, Greenwood, South Carolina, USA*

<sup>5</sup>*Division of Pulmonary and Critical Care Medicine, Weill Cornell Medical College, New York, New York, USA*

## Abstract

Noninvasive ventilation has been widely used in the management of acute respiratory failure in appropriate clinical settings. In addition to known benefit of alleviating the need for invasive mechanical ventilation, recent literature suggested its beneficial use in the process of endotracheal intubation.

Search of the PubMed database and manual review of selected articles investigating the methods and outcomes of endotracheal intubation in difficult airway due to hypoxemic respiratory failure and the role of noninvasive ventilation in this process.

Large randomized controlled studies focused on alternative approaches to endotracheal intubation in severe hypoxemic respiratory failure are largely missing but there are several retrospective cohort analysis and reports describing the novel technique describing the application of noninvasive ventilation during endotracheal intubation.

Noninvasive ventilation can be used as an adjunct intervention that may maintain oxygenation and ventilation, prevent significant hemodynamic instability and provide a pneumatic stent to maintain upper airway patency, thus reducing the risks of intubation-related complications.

Anaesthesiology Intensive Therapy 2017, vol. 49, no 4, 294–302

**Key words:** airway, difficult; endotracheal intubation, difficult; noninvasive ventilation; awake bronchoscopic intubation

Non-invasive positive pressure ventilation (NIV) has been validated in management of select patients with acute respiratory failure [1]. Failure of NIV and the need for transition to mechanical ventilation in this patient population can lead to severe complications. The use of NIV immediately before and during endotracheal intubation (ETI) may improve the safety in transitioning to invasive mechanical ventilation by a number of mechanisms. However, there is insufficient published data about the feasibility of the procedure and about possible impact of NIV maintenance throughout a difficult intubation scenario. We discuss and offer recommendations for the use of NIV during a predicted difficult intubation.

## THE ROLE OF NIV IN DIFFICULT INTUBATION

In critically ill patients, ETI is an integral part of life-supporting measures and is paradoxically associated with life threatening complications that are not infrequently encountered during a “difficult airway”. Difficult intubation, defined by multiple attempts to introduce an endotracheal tube, extended duration of procedures or necessity for multiple approaches and intubation devices, may lead to serious soft tissue damage and is the major cause of death and anoxic brain injury during anesthesia care [2]. The incidence of difficult intubation varies greatly depending on patient population, clinical settings, operator skills and level of preparedness for problems with airway management [3].

Traditionally, “difficult intubation” refers to the difficulty of glottic visualization and endotracheal tube placement during direct laryngoscopy. A broader definition, the “physiologic difficult airway” extends beyond anatomical concerns and takes into consideration the potential poor cardiopulmonary reserve encountered in cardiac surgery patients, as well as critically ill patients undergoing ETI [4]. Despite a technically easy laryngoscopy and endotracheal tube placement, hypoxemia, hypotension, severe acidosis, and right ventricular failure may be encountered in the peri-intubation period and contribute to significant morbidity. The combination of difficult laryngoscopy and endotracheal tube placement with poor physiologic reserve can lead to a catastrophic deterioration during ETI, a risk that increases with the number of intubation attempts. As a result, the rate of complications such as cardiac arrest, hypotension, and critical hypoxemia are much higher in critically ill patients than in anesthesia for elective surgery [5–11]. Bronchoscopic guidance after failed intubation or predicted difficult laryngoscopy is recommended by expert guidelines, and the lack of its availability and adequate operator skills are recognized as risk factors to complications of airway management [12, 13]. While there is a dearth of randomized controlled trials supporting the efficacy of bronchoscopic intubation in the intensive care unit, a recent retrospective cohort analysis imply its safety and feasibility [14].

The role of NIV as an alternative to invasive mechanical ventilation for acute respiratory failure has been a subject of multiple studies [15–17]. While NIV may be effective in preventing the need for ETI in certain clinical scenarios with severe hypoxemic respiratory failure, intubation after a failed trial of NIV is associated with death and other complications [15, 18, 19].

The use of NIV as a part of pre-oxygenation/ventilation strategy in preparation for ETI has been studied and shown to be beneficial [20–22]. Yet, the need to intubate the patient who has previously failed NIV or who is placed on NIV for the purpose of preoxygenation requires discontinuation of NIV. During this period when the NIV is discontinued but invasive ventilation has not yet been established, the patient is vulnerable to significant hypoxemia caused by derecruitment of lung dependent on extrinsic positive end expiratory pressure (PEEP) previously provided to maintain oxygenation. The extended beneficial effect on oxygenation may be expected if NIV is continued throughout the process of ETI with a nasal interface, which enables complete necessary instrumentation of the oral cavity and pharynx [23, 24].

### PHYSIOLOGIC BENEFITS OF NIV IN ENDOTRACHEAL INTUBATION

The benefits of NIV support during ETI are multi-factorial, and may culminate in increased patient safety during the procedure. Providing NIV support improves ventilation,

**Table 1.** Physiologic benefits of NIV during endotracheal intubation

Pre-oxygenation
Prevention of alveolar de-recruitment
Maintenance of gas exchange during apnea
Maintenance of upper airway patency
Reduction of hemodynamic alterations during ETI
Reduction of the level of respiratory distress prior to ETI

oxygenation, improves airway patency, and unmasks unstable hemodynamics prior to ETI (Table 1).

### VENTILATION

Patients undergoing elective surgery generally tolerate apnea during ETI for elective surgery. The rise in PaCO<sub>2</sub> during apnea is non-linear, but approximates 3–4 mm Hg min<sup>-1</sup>. The rate of PaCO<sub>2</sub> rise will be greater if the patient has increased metabolic rate due to a fever, tissue injury or systemic inflammation associated with acute illness. NIV can improve gas exchange during ETI by cyclically augmenting the trans-pulmonary pressure gradient to maintain alveolar ventilation. NIV can maintain satisfactory level of ventilation even during deep sedation as demonstrated in a case series of its application in procedural anesthesia [25]. In patients undergoing intubation during spontaneous breathing, NIV can theoretically decrease the work of breathing and improve ventilation by augmenting tidal volumes [26].

### OXYGENATION

Following induction and paralysis during rapid sequence intubation (RSI) the patient becomes apneic and the lungs recoil to the functional residual capacity (FRC). During this period, gas exchange continues as mixed venous blood continues to flow to the alveolar capillary bed and the FRC acts as the air reservoir supplying the circulation with oxygen. Both the volume of air at the FRC and its partial pressure of oxygen determine how quickly arterial desaturation occurs during apnea. The rate of total oxygen consumption in the tissues, as well as the magnitude and distribution of pulmonary blood flow also determine the time to desaturation. Pre-oxygenation of a spontaneously breathing patient with high supplemental FiO<sub>2</sub> is effective to lengthen the time before desaturation in patients presenting for elective surgery [27]. However, these standard methods of pre-oxygenation are ineffective in critically ill patients due to physiologic derangements. In this population, atelectasis commonly reduces FRC and increases the right-to-left shunt fraction. Low cardiac output state results in reduced pulmonary blood flow. Moreover, the high tissue oxygen demand during acute critical illness further compromises the balance between oxygen delivery and

consumption. All of these factors can contribute to hypoxia during ETI. Patients with an oxygen saturation less than or equal to 93% during pre-oxygenation uniformly desaturate to <90% during intubation [28].

In critically ill patients, NIV may offer benefits over standard pre-oxygenation techniques. Through positive pressure, NIV can recruit atelectatic lung, thereby increasing the volume of the FRC and reducing the shunt fraction. Oxygen consumption may also decrease as a result of the reduced work of breathing during spontaneous ventilation with NIV. Moreover, by increasing alveolar ventilation, NIV can increase the alveolar oxygen content by CO<sub>2</sub> and nitrogen washout. Theoretically, this can raise mixed venous oxygen saturation and improve the effectiveness of pre-oxygenation. The recruitment and benefit of pre-oxygenation with NIV can continue even after ETI is completed [20].

NIV has also been shown to provide adequate oxygenation and prevent desaturation during ETI. NIV can be used in these settings as a form of apneic oxygenation. If the airway is patent, any high flow oxygen device can promote the replacement of alveolar gas that flows into the alveolar capillary beds through bulk flow. Therefore, high-flow nasal cannula (HFNC) can be used as an apneic oxygenation method, leading to reduced prevalence of severe hypoxemia during intubation of critically ill patients with mild-to-moderate hypoxemia in a pilot study [29, 30]. However, two randomized controlled trials found that HFNC during emergent ETI of patients with severe hypoxemia did not prevent desaturation [31, 32]. It is possible that high flow devices have limited benefits as a form of apneic oxygenation during ETI if airway patency is not maintained with maneuvers such as jaw thrust and because they provide little, if any, lung recruitment and ventilation. In addition to alveolar recruitment, PEEP via a nasal NIV interface during intubation can theoretically maintain airway patency. These possible benefits of PEEP are especially important in a patient undergoing RSI during which supine positioning, apnea, reduced FRC, and atelectasis promote desaturation during ETI.

De-nitrogenation is maximized with positive pressure ventilation due to alveolar recruitment. Pre-oxygenation with high FiO<sub>2</sub> effectively removes inert nitrogen from the alveolar air spaces and blood. Unfortunately, nitrogen normally acts as a pneumatic splint to maintain the patency of unstable lung units. Without nitrogen, the partial pressure of gas is very low in mixed venous blood returning to capillaries. Therefore, de-nitrogenation increases the gas pressure gradient from alveoli compared with alveolar capillary blood. After de-nitrogenation, oxygen will rapidly flow from the alveoli into the capillaries leading to alveolar instability and atelectasis — a physiological phenomenon also demonstrated on CT imaging [33]. PEEP facilitates

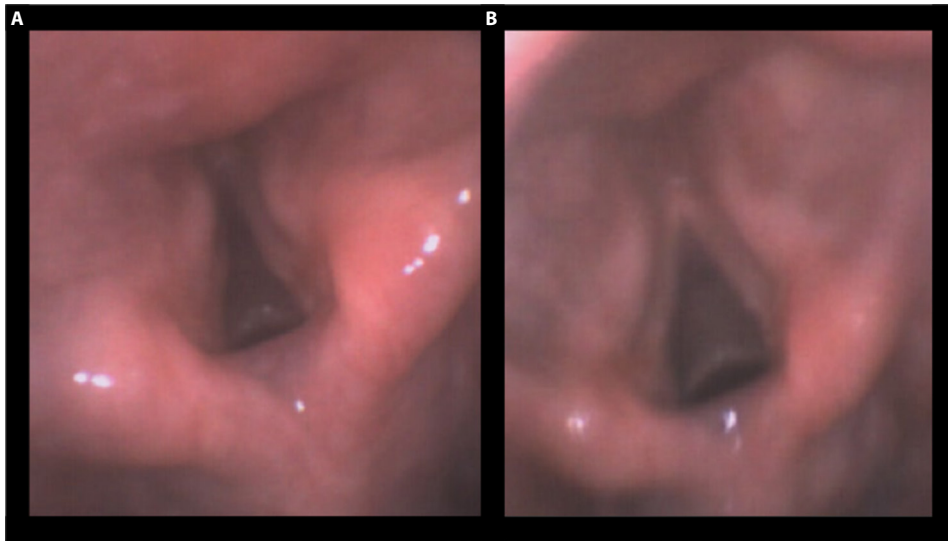
alveolar recruitment, which can counteract the adverse effect of de-nitrogenation on alveolar recruitment and improve oxygenation. Additionally, nasal NIV during ETI can also aid oxygenation by partially supporting ventilation. The principle that oxygenation can be supported by nasal NIV throughout the process of intubation has been demonstrated for both bronchoscopic [34] and direct laryngoscopic ETI [24].

### **MAINTAINING UPPER AIRWAY PATENCY**

The velopharynx corresponds to the upper airway at the level of the soft palate, which is the most common site of airway obstruction in adults during both sleep and deep sedation. Anesthesia reduces the tone of the pharyngeal muscle dilators, and blunts protective arousal reflexes, thus narrowing the antero-posterior diameter of the airway. These effects are more pronounced in the supine position. This pattern of airway obstruction in anesthesia is very similar to obstructive sleep apnea in which negative intraluminal pressures in the spontaneously breathing patient potentiate airway collapse. In both situations, the application of nasal NIV can relieve airway obstruction with the application of CPAP. Nasal NIV can displace the soft palate anteriorly, which partially prevents the leakage of air out of the oropharynx. Incremental increases in positive airway pressures leads to a linear increase in airway area at a given airway level. Therefore, nasal NIV can serve as a pneumatic splint for the oropharynx during anesthesia. Pilot data demonstrate that this splinting can aid ETI. Nasal NIV with a continuous positive airway pressure of 20 cm H<sub>2</sub>O has been utilized to relieve upper airway obstruction during fiberoptic-guided nasotracheal intubation in a morbidly obese patient [35]. The splinting effect on the glottis with PEEP has been visualized in a healthy patient on non-invasive BiPAP ventilation with an EPAP of 8 cm H<sub>2</sub>O (Fig. 1). Although CPAP titration is utilized to relieve upper airway obstruction in obstructive sleep apnea, it is not known if a similar titration is required to provide pneumatic stenting of the glottis, or if a common minimum PEEP will suffice.

### **HEMODYNAMIC EFFECT**

Critically ill patients frequently experience significant hemodynamic alterations during ETI [8]. The hemodynamic effects of NIV during ETI are complex and their net effect can be difficult to predict in critically ill patients. NIV decreases both venous return to the heart and to a lesser extent, left ventricular afterload. This can effectively treat pulmonary edema from left ventricular failure and can facilitate safe ETI [36]. However, positive pressure ventilation frequently decreases cardiac output by decreasing the pressure gradient for venous return to the heart [37]. Additionally, hyperinflation from positive pressure can elevate pulmonary vascular



**Figure 1.** Comparison of the effect of normal breathing at the atmospheric pressure and NIV with BiPAP on the size and anatomy of hypopharynx and upper airways at the end of exhalation of healthy subject. **A** — negative pressure ventilation; **B** — BiPAP 16/8 cm H<sub>2</sub>O. Notice the splinting effect of BiPAP on the anatomy of hypopharynx

resistance and impede right ventricular output [38, 39]. Therefore, NIV can also worsen hemodynamics before or during ETI. Nevertheless, adequate and timely NIV use prior to ETI can offer early manifestation of hemodynamic consequences of positive pressure ventilation, allowing clinicians to treat the hemodynamic instability prior to sedation and anesthesia required for ETI. In a population of hypoxemic patients with poor right ventricular function treated with NIV prior to decision to intubate, continuation of NIV throughout the intubation may prevent hemodynamic changes related to transition from positive pressure ventilation (NIV) to negative pressure ventilation in the period of ETI and subsequent change from negative to positive pressure ventilation upon ETI [40].

#### **PATIENT COMFORT AND SAFETY**

In cases of severe respiratory failure, clinicians may be forced to perform urgent ETI before a proper airway assessment and management strategy can be formulated. In carefully selected situations, clinicians may use NIV to temporarily stabilize the patient while preparing the patient and equipment for safer ETI. Using NIV can abrogate the need for bag-mask ventilation (BVM), a potentially very uncomfortable procedure in a suboptimally sedated patient. The transition to BVM itself carries a risk of difficult ventilation, supine positioning and reduction of FRC, and possibly the inability to provide adequate oxygenation in patients with severe hypoxemic respiratory failure. Avoidance of BVM and continuation of NIV during ETI, especially in cases of bronchoscopic awake intubation, can potentially improve safety in such high-risk cases.

#### **PROCEDURE(S)**

There are several case reports and series that have been published which describe different ETI procedural techniques with a variety of NIV interfaces. The full-face mask interface can increase the delivered FIO<sub>2</sub> by limiting entrained air through the mouth which is common with the nasal interface. Moreover, full-face masks limit air leak through the mouth and can help maintain PEEP. However, in contrast to the nasal interface, full-face masks can contribute to upper airway obstruction in anesthetized supine patients by displacing the tongue posteriorly. As discussed above, nasal interfaces can stent the upper airway open and allow oral ETI without possible effect on tongue displacement.

Effectiveness of alveolar ventilation can vary depending on the patient's underlying pulmonary mechanics and the mode of NIV. Patients with non-compliant respiratory systems require higher levels of inspiratory pressure to deliver adequate tidal volumes. In this scenario, bilevel positive airway pressure (BiPAP) may be a superior mode. Patients with upper airway obstruction may require higher levels of end-expiratory pressure, so CPAP may be appropriate. If the patient is anesthetized, a mode with a set respiratory rate is recommended such as spontaneous/timed (S/T) mode. Regardless of the mode and settings, it is essential to monitor the patient on NIV and determine if the patient has adequate exhaled tidal volume and minute ventilation. In the absence of appropriate ventilation, the clinician should evaluate for airway obstruction, excessive leak, dynamic hyperinflation and inadequate driving pressure.

Outlined (Table 2) are the multiple airway strategies and ETI techniques that exist in the literature with NIV support. Aoyama *et al.* [41] performed fiberoptic-guided intubation

**Table 2.** Noninvasive ventilation techniques during endotracheal intubation

Author/Report	Procedural Technique	Findings
Aoyama <i>et al.</i> [41]. Positive pressure ventilation during fiberoptic intubation: comparison of the laryngeal mask airway, intubating laryngeal mask and endoscopy mask techniques	LMA or ILM inserted followed by insertion of tracheal tube into the tube of the LMA or ILM. Fiberoptic intubation performed with application of 20 cm H <sub>2</sub> O PPV through the tracheal tube. In the endoscopy (Patil) mask group, fiberoptic intubation performed while PPV maintained through the Patil mask	Greater ventilation during intubation with endoscopy mask than that with the LMA or ILM, but gastric insufflation was more frequent
Nafeh <i>et al.</i> [42]. Fiberoptic tracheal intubation through a Boussignac valve to maintain continuous oxygenation during intubation in severely obese patients: 11 cases	PEEP of 7.5 cm H <sub>2</sub> O obtained by a Boussignac valve powered by an oxygen flow of 30 L min <sup>-1</sup> affixed to a face-mask. Fiberoptic orotracheal intubation carried out through the Boussignac valve. General anesthesia accomplished when the tracheal tube had advanced to the glottis	None of the severely obese patients experienced decrease in oxygen saturation during this intubation technique
Rothfleisch <i>et al.</i> [35]. Facilitation of Fiberoptic Nasotracheal Intubation in a Morbidly Obese Patient by Simultaneous Use of Nasal CPAP	Emergent nasotracheal intubation using a fiberoptic bronchoscope with simultaneous application of CPAP 20 cm H <sub>2</sub> O to the contralateral nares using a nasal pillow that helped maintain ventilation and facilitated visualization of anatomic landmarks and translaryngeal passage of the bronchoscope	Fiberoptic video images of this patient's hypopharynx demonstrate the pharyngeal splinting action of nasal CPAP
Wong <i>et al.</i> [43]. Awake bronchoscopic intubation through an air-Q with the application of BIPAP	BIPAP initially applied for preoxygenation. Single-use air-Q orally inserted in sitting position and BIPAP was applied to the air-Q, followed by the insertion of endotracheal tube via the air-Q to 14 cm. ETT cuff inflated, and BIPAP connected to the ETT through a flexible connector with a bronchoscope port. Bronchoscope advanced through the flexible connector past the well-visualized glottis to the carina. ETT cuff deflated and advanced over the bronchoscope into the trachea. ETT cuff reinflated after confirmation of position.	Oxygen saturation 97% was maintained during the intubation process
Barjaktarevic <i>et al.</i> [34]. Bronchoscopic Intubation During Continuous Nasal Positive Pressure Ventilation in the Treatment of Hypoxemic Respiratory Failure	BIPAP delivered via nasal interface. Oral airway covered with 5% lidocaine ointment placed in the oropharynx. After sufficient topical anesthesia, intubating (Williams) airway placed in the oropharynx. ETT inserted into the Williams airway and bronchoscope placed through the ETT and into the distal trachea. ETT inserted into the trachea using the bronchoscope as the stylet. Bronchoscope withdrawn slowly to allow visualization of the tip of the endotracheal tube in good position within the trachea. Nasal NIV then removed (Figs 2, 3)	All 10 patients intubated in the first attempt Hypotension was the most frequent complication. Mean decrease in oxyhemoglobin saturation during the procedure was 4.7 + 3.1
Cataldo <i>et al.</i> [24]. The Nasal Oxygenation and Ventilation of the Airway (NOVA) Technique, a New and Safer Approach to Airway Management in the Critically Ill Patient	The NOVA technique utilized nasal NIV during direct laryngoscopy and intubation (Fig. 4)	Potential elimination of apneic period during intubation

BIPAP — bilevel positive airway pressure; CPAP — continuous positive airway pressure; ETT — endotracheal tube; ILM — intubating laryngeal mask; LMA — laryngeal mask airway; NIV — noninvasive ventilation; PEEP — positive end-expiratory pressure; PPV — positive-pressure ventilation

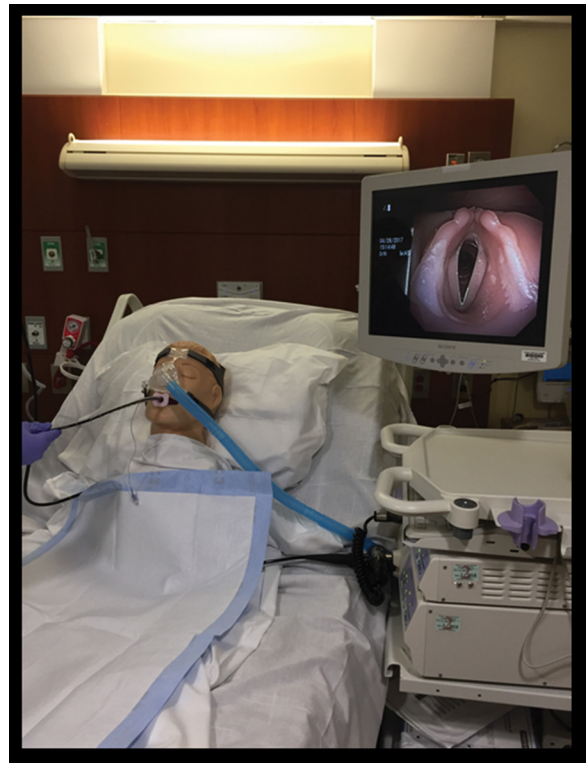during positive pressure ventilation with a laryngeal mask airway (LMA), intubating laryngeal mask (ILM) or endoscopy mask (Patil mask). In this technique, LMA or ILM were initially inserted followed by fiberoptic intubation and passage of the tracheal tube via the LMA or ILM during positive pressure ventilation of 20 cm H<sub>2</sub>O through the tracheal tube. In the Patil mask group, fiberoptic intubation was performed while positive pressure ventilation was maintained through the Patil mask. The ventilation was better during intubation with the endoscopy mask than that with the LMA or ILM, but gastric insufflation was more frequent. This study was performed in patients prior to elective surgery and may not accurately reflect conditions in critically ill patients.

Nafeh *et al.* [42] performed fiberoptic-guided intubation in 11 severely obese patients while maintaining CPAP with a Boussignac valve (Vygon Medical, Montgomeryville, PA, USA) during the entire intubation procedure. The patients received oral and topical nasopharyngeal anesthetic and were placed in half-sitting position. PEEP of 7.5 cm H<sub>2</sub>O was delivered by a Boussignac valve powered by an oxygen flow of 30 L min<sup>-1</sup> affixed to a face-mask. After initiation of remifentanyl, fiberoptic orotracheal intubation was carried out through the Boussignac valve. General anesthesia was accomplished when the tracheal tube had advanced to the glottis. No patient had oxygen desaturation. This study was also done in elective surgical patients. Rothfleisch *et al.* [35] emergently

nasotracheally intubated a morbidly obese patient using a fiberoptic bronchoscope with simultaneous application of CPAP 20 cm H<sub>2</sub>O to the contralateral nare using a nasal pillow that helped maintain ventilation. The CPAP treatment also facilitated visualization of the anatomic landmarks and translaryngeal passage of the bronchoscope. Wong *et al.* [43] performed an awake bronchoscopic intubation in an obese patient with a difficult airway and acute respiratory failure. BIPAP was initially applied for pre-oxygenation given repeated oxygen desaturation. A single-use air-Q LMA was orally inserted in the sitting position and BIPAP was applied to the air-Q, followed by the insertion of endotracheal tube via the air-Q. The endotracheal tube cuff was inflated, and BIPAP was connected to the endotracheal tube through a flexible connector with a bronchoscope port. A bronchoscope was advanced through the flexible connector past the well-visualized glottis to the carina. The endotracheal tube cuff was deflated and advanced over the bronchoscope into the trachea. The endotracheal tube cuff was reinflated after confirmation of position. Oxygen saturation of 97% was maintained during the intubation procedure. Cataldo *et al.* [24] applied Nasal Oxygenation and Ventilation of the Airway (NOVA) technique with nasal mask NIV during rapid sequence intubation and direct laryngoscopy in critically sick patients requiring ETI. The authors propose that partially ventilating a paralyzed patient during rapid sequence intubation may eliminate the apneic period altogether. Barjaktarevic *et al.* [34] performed bronchoscopic-guided intubation with NIV in ten patients with acute hypoxemic respiratory failure (Fig. 2). The patients had progressive hypoxemic respiratory failure despite NIV and subsequently required rescue ETI. BIPAP, initially delivered via a full-face mask, was later changed to nasal interface in anticipation of rescue orotracheal intubation. Patients were ventilated with nasal NIV and placed in a semi-recumbent position. An oral airway covered with 5% lidocaine ointment was placed in the oropharynx. After sufficient topical anesthesia, an intubating Williams airway was placed in the oropharynx and systemic sedation was administered. The endotracheal tube was inserted into the Williams airway and the bronchoscope was placed through the endotracheal tube and into the distal trachea. The endotracheal tube was then passed into the trachea using the bronchoscope as the stylet (Fig. 3).

### LIMITATIONS OF NIV DURING ETI

Airway management plans can be more complex with the application of NIV and require additional experience with a defined protocol. The equipment costs include the use of the ventilator, the disposable airway interface, ventilator tubing, and the personnel to set up the equipment. Adding unfamiliar equipment and procedures can distract clinicians during emergency airway management. Using




**Figure 2.** Demonstration of the concept of awake bronchoscopic intubation supported with continuous nasal positive pressure ventilation

NIV during ETI may require more to provide proper topical anesthesia, and may not be feasible when there is insufficient time to properly prepare the patient and equipment. Many patients do not tolerate NIV due to patient-ventilator asynchrony. Appropriate patient selection as well as careful titration and adjustment of NIV settings (mode, interface, pressure titration) are essential.

Contraindications to NIV support during ETI include blood and excessive secretions in the airway, vomiting, or a high risk of aspiration. While the use of antisialagogue such as glycopyrrolate or, less often, atropine or scopolamine may decrease mucus and salivary secretions, this complication is more likely if the patient has impaired gastric emptying. The risk exists with an insufflation pressure of greater than 20 cm H<sub>2</sub>O, which can be easily obtained using manual ventilation, thus limiting the absolute positive pressure value, and can decrease the risk of aspiration [20, 44]. There is not sufficient evidence to support the routine use of a nasogastric tube for gastric decompression. Most complications of NIV are local and related to the tightly fitting mask such as local skin damage, mask leak, and eye irritation.

### CONCLUSIONS

NIV is a well-validated treatment in selected patients with acute respiratory failure. NIV can also be used to sup-



**Figure 3.** Recommended setup for NIV-supported awake bronchoscopic intubation: **1.** The cooperative patient is placed in semi-recumbent position in order to minimize distress. **2.** The nasal mask is used as an interface for the application of NIV (if previously on a different interface, change to nasal mask is recommended during the process of preparation for ETI). **3.** The posterior oropharynx is anesthetized with 4% atomized lidocaine solution with the goal of coating the glottis and the piriform recesses. **4.** Lidocaine ointment 5% coats Williams airway prior to its insertion in the mouth; slow release of ointment facilitates supra-glottic local anesthesia and attenuates gag and cough reflexes. The Williams intubating airway comes in two sizes, size 10 being able to accommodate ETT size 7.5–8.5). A bronchoscope is used for visualization of vocal cords, endotracheal local anesthetic delivery and as a stylet over which the ETT is passed into the trachea as well as a confirmatory tool for adequacy of ETT placement. Additional lidocaine 1–2% solution is used as a local anesthetic both for supra- and infra-glottic anesthesia delivered via the working channel of the bronchoscope under direct visualization. **7.** A lubricated endotracheal tube is loaded into the Williams airway prior to the intubation, both are placed into patient’s mouth and bronchoscope is then inserted into the ETT. The endotracheal tube is then passed over the bronchoscopic stylet into the trachea. Difficulty with passing the tube through the larynx can be mitigated by rotating the tube 90 degrees counter-clockwise. Selecting a bronchoscope that minimizes the space between the outer diameter of the bronchoscope and the inner diameter of the tube also reduces this hazard

port the patient during ETI. As an emerging concept, new data is needed to define the best clinical situations for its use. Maintenance of NIV in patients who are considered treatment failures undergoing ETI may reduce complications associated with discontinuation of the therapy during transition to invasive mechanical ventilation. Using nasal NIV during endotracheal intubation may be beneficial to provide a pneumatic stent for the upper airway and/or maintenance of gas exchange during ETI.

**Experts’ recommendation:** Bronchoscopic awake intubation has been recommended in the past as an alternative approach to direct laryngoscopy for obese patients, patients with cranial or facial anatomy, neck or spinal mobility limita-

tions, patients undergoing nasal intubation or patients who cannot lay flat, but little has been known about the use of this concept in severely hypoxemic or hemodynamically unstable patients. Use of nasal NIV before and during ETI of such patients in a carefully selected population of patients may help maintain adequate oxygenation and ventilation, lung recruitment and patency of upper airways. Furthermore, achieving optimal topical anesthesia and minimizing systemic sedation reduces the negative hemodynamic impact of anesthetics and paralytics during transition from negative to positive pressure ventilation. Bronchoscopic skills, non-urgent settings and the use of intubating airways play a significant role in the feasibility and efficacy of this technique.

**Table 3.** Indications, contraindications and recommended set-up for NIV-supported awake bronchoscopic intubation

Indication	Contraindications	Ventilatory support	Intubation equipment	Sedation
Hypoxemic respiratory failure with inability to maintain SpO <sub>2</sub> > 92 without non-invasive ventilation and positive pressure	Large oral secretions, hemoptysis, emesis	NIV via Bi-level PAP	5% lidocaine ointment covering the intubation airway, placed in patient's mouth 5–10 minutes before the ETI	Low dose combination of benzodiazepine (usually midazolam, 1–4 mg <i>i.v.</i> ) and opiate (usually fentanyl 25–150 mcg <i>i.v.</i> )
	Uncontrolled gag or inability to tolerate the presence of Williams airway	NIV via Continuous PAP		
Hypercapnic respiratory failure	Agitated or noncooperative patient	For severely hypoxemic patients, a non-rebreather mask can be used for additional preoxygenation while Williams airway in the mouth	1–2% lidocaine solution, if possible delivered by atomizer	Ketamine (20 mg <i>i.v.</i> push, followed by 10 mg <i>i.v.</i> Q <sub>2</sub> min) or drip if less emergent (0.1 mg min <sup>-1</sup> )
		Emergent airway necessity with respiratory arrest	Williams intubating airway: Size 9 allows for ETT #7.5 and size 10 allows for ETT #8.0	Precedex drip (usually 1 mcg kg <sup>-1</sup> bolus followed by 0.2 mcg kg <sup>-1</sup> h <sup>-1</sup> )
Anticipation of difficult airway in a patient who is may clinically benefit or is currently treated with NIV			Endotracheal tube, standard. May need to transiently remove connector to the ventilator so Williams airway can be taken out after the intubation	Low-dose propofol (usually < 50 mg, can be combined with ketamine)
			Bronchoscope - video or fiberoptic or disposable intubating Ambuscope	

## ACKNOWLEDGEMENTS

1. Source of funding: none.
2. Conflict of interest: none.

## References:

1. Nava S, Hill N. Non-invasive ventilation in acute respiratory failure. *Lancet*. 2009; 374(9685): 250–259, doi: [10.1016/S0140-6736\(09\)60496-7](https://doi.org/10.1016/S0140-6736(09)60496-7), indexed in Pubmed: [19616722](https://pubmed.ncbi.nlm.nih.gov/19616722/).
2. Henderson JJ, Popat MT, Latto IP, et al. Difficult Airway Society guidelines for management of the unanticipated difficult intubation. *Anaesthesia*. 2012; 67(4): 452–452, doi: [10.1111/j.1365-2044.2012.07129.x](https://doi.org/10.1111/j.1365-2044.2012.07129.x).
3. De Jong A, Molinari N, Terzi N, et al. AzuRéa Network for the Frida-Réa Study Group. Early identification of patients at risk for difficult intubation in the intensive care unit: development and validation of the MACOCHA score in a multicenter cohort study. *Am J Respir Crit Care Med*. 2013; 187(8): 832–839, doi: [10.1164/rccm.201210-1851OC](https://doi.org/10.1164/rccm.201210-1851OC), indexed in Pubmed: [23348979](https://pubmed.ncbi.nlm.nih.gov/23348979/).
4. Choudhury A, Gupta N, Magoon R, et al. Airway management of the cardiac surgical patients: Current perspective. *Ann Card Anaesth*. 2017; 20(Supplement): S26–S35, doi: [10.4103/0971-9784.197794](https://doi.org/10.4103/0971-9784.197794), indexed in Pubmed: [28074820](https://pubmed.ncbi.nlm.nih.gov/28074820/).
5. Mort TC. Preoxygenation in critically ill patients requiring emergency tracheal intubation. *Crit Care Med*. 2005; 33(11): 2672–2675, indexed in Pubmed: [16276196](https://pubmed.ncbi.nlm.nih.gov/16276196/).
6. Mort TC. Complications of emergency tracheal intubation: hemodynamic alterations—part I. *J Intensive Care Med*. 2007; 22(3): 157–165, doi: [10.1177/0885066607299525](https://doi.org/10.1177/0885066607299525), indexed in Pubmed: [17562739](https://pubmed.ncbi.nlm.nih.gov/17562739/).
7. Mort TC. Complications of emergency tracheal intubation: immediate airway-related consequences: part II. *J Intensive Care Med*. 2007; 22(4): 208–215, doi: [10.1177/0885066607301359](https://doi.org/10.1177/0885066607301359), indexed in Pubmed: [17712056](https://pubmed.ncbi.nlm.nih.gov/17712056/).
8. Perbet S, De Jong A, Delmas J, et al. Incidence of and risk factors for severe cardiovascular collapse after endotracheal intubation in the ICU: a multicenter observational study. *Crit Care*. 2015; 19: 257, doi: [10.1186/s13054-015-0975-9](https://doi.org/10.1186/s13054-015-0975-9), indexed in Pubmed: [26084896](https://pubmed.ncbi.nlm.nih.gov/26084896/).
9. Schwartz D, Matthay M, Cohen N. Death and Other Complications of Emergency Airway Management in Critically Ill Adults. *Anesthesiology*. 1995; 82(2): 367–376, doi: [10.1097/0000542-199502000-00007](https://doi.org/10.1097/0000542-199502000-00007).
10. Franklin C, Samuel J, Hu TC. Life-threatening hypotension associated with emergency intubation and the initiation of mechanical ventilation. *The American Journal of Emergency Medicine*. 1994; 12(4): 425–428, doi: [10.1016/0735-6757\(94\)90053-1](https://doi.org/10.1016/0735-6757(94)90053-1).
11. Davis D, Dunford J, Poste J, et al. The Impact of Hypoxia and Hyperventilation on Outcome after Paramedic Rapid Sequence Intubation of Severely Head-Injured Patients. *J Trauma*. 2004; 57(1): 1–10, doi: [10.1097/01.ta.0000135503.71684.c8](https://doi.org/10.1097/01.ta.0000135503.71684.c8).
12. Cook TM, Woodall N, Harper J, et al. Fourth National Audit Project. Major complications of airway management in the UK: results of the Fourth National Audit Project of the Royal College of Anaesthetists and the Difficult Airway Society. Part 2: intensive care and emergency departments. *Br J Anaesth*. 2011; 106(5): 632–642, doi: [10.1093/bja/aeo059](https://doi.org/10.1093/bja/aeo059), indexed in Pubmed: [21447489](https://pubmed.ncbi.nlm.nih.gov/21447489/).
13. Apfelbaum JL, Hagberg CA, Caplan RA, et al. Practice guidelines for management of the difficult airway: an updated report by the American Society of Anesthesiologists Task Force on Management of the Difficult Airway. *Anesthesiology*. 2013; 118(2): 251–270, doi: [10.1097/ALN.0b013e31827773b2](https://doi.org/10.1097/ALN.0b013e31827773b2), indexed in Pubmed: [23364566](https://pubmed.ncbi.nlm.nih.gov/23364566/).
14. Ma KC, Chung A, Aronson KI, et al. Bronchoscopic intubation is an effective airway strategy in critically ill patients. *J Crit Care*. 2017; 38: 92–96, doi: [10.1016/j.jcrc.2016.10.022](https://doi.org/10.1016/j.jcrc.2016.10.022), indexed in Pubmed: [27875775](https://pubmed.ncbi.nlm.nih.gov/27875775/).
15. Antonelli M, Conti G, Rocco M, et al. A comparison of noninvasive positive-pressure ventilation and conventional mechanical ventilation in patients with acute respiratory failure. *N Engl J Med*. 1998; 339(7): 429–435, doi: [10.1056/NEJM199808133390703](https://doi.org/10.1056/NEJM199808133390703), indexed in Pubmed: [9700176](https://pubmed.ncbi.nlm.nih.gov/9700176/).
16. British Thoracic Society Standards of Care Committee. Non-invasive ventilation in acute respiratory failure. *Thorax*. 2002; 57(3): 192–211, indexed in Pubmed: [11867822](https://pubmed.ncbi.nlm.nih.gov/11867822/).
17. Hess DR. Noninvasive ventilation for acute respiratory failure. *Respir Care*. 2013; 58(6): 950–972, doi: [10.4187/respcare.02319](https://doi.org/10.4187/respcare.02319), indexed in Pubmed: [23709194](https://pubmed.ncbi.nlm.nih.gov/23709194/).
18. Antonelli M, Conti G, Moro ML, et al. Predictors of failure of noninvasive positive pressure ventilation in patients with acute hypoxemic respiratory failure: a multi-center study. *Intensive Care Med*. 2001; 27(11): 1718–1728, doi: [10.1007/s00134-001-1114-4](https://doi.org/10.1007/s00134-001-1114-4), indexed in Pubmed: [11810114](https://pubmed.ncbi.nlm.nih.gov/11810114/).
19. Mosier JM, Sakles JC, Whitmore SP, et al. Failed noninvasive positive-pressure ventilation is associated with an increased risk of intubation-related complications. *Ann Intensive Care*. 2015; 5: 4, doi: [10.1186/s13613-015-0044-1](https://doi.org/10.1186/s13613-015-0044-1), indexed in Pubmed: [25852964](https://pubmed.ncbi.nlm.nih.gov/25852964/).
20. Baillard C, Fosse JP, Sebbane M, et al. Noninvasive ventilation improves preoxygenation before intubation of hypoxic patients. *Am J Respir Crit*



- Care Med. 2006; 174(2): 171–177, doi: [10.1164/rccm.200509-1507OC](https://doi.org/10.1164/rccm.200509-1507OC), indexed in Pubmed: [16627862](https://pubmed.ncbi.nlm.nih.gov/16627862/).
21. Futier E, Constantin JM, Pelosi P, et al. Noninvasive ventilation and alveolar recruitment maneuver improve respiratory function during and after intubation of morbidly obese patients: a randomized controlled study. *Anesthesiology*. 2011; 114(6): 1354–1363, doi: [10.1097/ALN.0b013e31821811ba](https://doi.org/10.1097/ALN.0b013e31821811ba), indexed in Pubmed: [21478734](https://pubmed.ncbi.nlm.nih.gov/21478734/).
  22. Sreejit MS, Ramkumar V. Effect of positive airway pressure during pre-oxygenation and induction of anaesthesia upon safe duration of apnoea. *Indian J Anaesth*. 2015; 59(4): 216–221, doi: [10.4103/0019-5049.154998](https://doi.org/10.4103/0019-5049.154998), indexed in Pubmed: [25937647](https://pubmed.ncbi.nlm.nih.gov/25937647/).
  23. Barjaktarevic I, Berlin D. Bronchoscopic intubation during continuous nasal positive pressure ventilation in the treatment of hypoxemic respiratory failure. *J Intensive Care Med*. 2015; 30(3): 161–166, doi: [10.1177/0885066613510680](https://doi.org/10.1177/0885066613510680), indexed in Pubmed: [24243561](https://pubmed.ncbi.nlm.nih.gov/24243561/).
  24. Cataldo S, Pedro M, Lokhandawala B. The nasal oxygenation and ventilation of the airway (NOVA) technique, a new and safer approach to airway management in the critically ill patient. *SOJ Anesthesiol Pain Manag*. 2014; 1(2): 1–4.
  25. Strayer RJ, Caputo ND. Noninvasive ventilation during procedural sedation in the ED: a case series. *Am J Emerg Med*. 2015; 33(1): 116–120, doi: [10.1016/j.ajem.2014.10.023](https://doi.org/10.1016/j.ajem.2014.10.023), indexed in Pubmed: [25455053](https://pubmed.ncbi.nlm.nih.gov/25455053/).
  26. Kallet RH, Diaz JV. The physiologic effects of noninvasive ventilation. *Respir Care*. 2009; 54(1): 102–115, indexed in Pubmed: [19111110](https://pubmed.ncbi.nlm.nih.gov/19111110/).
  27. Weingart SD, Levitan RM. Preoxygenation and prevention of desaturation during emergency airway management. *Ann Emerg Med*. 2012; 59(3): 165–75.e1, doi: [10.1016/j.annemergmed.2011.10.002](https://doi.org/10.1016/j.annemergmed.2011.10.002), indexed in Pubmed: [22050948](https://pubmed.ncbi.nlm.nih.gov/22050948/).
  28. Davis DP, Hwang JQ, Dunford JV. Rate of decline in oxygen saturation at various pulse oximetry values with prehospital rapid sequence intubation. *Prehosp Emerg Care*. 2008; 12(1): 46–51, doi: [10.1080/10903120701710470](https://doi.org/10.1080/10903120701710470), indexed in Pubmed: [18189177](https://pubmed.ncbi.nlm.nih.gov/18189177/).
  29. Miguel-Montanes R, Hajage D, Messika J, et al. Use of high-flow nasal cannula oxygen therapy to prevent desaturation during tracheal intubation of intensive care patients with mild-to-moderate hypoxemia. *Crit Care Med*. 2015; 43(3): 574–583, doi: [10.1097/CCM.0000000000000743](https://doi.org/10.1097/CCM.0000000000000743), indexed in Pubmed: [25479117](https://pubmed.ncbi.nlm.nih.gov/25479117/).
  30. Esquinas AM, Berlin DA, Barjaktarevic I. Oxygenation during high-flow nasal cannula in tracheal intubation: do we know the “red desaturation line”? *Crit Care Med*. 2015; 43(6): e215–e216, doi: [10.1097/CCM.0000000000000919](https://doi.org/10.1097/CCM.0000000000000919), indexed in Pubmed: [25978180](https://pubmed.ncbi.nlm.nih.gov/25978180/).
  31. Vourc’h M, Asfar P, Volteau C, et al. High-flow nasal cannula oxygen during endotracheal intubation in hypoxemic patients: a randomized controlled clinical trial. *Intensive Care Med*. 2015; 41(9): 1538–1548, doi: [10.1007/s00134-015-3796-z](https://doi.org/10.1007/s00134-015-3796-z), indexed in Pubmed: [25869405](https://pubmed.ncbi.nlm.nih.gov/25869405/).
  32. Semler MW, Janz DR, Lentz RJ, et al. FELLOW Investigators, Pragmatic Critical Care Research Group. Randomized Trial of Apneic Oxygenation during Endotracheal Intubation of the Critically Ill. *Am J Respir Crit Care Med*. 2016; 193(3): 273–280, doi: [10.1164/rccm.201507-1294OC](https://doi.org/10.1164/rccm.201507-1294OC), indexed in Pubmed: [26426458](https://pubmed.ncbi.nlm.nih.gov/26426458/).
  33. Edmark L, Kostova-Aherdan K, Enlund M, et al. Optimal oxygen concentration during induction of general anesthesia. *Anesthesiology*. 2003; 98(1): 28–33, indexed in Pubmed: [12502975](https://pubmed.ncbi.nlm.nih.gov/12502975/).
  34. Barjaktarevic I, Berlin D. Bronchoscopic intubation during continuous nasal positive pressure ventilation in the treatment of hypoxemic respiratory failure. *J Intensive Care Med*. 2015; 30(3): 161–166, doi: [10.1177/0885066613510680](https://doi.org/10.1177/0885066613510680), indexed in Pubmed: [24243561](https://pubmed.ncbi.nlm.nih.gov/24243561/).
  35. Rothfleisch R, Davis LL, Kuebel DA, et al. Facilitation of fiberoptic nasotracheal intubation in a morbidly obese patient by simultaneous use of nasal CPAP. *Chest*. 1994; 106(1): 287–288, indexed in Pubmed: [8020289](https://pubmed.ncbi.nlm.nih.gov/8020289/).
  36. Buda AJ, Pinsky MR, Ingels NB, et al. Effect of intrathoracic pressure on left ventricular performance. *N Engl J Med*. 1979; 301(9): 453–459, doi: [10.1056/NEJM197908303010901](https://doi.org/10.1056/NEJM197908303010901), indexed in Pubmed: [460363](https://pubmed.ncbi.nlm.nih.gov/460363/).
  37. van den Berg PCM, Jansen JRC, Pinsky MR. Effect of positive pressure on venous return in volume-loaded cardiac surgical patients. *J Appl Physiol* (1985). 2002; 92(3): 1223–1231, doi: [10.1152/jappphysiol.00487.2001](https://doi.org/10.1152/jappphysiol.00487.2001), indexed in Pubmed: [11842062](https://pubmed.ncbi.nlm.nih.gov/11842062/).
  38. Roos A, Thomas LJ, Nagel EL, et al. Pulmonary vascular resistance as determined by lung inflation and vascular pressures. *J Appl Physiol*. 1961; 16: 77–84, indexed in Pubmed: [13743179](https://pubmed.ncbi.nlm.nih.gov/13743179/).
  39. Vieillard-Baron A, Bouferrache K, Charron C. Right ventricular function evaluation in acute respiratory distress syndrome: back to the future. *Crit Care Med*. 2010; 38(9): 1909–1910, doi: [10.1097/CCM.0b013e3181ee404f](https://doi.org/10.1097/CCM.0b013e3181ee404f), indexed in Pubmed: [20724889](https://pubmed.ncbi.nlm.nih.gov/20724889/).
  40. Johannes J, Berlin DA, Patel P, et al. A technique of awake bronchoscopic endotracheal intubation for respiratory failure in patients with right heart failure and pulmonary hypertension. *Crit Care Med*. 2017; 45(9): e980–e984, doi: [10.1097/CCM.0000000000002586](https://doi.org/10.1097/CCM.0000000000002586).
  41. Aoyama K, Yasunaga E, Takenaka I, et al. Positive pressure ventilation during fiberoptic intubation: comparison of the laryngeal mask airway, intubating laryngeal mask and endoscopy mask techniques. *Br J Anaesth*. 2002; 88(2): 246–254, doi: [10.1093/bja/88.2.246](https://doi.org/10.1093/bja/88.2.246).
  42. Nafeh S, Danielou E, Calenda E, et al. Fiberoptic tracheal intubation through a Boussignac valve to maintain continuous oxygenation during intubation in severely obese patients: 11 cases. *J Clin Anesth*. 2011; 23(4): 345–346, doi: [10.1016/j.jclinane.2010.08.015](https://doi.org/10.1016/j.jclinane.2010.08.015), indexed in Pubmed: [21663825](https://pubmed.ncbi.nlm.nih.gov/21663825/).
  43. Wong DT, Wang J, Venkatraghavan L. Awake bronchoscopic intubation through an air-Q® with the application of BIPAP. *Can J Anaesth*. 2012; 59(9): 915–916, doi: [10.1007/s12630-012-9741-5](https://doi.org/10.1007/s12630-012-9741-5), indexed in Pubmed: [22723082](https://pubmed.ncbi.nlm.nih.gov/22723082/).
  44. Ho-Tai LM, Devitt JH, Noel AG, et al. Gas leak and gastric insufflation during controlled ventilation: face mask versus laryngeal mask airway. *Can J Anaesth*. 1998; 45(3): 206–211, doi: [10.1007/BF03012903](https://doi.org/10.1007/BF03012903), indexed in Pubmed: [9579256](https://pubmed.ncbi.nlm.nih.gov/9579256/).

**Corresponding author:**

Igor Barjaktarevic, MD PhD  
 Division of Pulmonary and Critical Care  
 David Geffen School of Medicine at UCLA  
 Los Angeles, California, USA  
 e-mail: [ibarjaktarevic@mednet.ucla.edu](mailto:ibarjaktarevic@mednet.ucla.edu)

Received: 12.07.2017

Accepted: 20.08.2017