

# Tapia's syndrome after arthroscopic shoulder stabilisation under general anaesthesia and LMA

\*Jacek Wadelek, Julia Kolbusz, Piotr Orlicz, Andrzej Staniaszek

Department of Anaesthesiology and Intensive Therapy, Central Teaching Hospital MSWiA in Warsaw

## Abstract

**Background.** Anaesthetic complications, albeit rare, still occur and may be severe and unanticipated, with significant morbidity.

Extracranial ipsilateral palsy of the recurrent laryngeal and the hypoglossal nerves is known as the Tapia's syndrome. Damage to these nerves may result from displacement of the head during mask ventilation, endotracheal intubation, bronchoscopy or the use of a laryngeal mask airway (LMA). We describe unilateral paralysis of the muscles of the tongue and ipsilateral vocal cord due to a lesion of cranial nerves X and XII that occurred following LMA anaesthesia combined with plexus block.

**Case report.** A 57-year-old man with a rupture of the right shoulder underwent arthroscopic shoulder stabilisation and internal fixation. General anaesthesia with a LMA was combined with an interscalene plexus block. After induction with propofol and fentanyl, a LMA was inserted with some difficulty without muscle relaxation. The cuff was inflated with 30 mL of air and further volumes of air until a "just-seal" pressure was obtained. The anaesthesia was maintained with sevoflurane in oxygen/air. The procedure was carried out in a semi-supine position with the head inclined slightly forward, and the upper body slightly elevated. Surgery lasted 55 min and anaesthesia 70 min. After surgery, the patient quickly regained consciousness and the LMA was removed when he was responding to commands and was able to fully open his mouth.

During the immediate postoperative period, the patient's voice was hoarse but he breathed without difficulty. The following day, he developed dysphagia and slurred speech; on examination, paralysis of the left side of the tongue was found. The diagnosis of an acute injury to the hypoglossal and laryngeal recurrent nerves was made and the patient was transferred to the neurology clinic for further treatment.

**Conclusions.** This rare complication reminds us not only of the importance of positioning during anaesthesia and surgery, but also of the need for careful and correct airway management. It could be probably prevented by careful insertion of an appropriate size LMA, and the use of low intracuff pressures and/or volumes.

**Key words:** complications, general anaesthesia, Tapia's syndrome, surgery, orthopaedic

Anestezjol Intens Ter 2012; 44: 31-34

Safe general anaesthesia requires effective methods of restoration and maintenance of the airway and lung ventilation. In recent years various supra-glottic devices were introduced, commonly used for short-term general anaesthesia. The most popular is the laryngeal mask airway (LMA), which provides efficient airway patency without endangering patients for laryngoscopy- and endotracheal intubation-related complications. The laryngeal masks have become so popular amongst anaesthesiologists that they are routinely used in millions of patients

[1]. Compared to endotracheal intubation, the risk of complications associated with this method is lower yet some side effects are likely to develop, particularly in cases of difficult airway. The most common complaint is postoperative sore throat affecting about 10-40% of patients [2]. According to some literature data, some more severe complications are also observed, e.g. nerve injuries [3].

The aim of the report is to describe a case of unilateral paralysis of the hypoglossal and recurrent

laryngeal nerves, using the laryngeal mask in a patient undergoing arthroscopic shoulder stabilisation under general anaesthesia.

#### CASE REPORT

A 57-year-old man was diagnosed with the impingement syndrome caused by a fall onto the outstretched upper limb. After the orthopaedic examination the patient was scheduled for arthroscopic acromioplasty of the right shoulder joint. The preoperative anaesthetic visit revealed only moderate arterial hypertension, nicotine use and slight overweight (BMI 31.6; height: 176 cm; body weight 98 kg). Since this kind of surgery is very painful and the pain maintains during the immediate postoperative period, the combined anaesthesia was decided, i.e. the brachial plexus block and general anaesthesia with a laryngeal mask.

In the operating room, standard monitoring of basic vital functions was initiated (ECG, SpO<sub>2</sub>, SAP/DAP) and the patient was intravenously premedicated with midazolam, 3.5 mg. Firstly, block anaesthesia was performed from the lower interscalene access by identifying the brachial plexus using nerves stimulation. The block was provided after administration of 30 mL 0.375% of bupivacaine. The block was followed by general anaesthesia induced with propofol 2 mg kg<sup>-1</sup> thiopentone 2 mg kg<sup>-1</sup> and fentanyl 2 mg kg<sup>-1</sup>. The classic laryngeal mask no. 4 was used for airway instrumentation, whose cuff was filled with 30 mL of air. However, the airways were not tightened thus the mask was repositioned and the cuff filled with additional 3 mL of air, which provided the tightness of the system. During the anaesthesia maintenance, sevoflurane up to 2.5% was used in the mixture of O<sub>2</sub> and air, with spontaneous breathing preserved; moreover, fentanyl, 2 mg kg<sup>-1</sup> was given in a bolus.

The patient was placed in the semi-supine position; his head was stabilised and the upper limb immobilized with a traction. The procedure lasted 55 min and was uneventful. After the completion of general anaesthesia, the laryngeal mask was removed from the airway. The anaesthesia time was 70 min.

On the surgery day, in the recovery room, the patient had hoarseness without breathing difficulties. On the first postoperative day, the patient additionally complained of numbness of half of the tongue and slight deviation of the tongue to the unaffected side. There were no haematomas, oedema or tongue injuries. Considering the unclear aetiology of the motor-sensory disturbances affecting hypoglossal and recurrent laryngeal nerves, further diagnostic procedures were undertaken. The neurological examination showed the tongue deviation to the right, lowering of the left palatine arch, dysphagia and hoarseness (damaged cranial nerves X and XII). MRI of the head revealed the smooth-contoured lesion, 31x17x54 mm, on the posterior oral part of the pharyngeal wall, at the tongue base, which was probably located submucosally (Fig. 1). The lesion was posteriorly adjacent to the vascular bundle of cervical nerves, and separated from the medial pterygoid muscle by the thin margin of fatty tissue; the

posterior pharyngeal wall was bulged at the lesion level. The MRI scan suggested a benign submucosal focal lesion. The laryngological examination disclosed impaired mobility of the right vocal fold. The middle throat was punctured at the level of lesion and revealed the blood and blood clots. The symptomatic treatment applied during the next days improved the patient's condition; the majority of neurologic symptoms subsided after several months. During the final laryngological examination, the asymptomatic lowered palatoglossal fold was the only change observed.

#### DISCUSSION

Damage to the vagus and sublingual hypoglossal nerves, known as the Tapia's syndrome (hemiplegia palatopharyngolaryngea) was first described in 1905 in toreadors who sustained the injuries to the neck posterior to the mandible angle. In the majority of cases, the syndrome is caused by carcinoma, inflammation or pharyngeal injuries. In anaesthesiology, this complication is rarely observed [4, 5]. Its main manifestations include paralysis of the larynx (the vocal fold is situated medially, which causes hoarseness), unilateral paralysis of the soft palate, and deviation of the tongue to the unaffected side.

The occurrence of the syndrome after general anaesthesia with the laryngeal mask is believed to result from neuropraxia of both nerves due to pressure damage caused by the mask filled cuff. Other potential causes suggested are difficulties in insertion of the mask to the larynx, time of leaving it in the glottal space and forced positioning of the patient. Moreover, the relation between the damage to the hypoglossal, glossopharyngeal and recurrent laryngeal nerves and the use of a laryngeal

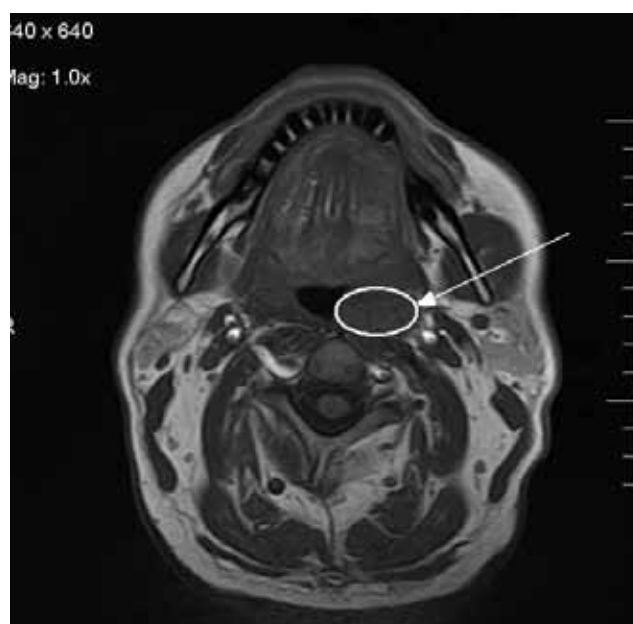


Fig. 1. MRI scan of the head. Haematoma at the tongue base, located on the posterior wall of the nasopharynx on the left (arrow)

mask was demonstrated [6, 7, 8, 9]. Additionally, the cases of Tapia's syndrome were observed as a result of general anaesthesia and endotracheal intubation [10, 11]. In such cases, the likely mechanism of injury is the pressure damage to the anterior recurrent laryngeal nerve branch between the cuff and the posterior part of the thyroid cartilage. Furthermore, isolated uni- and bilateral injuries to the hypoglossal nerve caused by damage to the lateral tongue base were noted during routine oral tracheal intubation with the Macintosh blade in patients with their heads deflected and pharynx setonage [12]. The Tapia's syndrome was also observed after shoulder surgery in the forced reclining position, resulting from the pressure of the endotracheal tube on the nerve after head repositioning [13]. Finally, uni- and bilateral injuries to vocal cords were also reported after endotracheal intubation [13].

In our case of Tapia's syndrome, the following mechanisms of nerve damage were considered: pressure of the mask cuff on the nerve crossing and deflected position of the head resulting in the tension of laterally located anatomical structures. The hypoglossal nerve is located on the most lateral eminence of the transverse process of C<sub>1</sub> and crosses with the vagus nerve [14]. If the deflection is excessive, the nerves can be strained and press the eminence. Nevertheless, the most likely cause of damage to cranial nerves related to the laryngeal mask is pressure neuropraxia when the filled cuff presses the nerves. The highest risks of the pressure on the hypoglossal nerve are observed at its crossing with the hyoid bone and the recurrent laryngeal nerve after its entrance to the larynx where it runs deeply on the lateral border of the interior sphincter muscle. The damage to the hypoglossal nerve is usually manifested by dysphagia whereas recurrent nerve injuries are associated with hoarseness and inspiratory wheezing.

The commonest causes of mechanical injuries include too small sizes of the laryngeal mask and the use of N<sub>2</sub>O for general anaesthesia. When a too small mask is used the frequency of changes in its primary position in the airway increases and the cuff tends to be overfilled with air to provide the tightness of the system. The manoeuvres to ensure airway patency increase the risk of injuries, which was the case in our patient. Although the haematoma in the pharyngeal space was not directly responsible for the symptoms observed (it was located on the side opposite to the manifested neurological symptoms), its development might indicate the damaging effects of the too small mask applied. This led to the development of the haematoma on one side of the pharyngeal cavity and injuries to the nerves on the opposite side. As far as N<sub>2</sub>O is concerned, it quickly diffuses to the interior of the cuff; its increased volume and pressure exerted on the surrounding tissues were of no importance as the agent was not used in our case. However, there were some factors, which might have contributed to mechanical injuries to the upper airway tissues, including the nerves passing near the laryngeal mask. The procedure was carried out in the

semi-supine position with the head stabilised, which might have caused tension and pulling of the structures of the nasopharyngeal and oral cavity.

The perioperative symptoms of peripheral damage to cerebral nerves develop within 48 postoperative hours and subside spontaneously over weeks or months. The injuries to the hypoglossal and recurrent laryngeal nerves after general anaesthesia are rare; when the described clinical symptoms are noticed, the presence of such complications should be considered. To avoid them, the mask should be most properly inserted, its size suitable chosen and recommended volumes of cuff filling followed, not to mention the stable head position during anaesthesia and surgery [15]. To reduce the incidence of injuries to the upper airway when the laryngeal mask is used, the pressure in the air-filled cuff should be measured manometrically and kept below 44 mm Hg (5.9 kPa), which is considered the upper safe limit [3]. The air volume depends on the mask size and its size on the patient's body weight.

#### REFERENCES

1. Rosenblatt W, Ovassapian A, Eige S: Use of the laryngeal mask airway in the United States: a randomized survey of ASA members. *Anesthesiology* 1998; 89: A575.
2. Dingley J, Whitehead MJ, Wareham K: A comparative study of the incidence of sore throat with the laryngeal mask airway. *Anaesthesia* 1994; 49: 251-254.
3. Seet E, Yousaf F, Gupta S, Subramanyam R, Wong DT, Chung F: Use of manometry for laryngeal mask airway reduces postoperative pharyngolaryngeal adverse events: a prospective, randomized trial. *Anesthesiology* 2010;112: 652-657.
4. Schoenberg BS, Massey EW: Tapia's Syndrome. The erratic evolution of an eponym. *Arch Neurol* 1979; 36: 257-260.
5. Boğa I, Aktas S: Treatment, classification, and review of Tapia syndrome. *J Craniofac Surg* 2010; 21: 278-280.
6. Fidelel FJ, Schroeder TH: Cranial nerve injuries from a laryngeal mask airway. *Eur J Anaesthesiol* 2009; 26: 980-981.
7. Bruce IA, Ellis R, Kay NJ: Nerve injury and the laryngeal mask airway. *J Laryngol Otol* 2004;118: 899-901.
8. Endo K, Okabe Y, Maruyama Y, Tsukatani T, Furukawa M: Bilateral vocal cord paralysis caused by laryngeal mask airway. *Am J Otolaryngol* 2007; 28: 126-129.
9. Chan TV, Grillone G: Vocal cord paralysis after laryngeal mask airway ventilation. *Laryngoscope* 2005;115: 1436-1439.
10. Cinar SO, Seven H, Cinar U, Turgut S: Isolated bilateral paralysis of the hypoglossal and recurrent laryngeal nerves (Bilateral Tapia's syndrome) after transoral intubation for general anaesthesia. *Acta Anaesthesiol Scand* 2005; 49: 98-99.
11. Yavuzer R, Basterizi Y, Ozkose Z, Demir Y, Yilmaz M, Ceylan A: Tapia's Syndrome following septorhinoplasty. *Aesth Plast Surg* 2004; 28: 208-211.
12. Barsoum W, Mayerson J, Bell, Gordon R: Cranial nerve palsy as a complication of operative traction. *Spine* 1999; 24: 585-586.

13. *Boisseau N, Rabarijaona H, Grimaud D, Raucoules-Aimè M*:  
Tapia's Syndrome following shoulder surgery. *Br J Anaesth*  
2002; 88: 869-870.
14. *Rubio-Nazabal E, Marey-Lopez J, Lopez-Facal S, Alvare-  
Perez B, Martinez-Figueroa A, Rey del Corral P*: Isolated  
bilateral paralysis of the hypoglossal nerve after transoral  
intubation for general anesthesia. *Anesthesiology* 2002;  
96: 245-247.
15. *Brimacombe J, Berry A*: The laryngeal mask airway –  
anatomical and physiological implications. *Acta Anaesthesiol  
Scand* 1996; 40: 201-209.

received: 06.01.2011

accepted: 23.07.2011

address:

\*Jacek Wadełek

Klinika Anestezjologii i Intensywnej Terapii

CSK MSWiA w Warszawie

ul. Wołoska 137, 02-507 Warszawa

tel.: 22 508 14 52

e-mail: WAD\_jack@poczta.fm