

# Autoimmune disorders in the course of primary immunodeficiency

JERZY ŚWIERKOT<sup>1</sup>, ALEKSANDRA LEWANDOWICZ-USZYŃSKA<sup>2</sup>

<sup>1</sup>Department of Rheumatology, Medical University of Wrocław, Poland; <sup>2</sup>Department of Propedeutic Pediatrics, Children's Clinic of Immunology and Rheumatology, Medical University of Wrocław, Poland

## Abstract

Primary antibody deficiencies have variable autoimmune manifestations. Immunodeficiency and autoimmunity seem to be on opposite sides of clinical immune response, but in reality they are frequently related and can coexist. The most common hypogammaglobulinemias are IgA deficiency, X-linked agammaglobulinemia, and common variable immunodeficiency (CVID). The most common autoimmune disorders are autoimmune hematological disease, autoimmune diseases of the gastrointestinal tract, autoimmune endocrine diseases, and autoimmune rheumatic diseases. Autoimmune manifestations in patients with hypogammaglobulinemias are due to dysregulation of the physiological homostatic mechanisms of the immune system. A variety of autoimmune disorders may dominate the clinical picture of primary immunodeficiency so that the underlying immunodeficiency is overlooked. For early detection and appropriate treatment, autoimmune disease should be suspected in patients with immunodeficiency. The basis of treatment for primary immunodeficiencies is immunoglobulin replacement for antibody deficiency syndromes (other than selective IgA deficiency) and the prevention and aggressive treatment of infections.

**Key words:** common variable immunodeficiency, IgA deficiency, X-linked agammaglobulinemia, autoimmune disorders.

(Centr Eur J Immunol 2007; 32 (1): 27-33)

## Introduction

Primary hypogammaglobulinemia is a heterogeneous group of immunoglobulin deficiencies. The spectrum of antibody deficiencies is broad, ranging from the most severe type of antibody deficiency with total absence of B cells and serum Ig to patients who have a selective antibody deficiency with normal serum Ig. The most common hypogammaglobulinemias are IgA deficiency, X-linked agammaglobulinemia, and common variable immunodeficiency (CVID).

Patients with primary hypogammaglobulinemias display a variety of clinical signs and symptoms. Recurrent pneumonia, bronchitis, and maxilar sinusitis are the most common symptoms before diagnosis. Immunodeficiency and autoimmunity seem to be on opposite sides of clinical immune response, but in reality they are frequently related and can coexist. Many immune deficiency syndromes, mainly humoral defects, are associated with autoimmune disorders (figure 1).

Autoimmune manifestations in patients with hypogammaglobulinemias are due to dysregulation of the physiological homostatic mechanisms of the immune system. There are many ways by which immunodeficiency may lead to autoimmune disorders.

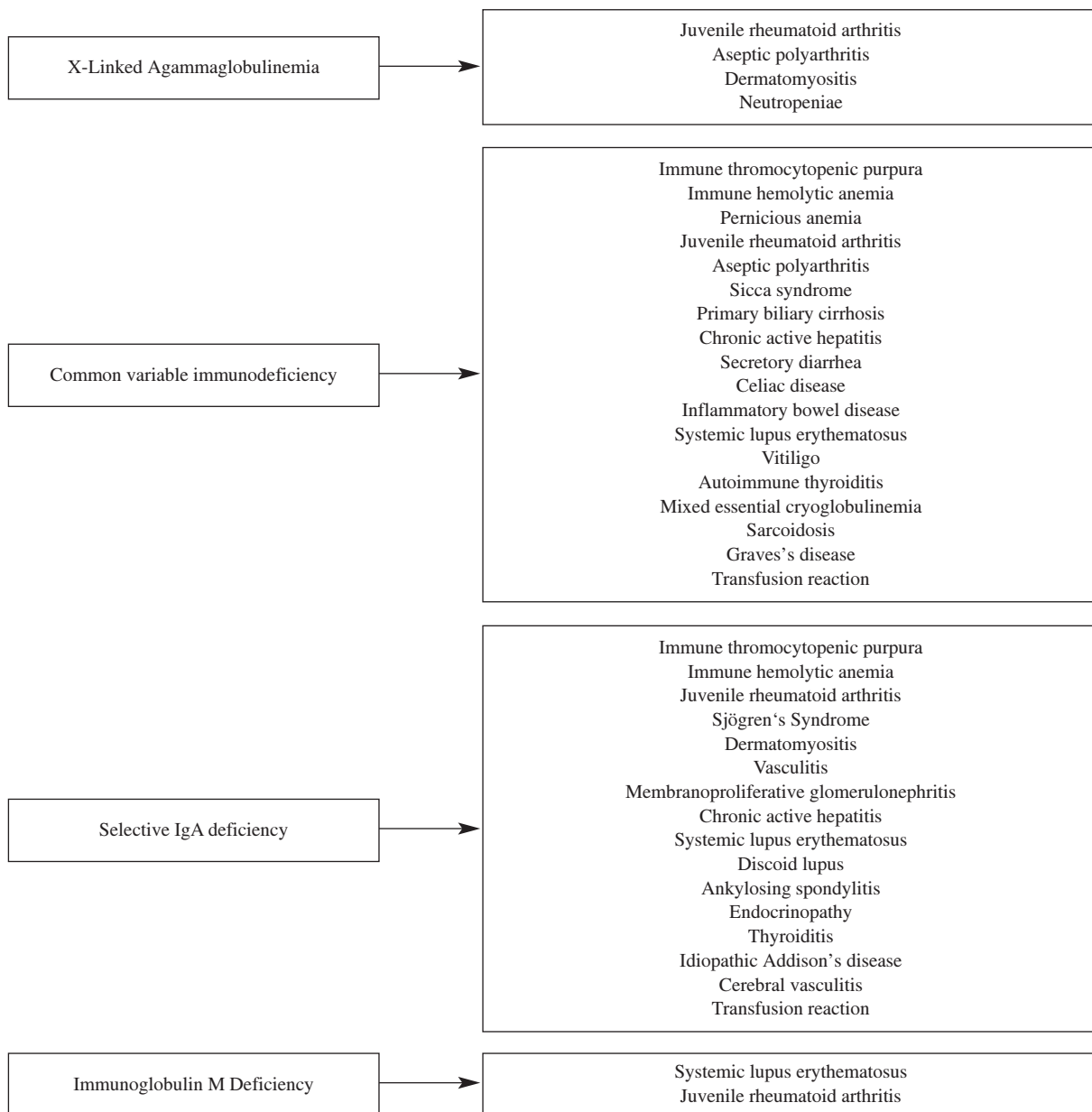
### 1. Persistent antigen stimulation

Continuous foreign antigen stimulation is the main pathogenic mechanism for autoimmunity in immunodeficiency. In these patients, the defective immune system cannot eradicate microbial and viral pathogens, which leads to increased chronic inflammatory response, and autoimmunity.

Primary immune defect → persisting opportunistic infection → suboptimal, chronic immune response → bystander tissue damage „autoimmunity” [1].

### 2. Immune dysregulation

• IL-2 deficiency in mice and humans is associated with autoimmune disease and in many immunodeficiencies there



**Fig. 1.** Autoimmune disorders which are often accompanied to immunodeficiency

is impaired production of IL-2 or poor IL-2 signaling. IL-2 is also very important in the production of CD4+ CD25+ regulatory T cells (this is important in maintaining tolerance),

- impaired expression of cell surface molecules on T cells such as CD40 ligand molecule → failure of B-cell maturation,
- decreased production of intracellular protein tyrosine kinase, and cytokines (IL-2, IFN- $\gamma$ ),
- suppressor T cells promote the growth of autonomous autoimmune clones,

- T-cell abnormalities: decreased T-cell proliferation to mitogens and antigens, reduced generation of antigen-specific memory T cells [2-4].

3. Recurrent tissue damage

4. Defective clearance of immune complexes

- impaired phagocytosis associated with failure to clear apoptotic cells or immune complexes (complement deficiencies) [2].

5. Genetic predisposition - patients with CVID may be genetically predisposed to autoimmune diseases; a putative

CVID gene has been proposed to lie within or near the MHC class III region on chromosome 6.

The most common autoimmune disorders are thrombocytopenic purpura (ITP) and autoimmune hemolytic anemia (AHA). Cytopenias are particularly common in antibody defects (CVID, selective IgA deficiency: SIgAD) [5, 6].

Sarmiento et al. [7] demonstrated the frequency of autoimmune disorders in 152 patients with primary antibody deficiencies. They were found in 35 patients (23%). Autoimmune diseases were more frequent in CVID patients (37.1%) than in those with selective IgA deficiency (25.5%) or selective IgG subclass deficiency (12.5%). Thirty-seven percent of autoimmune episodes occurred prior to the diagnosis of primary antibody deficiency. Autoimmune hematological disease was found in 14 patients (9.2%), autoimmune diseases of the gastrointestinal tract in 8 (5.3%), autoimmune endocrine diseases in 6 (3.9%), autoimmune rheumatic diseases in 6 (3.9%) and vitiligo in 4. Sixteen patients (10.5%) had autoantibodies without clinical data of an autoimmune disease.

A number of rheumatic manifestations have been reported in patients with primary hypogammaglobulinemia: arthralgia, septic arthritis (particularly due to mycoplasma), aseptic monoarthritis, symmetrical polyarthritis, and arthritis associated with concomitant autoimmune diseases [8, 9]. Polyarthritis can resemble rheumatoid arthritis (RA) clinically, but it is most commonly non-erosive, usually runs a benign course, and spontaneously improves after IVIG (intravenous immunoglobulin) therapy. Rheumatoid factor is negative. Often the large joints are involved and there are no extra-articular manifestations typical of RA (only subcutaneous nodules that have a histology similar to that of RA have been occasionally reported). In histological studies of the synovium, chronic synovitis with mainly perivascular CD8+ lymphocyte infiltrates is present. In these patients we can see predominance of CD8+ lymphocytes in the peripheral blood. The CD4/CD8 ratio is reversed due to the elevated number of CD8+ cells (CD4/CD8 ratio <1). After infusions of immunoglobulins, the CD8+ lymphocyte count is sometimes decreased [10]. It is possible that CD8+ lymphocytes are involved in the pathogenesis of arthritis associated with agammaglobulinemia. The arthritis of hypogammaglobulinemia often dramatically improves after gammaglobulin treatment and can therefore be included among the few potentially curable polyarthritides. There are some reports of an association between RA and primary hypogammaglobulinemia. Some of the cases were perhaps not RA, but mycoplasma arthritis. Hypogammaglobulinemia could also be secondary to drug therapy (most commonly gold) [11]. In patients with RA and hypogammaglobulinemia it is likely that the arthritis is predominantly T-cell mediated.

Septic arthritis in patients with hypogammaglobulinemia is usually due to a mycoplasma organism (*Mycoplasma*

*pneumoniae*, *Mycoplasma hominis*, *Mycoplasma salivarium*) and seldom to bacterial pathogens such as *Streptococcus pneumoniae* and *Haemophilus influenzae*. In these cases, highly destructive mono-, oligo-, or polyarthritis appear. Sometimes the patients have urethritis, conjunctivitis, and low synovial fluid glucose and we must distinguish it from reactive arthritis. When confronted with negative cultures, PCR testing allows us to identify such infections.

In the literature they are only a few examples of the coincidence of hypogammaglobulinemia and scleroderma or pansclerotic morphea. Disabling pansclerotic morphea is the most severe form of linear morphea. In this disease, elevation of gamma globulins are very often present. Devidayal et al. [12] described a unique combination in a 1.5-year-old girl with disabling pansclerotic morphea and hypogammaglobulinemia (perhaps CVID). Pamuk et al. [13] presented a patient who was diagnosed as having XLA in early childhood and who developed oligoarthritis at 5 years and limited cutaneous scleroderma at 8 years of age. There are some reports of a good response after IVIG therapy, which decreased the skin score in scleroderma, but this patient developed scleroderma while using regular IVIG.

## Common variable immunodeficiency

Common variable immunodeficiency (CVID) patients are known to have an increased tendency to develop autoimmune manifestations [14]. It may be the first or sole sign before the underlying disease is established. CVID is the most common symptomatic primary antibody deficiency syndrome. CVID is not a single disease, but an idiopathic group of diseases characterized by various degrees of defective antibody production.

It is characterized by recurrent bacterial infections, especially of the upper and lower respiratory tracts, and is also associated with an increased incidence of autoimmune and neoplastic disorders [15]. Most patients are diagnosed as adults. The median age at the time of onset of symptoms is the second or third decade of life. The diagnosis is made upon exclusion of other causes of humoral immune defects such as multiple myeloma, thymoma, lymphoid malignancies, and the use of drugs. The diagnosis of CVID requires decreased immunoglobulins of at least two isotypes (serum IgG, IgA, or IgM reduced by two or more standard deviations from the normal mean) with impaired specific antibody formation.

The predominant manifestation is hypogammaglobulinemia. The underlying cause is still unknown, although several T- and B-cell defects have been described. A principal defect in CVID appears to be abnormal terminal differentiation of B cells to immunoglobulin-secreting cells after appropriate T-cell- or mitogen-derived stimulatory signals [16]. T-cell abnormalities are very often present in CVID: defects in interleukin 2, interferon gamma production, T-cell signaling pathway, or depressed expression of the CD40

ligand in T cells. Some patients have defective signal transduction with diminished proliferative responses occurring after T-lymphocyte receptor stimulation.

It is known that patients with CVID are more susceptible to autoimmune disease; about 22-25% of patients with CVID develop autoimmune diseases. There are often female and are more likely to develop malignancies in the 5<sup>th</sup> and 6<sup>th</sup> decades than CVID patients without autoimmune disease. The most common autoimmune diseases described are idiopathic thrombocytopenic purpura and autoimmune hemolytic anemia. ITP occurred in 7.6% and AHA in 4.8% of patients. Patients with CVID and ITP generally respond well to treatment with corticosteroids (max: 1 mg prednisone/kg) and IVIG (1-2 g/kg over 1 week). Recurrent episodes could be treated in a similar manner and splenectomy is almost never required [17]. Pernicious anemia has also been reported. Autoimmunity can affect every organ. Bloch-Michel et al. [18] analyzed 17 patients with CVID. Seven patients developed autoimmune conditions (insulin-dependent diabetes, idiopathic thrombocytopenic purpura, rheumatoid arthritis). These patients had activated T CD4(+) and/or CD8(+) cells. The other 5 patients did not have activated T lymphocytes, but presented with infectious events only. In 95 patients with CVID, 19% had one or more autoimmune diseases: pernicious anemia (6%), atrophic gastritis (3%), idiopathic thrombocytopenia (3%), rheumatoid-like arthritis (2%), autoimmune hemolytic anemia (1%), and autoimmune thyroiditis (1%) [19].

SLE is a disorder characterized by hypergammaglobulinemia associated with high levels of autoantibodies and circulating immune complexes. In the literature, a dozen or so patients with SLE and CVID have been reported. SLE was diagnosed first and the patients were treated with immunosuppressive drugs, so it is difficult to establish whether SLE or immunosuppressive therapy was the primary cause of hypogammaglobulinemia. Another possibility is the existence of lymphocytotoxic antibodies, which have been observed in patients with SLE. In SLE patients with decreased immunoglobulin levels, high levels of lymphocytotoxic antibodies were reported [20]. SLE and CVID is a very interesting association. SLE and CVID are both associated with aberrant immune regulation. In SLE there is excessive B-cell activity, often with hypergammaglobulinemia and autoantibody formation, and in CVID there are reduced levels of immunoglobulins. There do not appear to be any differentiating clinical features between SLE developing in the presence or absence of CVID. A review of 18 patients with hypogammaglobulinemia and SLE identified multiple etiologies of these cases [21, 22]:

- excessive T suppressor cell function,
- diminished T helper cell activity,
- decreased numbers of phenotypically characterized B cells,
- intrinsic B-cell dysfunction,
- extrinsic factor with an effect of B-cell maturation,

- existence of lymphocytotoxic antibodies,
- immunosuppressive medications.

The question remains whether these two disorders simply coexist or whether CVID is a complication of SLE or caused by the immunosuppressive treatment given to these patients. Tarrant et al. described a patient with SLE who developed a loss of circulating B cells with associated hypogammaglobulinemia requiring immunoglobulin. The SLE went into complete remission. Recently, anti-CD20 antibodies used to selectively deplete mature B cells have been effective in treating autoantibody-mediated diseases and these results suggest that such therapy may also be effective in SLE [23].

In a large study of 103 patients with CVID, 3 were reported to have juvenile rheumatoid arthritis (JRA), but it was unclear whether the arthritis or the immunodeficiency appeared first [24].

Świerkot et al. [25] described the case of a 38-year-old patient in whom recurrent respiratory infections of increasingly serious course had appeared since she was about 12 years old. These were later accompanied by infections of the digestive tract, neurological complications in the form of tetraparesis, periodic fevers, as well as painfulness and features of inflammation in the area of several joints, despite treatment with anti-inflammatory agents. CVID was diagnosed on the basis of the clinical symptoms and laboratory results. Substitution IVIG was applied, achieving notable improvement in the patient's quality of life, a decrease in the frequencies of inflammation and fever, and distinct improvement in the condition of the joints.

Single cases of the coexistence hypogammaglobulinemia and inclusion-body myositis have been reported. The occurrence with CVID may be a clinical clue for a viral pathogenesis of inclusion-body myositis. There is an increased rate of the simultaneous occurrence of eosinophilic fasciitis and CVID. Di Gioacchino et al. [26] reported on a 53-year-old patient with persistently low levels of all immunoglobulin classes, unrelated to protein loss or immunosuppressive treatment, one year after the appearance of eosinophilic fasciitis.

Many autoimmune diseases may appear at times simultaneously in patients with CVID. A 13-year-old boy had JRA, hemolytic anemia, alopecia, and juvenile warts. The numbers of circulating T and B lymphocytes were normal, while T-cell function was depressed and B cells were unable to secrete IgM or IgG [27]. Tanus et al. [28] report a case of CVID presenting with multiple unusual autoimmune diseases, including parotitis, vitiligo, atrophic gastritis, pernicious anemia, and primary biliary cirrhosis.

Chronic inflammatory bowel diseases might occur in up to 20% patients with CVID (most often the large bowel is affected). The inflammatory bowel diseases may have histological features of celiac disease, Crohn's disease, or acute graft-versus-host disease. In these patients, the tumor necrosis factor  $\alpha$  concentration is often very high.

Granulomatous disease has been reported in several patients with hypogammaglobulinemia, with granuloma occurring in the lymph nodes, spleen, liver, kidney, central nervous system, and bone marrow. The pathogenesis of granulomatous disease in CVID is unclear, but may involve monocyte and T-cell abnormalities. Good response was described after corticosteroid treatment and intravenous immunoglobulin infusions [29]. Wegener's granulomatosis associated with CVID could be treated with conventional therapy (IVIg and immunosuppressive agents such as cyclophosphamide) despite hypogammaglobulinemia [30].

A variety of autoimmune disorders may dominate the clinical picture of CVID such that the underlying immunodeficiency is overlooked.

### X-linked agammaglobulinemia

X-linked agammaglobulinemia (XLA) is a hereditary immune deficiency caused by a mutation of the gene encoding Bruton's tyrosine kinase (Btk) protein. Mutations of Btk impair B-cell receptor signaling and impair the transition from pre-B to B cell. Only males are affected. The clinical symptoms consist of recurrent bacterial infection, especially due to encapsulated organism such as *Streptococcus pneumoniae* and *Haemophilus influenzae*. The disease is characterized by the onset of bacterial infections at an early age (usually after 6 months), low serum immunoglobulin levels in all isotypes, and a quite decreased number of B cells in the peripheral blood.

Autoimmune diseases are rarely described in XLA patients. A dermatomyositis-like syndrome has been described in about 20 patients with X-linked hypogammaglobulinemia. A cutaneous and muscular syndrome resembling dermatomyositis in a patient with congenital agammaglobulinemia was first reported in 1956 [31]. The syndrome is often accompanied with echovirus or echovirus-adenovirus combination meningoencephalitis (the virus may occasionally be retrieved from muscle biopsies). Neurological signs are often extremely discrete, in particular at the onset, and can be completely absent. Non-pitting edema of the lower legs or a transient erythematous rash is occasionally the first sign of the condition. Some of the patients have HLA B8 (55% of patients) and HLA-DR3 (90%), which seems to play a major role in juvenile dermatomyositis [32]. In muscle biopsies obtained during the period of the dermatomyositis-like syndrome, CD8+ lymphocytic infiltrates very similar to observations in classical dermatomyositis were demonstrated [33]. Serum muscle enzymes increase during exacerbation. The intensity of changes are very diverse: some patients complain only of stiffness, while others have flexion contractures of the knees or elbows. The treatment of dermatomyositis-like syndrome is often very difficult. Extremely high doses of IVIg should be used, and treatment with intrathecal immunoglobulin could be successful in cases with central nervous system involvement.

In patients with XLA, chronic aseptic arthritis, very similar to juvenile rheumatoid arthritis, sometimes appears. Janeway et al. reported already in 1956 an increased incidence of arthritis, with negative joint fluid cultures in children with XLA [31]. The arthritis is usually non-erosive and responds well to intravenous gammaglobulin infusion. XLA should be considered as a possible underlying cause of juvenile chronic arthritis in males. Early recognition is important for early therapy with gammaglobulin infusions.

Patients with hypogammaglobulinemia sometimes develop classical RA. Verbruggen et al. [34] described a patient with XLA who presented with an erosive symmetrical polyarthritis with histological features of RA, including the formation of a destructive pannus. Infiltrates in both the synovium and nodule consisted almost exclusively of CD8+ T cells. This case illustrates that classical RA can develop in the absence of mature B cells. Patients with hypogammaglobulinemia can also develop subcutaneous nodules that are histologically indistinguishable from rheumatoid nodules. The pathogenic role of B cells in rheumatoid arthritis has recently gained much interest due to the marked clinical responses of anti-CD20 therapy in RA.

Other autoimmune phenomena, such as alopecia, AHA, and scleroderma, were also described. In many cases, treatment with IVIg may ameliorate their condition.

### IgA deficiency

In selective IgA deficiency (SIgAD), the most common primary immunodeficiency disorder (1 in 600), serum IgA is <5 mg/dL, with levels of IgG and IgM remaining normal. Some IgA-deficient patients have concomitant IgG subclass deficiencies; in about 10% of patients, the IgA deficiency may also be associated with a selective IgG2 deficiency. Most people are asymptomatic. Selective IgA deficiency occurs with increased prevalence in atopic individuals. IgA deficiency and CVID may occur in the same family, suggesting a genetic relationship between these immune defects. Genetic predisposition to CVID, as to isolated IgA deficiency, may be determined by genes within the class III region of the major histocompatibility complex (MHC) [35].

Autoimmune manifestations were reported in 7-36% of patients with selective IgA deficiency and more than 40% of patients with abnormal serum antibodies to cells or tissues.

Patients with IgA deficiency produced various autoantibodies, including rheumatoid factor, antinuclear, antithyroid, anti-smooth muscle, anti-bile canaliculi, and anticardiolipin antibodies [17].

The most specific autoimmune disorders are SLE (1-5%), rheumatoid arthritis (2-4%) and JRA. Conversely, 1-4% of JRA patients have low IgA levels or IgA deficiency [36]. The prevalence of IgA deficiency in patients with SLE ranges from 0.94-4.6%, which is 10-20 times higher than in the general population [37]. Ammann et al. [38] reported in 30 IgA deficient patients 26 with aseptic polyarthritis, 3 with

dermatomyositis, 2 with Sjögren's syndrome, and 1 with SLE. Other disorders that are found with increased frequency include celiac disease and inflammatory bowel disease. The prevalence of SIgAD in patients with celiac disease is 2.6%, which is 10-16 times higher than in the general population [39]. Idiopathic Addison's disease of the adrenal glands, myasthenia gravis, autoimmune thyroiditis, and chronic active hepatitis have also been reported. ITP may occur in 1/200 individuals with selective IgA deficiency.

Davies et al. [40] presented 13 patients with IgA deficiency in the 22q11 deletion syndrome who developed inflammatory polyarticular arthritis. The arthritis was clinically indistinguishable from juvenile idiopathic arthritis. The patients were treated with methotrexate and/or corticosteroids with partial response.

Parenteral immunoglobulin replacement therapy is not indicated because the patients very often have anti-IgA antibodies (IVIG could be done only in patients with concomitant IgG subclass deficiency).

## Conclusions

Primary antibody deficiencies have variable autoimmune manifestations. For early detection and appropriate treatment, autoimmune disease should be suspected in patients with immunodeficiency. Recognition of this association is important because early diagnosis and treatment can greatly influence the prognosis. The basis of treatment for primary immunodeficiencies is immunoglobulin replacement for antibody deficiency syndromes (other than selective IgA deficiency) and the prevention and aggressive treatment of infections. The exact mechanism of action by which IVIG are of benefit in such diseases is complex and only partly understood. The immunomodulatory potential of IVIG in patients is a result of a variety of complex mechanisms that act in a synergy:

- interaction of the Fc portion of immunoglobulins with Fc receptors,
- selection of lymphocyte repertoires of patients through variable regions of infused immunoglobulins,
- modulation of the activation and effector functions of B and T lymphocytes,
- neutralization of pathogenic autoantibodies,
- interference with antigen presentation,
- a strong anti-inflammatory effect which depends on its interaction with the complement system, cytokines (increased serum concentration levels of IL-6, IL-8, IL-1Ra, and TNF alpha, no significant variation observed in the serum levels of IFN gamma, or IL-2), and endothelial cells [41].

In evaluating patients with rheumatic diseases for hypogammaglobulinemia it is important to consider that drugs used in the therapy of rheumatic diseases (gold, sulfasalazine, D-penicillamine) may cause hypogammaglobulinemia.

Primary immunodeficiencies and autoimmune disorders might be viewed as being at opposite ends of a spectrum, but the truth is more complicated. Paradoxically, patients may have both immunodeficiency and autoimmune disorders.

## References

1. Arkwright PD, Abinun M, Cant AJ (2002): Autoimmunity in human primary immunodeficiency diseases. *Blood* 99: 2694-2702.
2. Etzioni A (2003): Immune deficiency and autoimmunity. *Autoimmun Rev* 2: 364-369.
3. Shevach EM, McHugh RS, Piccirillo CA, et al. (2001): Control of T-cell activation by CD4+ CD25+ suppressor T cells. *Immunol Rev* 182: 58-67.
4. Eisenstein EM, Jaffe JS, Strober W (1993): Reduced interleukin-2 (IL-2) production in common variable immunodeficiency is due to a primary abnormality of CD4+ T cell differentiation. *J Clin Immunol* 13: 247-258.
5. Michel M, Chanet V, Galicier L, et al. (2004): Autoimmune thrombocytopenic purpura and common variable immunodeficiency: analysis of 21 cases and review of the literature. *Medicine (Baltimore)* 83: 254-263.
6. Sanal O, Ersoy F, Metin A, et al. (1995): Selective IgA deficiency with unusual features: development of common variable immunodeficiency, Sjogren's syndrome, autoimmune hemolytic anemia and immune thrombocytopenic purpura. *Acta Paediatr Jpn* 37: 526-529.
7. Sarmiento E, Mora R, Rodriguez-Mahou M, et al. (2005): Autoimmune disease in primary antibody deficiencies. *Allergol Immunopathol (Madr)* 33: 69-73.
8. Uluhan A, Sager D, Jasin HE (1998): Juvenile rheumatoid arthritis and common variable hypogammaglobulinemia. *J Rheumatol* 25: 1205-1210.
9. Swierkot J, Lewandowicz-Uszynska A, Jankowski A, et al. (2005): The arthritic pathologies accompanying primary immunodeficiencies with antibodies synthesis disturbances. *Postepy Hig Med Dosw (Online)* 59: 219-223.
10. Sany J, Jorgensen CH, Anaya JM, et al. (1993): Arthritis associated with primary agammaglobulinemia: new clues to its immunopathology. *Clin Exp Rheumatol* 11: 65-69.
11. Hermaszewski R, Ratnavel R, Webster AD, et al. (1993): Rheumatoid arthritis in a patient with primary hypogammaglobulinaemia. *Br J Rheumatol* 32: 636-639.
12. Devidayal, Singh S, Kumar L, et al. (2002): Disabling pansclerotic morphea of childhood and hypogammaglobulinemia: a curious association. *Rheumatol Int* 21: 158-160.
13. Pamuk ON, Pamuk GE, Turgut B, et al. (2004): Scleroderma in a patient with X-linked agammaglobulinaemia. *Scand J Rheumatol* 33: 59-60.
14. Bernatowska E, Pac M, Pietrucha B (2003): Autoimmunity and hypersensitivity in children with immunodeficiencies. *Nowa Pediatría* 32: 41-44.
15. Lewandowicz-Uszynska A, Swierkot J, Jargulinska E, et al. (2007): Common variable immunodeficiency. *Centr Eur J Immuno* 32: 21-26.
16. Itescu S (1996): Adult immunodeficiency and rheumatic disease. *Rheum Dis Clin North Am* 22:53-73.
17. Cunningham-Rundles C (2002): Hematologic complications of primary immune deficiencies. *Blood Rev* 16: 61-64.
18. Bloch-Michel C, Viillard JF, Blanco P, et al. (2003): Common variable immunodeficiency: 17 observations in the adult. *Rev Med Interne* 24: 640-650.

19. Kainulainen L, Nikoskelainen J, Ruuskanen O (2001): Diagnostic findings in 95 Finnish patients with common variable immunodeficiency. *J Clin Immunol* 21: 145-149.
20. MacDonald S, Webster AD, Platts-Mills TA (1982): An analysis of the lymphocytotoxic activity found in sera from patients with hypogammaglobulinemia. *Scand J Immunol* 15: 379-387.
21. Cronin ME, Balow JE, Tsokos GC (1989): Immunoglobulin deficiency in patients with systemic lupus erythematosus. *Clin Exp Rheumatol* 7: 359-364.
22. Swaak AJ, van den Brink HG (1996): Common variable immunodeficiency in a patient with systemic lupus erythematosus. *Lupus* 5: 242-246.
23. Tarrant TK, Frazer DH, Aya-Ay JP, et al. (2003): B cell loss leading to remission in severe systemic lupus erythematosus. *J Rheumatol* 30: 412-414.
24. Cunningham-Rundles C (1989): Clinical and immunologic analyses of 103 patients with common variable immunodeficiency. *J Clin Immunol* 9: 22-33.
25. Swierkot J, Lewandowicz-Uszynska A, Chlebicki A, et al. (2006): Rheumatoid arthritis in a patient with common variable immunodeficiency: difficulty in diagnosis and therapy. *Clin Rheumatol* 25: 92-94.
26. Di Gioacchino M, Masci S, Paolini F, et al. (2002): Common variable immunodeficiency and eosinophilic fasciitis. *Eur J Dermatol* 12: 73-74.
27. Uluhan A, Sager D, Jasin HE (1998): Juvenile rheumatoid arthritis and common variable hypogammaglobulinemia. *J Rheumatol* 25:1205-1210.
28. Tanus T, Levinson AI, Atkins PC, et al. (1993): Polyautoimmune syndrome in common variable immunodeficiency. *J Intern Med* 234: 525-527.
29. Fakhouri F, Robino C, Lemaire M, et al. (2001): Granulomatous renal disease in a patient with common variable immunodeficiency. *Am J Kidney Dis* 38: E7.
30. Delevaux I, Andre M, Aumaitre O (2002): Wegener's granulomatosis associated with common variable immunodeficiency. *J Rheumatol* 29: 1577-1578.
31. Craig JM, Gitlin D, Grice DS, et al. (1956): Collagen disease in patients with congenital agammaglobulinemia. *Trans Assoc Am Physicians* 69: 93-97.
32. Thyss A, el Baze P, Lefebvre JC, et al. (1990): Dermatomyositis-like syndrome in X-linked hypogammaglobulinemia. Case-report and review of the literature. *Acta Derm Venereol* 70: 309-313.
33. Wagner DK, Marti GE, Jaffe ES, et al. (1989): Lymphocyte analysis in a patient with X-linked agammaglobulinemia and isolated growth hormone deficiency after development of echovirus dermatomyositis and meningoencephalitis. *Int Arch Allergy Appl Immunol* 89: 143-148.
34. Verbruggen G, De Backer S, Deforce D, et al. (2005): X linked agammaglobulinemia and rheumatoid arthritis *Ann Rheum Dis* 64: 1075-1078.
35. Schaffer FM, Palermos J, Zhu ZB, et al. (1989): Individuals with IgA deficiency and common variable immunodeficiency share polymorphisms of major histocompatibility complex class III genes. *Proc Natl Acad Sci USA* 86: 8015-8019.
36. Barkley DO, Hohermuth HJ, Howard A, et al. (1979): IgA deficiency in juvenile chronic polyarthritis. *J Rheumatol* 6: 219-224.
37. Liblau RS, Bach JF (1992): Selective IgA deficiency and autoimmunity. *Int Arch Allergy Immunol* 99: 16-27.
38. Ammann AJ, Hong R (1971): Selective IgA deficiency: presentation of 30 cases and a review of the literature. *Medicine (Baltimore)* 50: 223-236.
39. Cataldo F, Marino V, Ventura A, et al. (1998): Prevalence and clinical features of selective immunoglobulin A deficiency in coeliac disease: an Italian multicentre study. Italian Society of Paediatric Gastroenterology and Hepatology (SIGEP) and "Club del Tenue" Working Groups on Coeliac Disease. *Gut* 42: 362-365.
40. Davies K, Stiehm ER, Woo P, et al. (2001): Juvenile idiopathic polyarticular arthritis and IgA deficiency in the 22q11 deletion syndrome. *J Rheumatol* 28: 2326-2334.
41. Bayry J, Misra N, Latry V, et al. (2003): Mechanisms of action of intravenous immunoglobulin in autoimmune and inflammatory diseases. *Transfus Clin Biol* 10: 165-169.