

Receptor activator of NF-kappaB ligand (RANKL) and CD 31 expressions in chronic periodontitis patients before and after surgery

ANTON FRIEDMANN¹, NURDAN OZMERIC², JEAN-PIERRE BERNIMOULIN³,
BERND-MICHAEL KLEBER³, EYLEM AYHAN⁴, TUBA AYKAN⁵, CEREN GÖKMENOĞLU⁶

¹Department of Periodontology, School of Dentistry, Faculty of Health, Witten/Herdecke University, Witten, Germany

²Department of Periodontology, Faculty of Dentistry, Gazi University, Biskek caddesi 84.sokak 06510 Emek, Ankara, Turkey

³Institute for Periodontology and Synoptic Dentistry, ChariteCenter 3, Zentrum für Zahnmedizin, Universitätsmedizin Charite, Berlin, Germany

⁴Department of Periodontology, Faculty of Dentistry, 100.Yil University, 65080 Kampüs Van, Turkey

⁵Private Practice, Atatürk Bulvarı Asaf Erkilic Apt. 94/3 Gaziantep, Turkey

⁶Department of Periodontology, Faculty of Dentistry, Ordu University, Bulent Ecevit Bulvarı, Ordu, Turkey

Abstract

Aim of the study: The present study investigated the hypothesis that upregulation of receptor activator of NF-kappaB ligand (RANKL) expression may be associated with upregulation of endothelial cell activity, which is common for periods of periodontal bone loss in chronic periodontitis.

Material and methods: RANKL expression of activated cells in soft tissue biopsies with CD 31 activity and the presence of RANKL and osteoprotegerin (OPG) in gingival crevicular fluid (GCF) were assessed in chronic periodontitis patients. Biopsies from 17 patients and 10 healthy subjects were immunohistochemically analyzed. Clinical measurements [plaque index (PI), the gingival index (GI), probing pocket depth (PPD), clinical attachment level (CAL) and gingival bleeding index (GBI)] and GCF samples were obtained before and after periodontal therapy.

Results: CD31 staining did not support the assumption that endothelium-like cells were predominantly associated with RANKL expression.

Conclusions: RANKL-positive cells were widely distributed in periodontitis patients giving only partial support to the hypothesis that RANKL expression is restricted to T- and B-cell activation.

Key words: gingival crevicular fluid, chronic periodontitis, immunohistochemistry, RANKL, CD31, osteoprotegerin.

(Centr Eur J Immunol 2014; 39 (4): 508-517)

Introduction

Receptor activator of NF-kappaB ligand (RANKL) plays a pivotal role in the differentiation, function and survival of osteoclasts by binding the receptor activator of NF-kappaB (RANK) in osteoclasts and their precursors [1]. When binding RANK, RANKL activates six major signaling pathways: nuclear factor activated T-cells (NFATc1), nuclear factor kappaB (NF-κB), anti-apoptotic signaling proteins Akt/PKB, c-Jun N-terminal (JNK), extracellular regulated (ERK) and p38 map-kinases, which play distinct roles in osteoclast differentiation, function and survival [2]. Periodontal ligament cells (PDL) stimulated osteoclastogenesis by activating RANKL and inhibiting osteoprotegerin (OPG) expression *in vitro* [3]. The same group demonstrated compressive-force-associ-

ated RANKL upregulation in PDL cells after exogenous PGE₂ treatment [4]. RANKL activation was observed in periodontal ligament cells during physiological root resorption of human deciduous teeth [5]. Osteoprotegerin, a natural inhibitor of RANKL; acts as a decoy and blocks the binding of RANKL to RANK [6]. The coordinated action of OPG, RANKL and RANK was observed in tooth development [7]. Localization of RANK and RANKL in human deciduous teeth was shown by immunohistochemistry [8]. *In situ* hybridization revealed RANKL mRNA in inflammatory and epithelial cells adjacent to granulomatous gingival tissue from periodontally diseased sites [9]. RANKL and OPG expression analyzed by semi-quantitative RT-PCR in the same study showed a higher estimated RANKL/OPG ratio in the advanced periodontitis group compared to the moderate one, and both groups

Correspondence: Prof. Nurdan Ozmeric, Department of Periodontology, Faculty of Dentistry, Gazi University, Biskek caddesi 84.sokak 06510 Emek, Ankara, Turkey, e-mail: nurdan@gazi.edu.tr

had a higher ratio than healthy subjects. The effectively blocked RANKL function has been demonstrated to reduce the bone resorption rate without affecting the inflammatory process in periodontal tissues [10]. The T- and B-cell activation enhanced RANKL expression, thus promoting osteoclastogenesis through interactions with the RANKL antagonist OPG [11]. Concentrations of RANKL and OPG in GCF samples have been reported to vary for different forms of periodontitis [12].

Platelet endothelial cell adhesion molecule-1 (PECAM-1; CD31), an IGF superfamily member expressed on platelets and leukocytes, is highly enriched at endothelial cell-cell junctions [13]. Constitutive PECAM-1 expression in healthy gingival samples and keratinized tissue samples obtained around dental implants was observed [14].

In a previous study, severe osteosclerosis and fibrosis in idiopathic myelofibrosis has been reported to be associated with endothelial overexpression of OPG [15]. They stated that immunohistochemical detection of OPG protein revealed strong labelling of endothelial cells. We hypothesized that upregulation of RANKL expression may be associated with upregulation of endothelial cell activity, which is common for periods of periodontal bone loss in chronic periodontitis.

Thus the aims of this study were to assess the presence of RANKL in gingival tissue from patients with chronic periodontal disease compared to periodontally healthy subjects. To relate the distribution of endothelial cell activity – assessed by CD 31 antibody – to RANKL expression in healthy and tissues affected by periodontitis. To address immunohistological findings in periodontal tissues to the detection of RANKL and OPG proteins expressed by periodontal tissues in gingival crevicular fluid samples at baseline, periodontal surgery scheduled 8 weeks after scaling and root planing (SRP) and postoperative two months postoperative in patients with chronic periodontitis.

Material and methods

Subjects

The study included 17 chronic periodontitis patients (10 female and 7 male, aged 28-63 years). The patients selected had at least 18 teeth; 5-6 teeth with a probing depth ≥ 7 mm including 2 single-rooted premolars and 2 incisors in contralateral quadrants of the same jaw. Chronic periodontitis patients were systemically healthy, had not received anti-inflammatory agents, antibiotics, immunosuppressants or systemic contraceptives in the past 6 months, and had never smoked. A group of 10 periodontally healthy volunteers ranging in age between 19 and 24 years agreed to donate gingival tissue for histological purposes. Biopsies were taken during crown-lengthening procedures. The study protocol was approved by the Institutional Review Board. All subjects gave their written informed consent.

The disease status was clinically determined by the plaque index (PI) [16], the gingival index (GI) [17], the probing pocket depth (PPD), the clinical attachment level (CAL), the gingival bleeding index (GBI) [18] and by radiographic examinations. Following periodontal examination, all patients underwent basic periodontal therapy, including oral hygiene instructions and plaque control evaluation, supra- and subgingival scaling and root planing. Periodontal surgery was scheduled 8 weeks after scaling and root planing.

Biopsy technique

Prior to any treatment, first biopsies were obtained from the interdental gingival papilla. Where periodontal surgery was considered to be indicated, tissue sampling has been repeated at the same site 8 weeks after scaling and root planing. An inverse bevel incision was used to obtain 1 mm tissue samples from the underside of the papilla. Biopsies included the pocket epithelium, connective and granulation tissues. Care was taken to achieve good cicatrization with no esthetic consequences. In healthy volunteers, caution was paid to obtain tissue samples of similar dimensions. After washing in sterile 0.15 M saline solution, samples were placed in 10% neutral buffered formalin for immunohistochemical analysis and were immediately sent to the laboratory.

Control samples

For control purposes, samples were taken from core biopsies of previously augmented human alveolar jaw bone that had been stored as paraffin-embedded tissue blocks. Sections of five different samples from this previously approved study were stained with RANKL antibody as positive controls and as negative controls without antibody staining. Connective tissue taken from the palatal aspect of the mucoperiosteal flap during implant installation served as a negative control for RANKL expression. Sections of the same samples were similarly treated for testing CD31 activity.

Immunohistochemical staining

A routine immunohistochemical procedure was applied to 4 μ m thick sections cut from paraffin-embedded tissue blocks. For two stainings, Target Retrieval Solution, pH 9.9 (DaKoCytomation, Glostrup, Denmark), and heating were used to unmask the antigens and retrieve sections mounted on precoated glass slides. Staining was done with primary mouse anti-human monoclonal antibodies specific for CD31 (DaKoCytomation, Glostrup, Denmark), and RANKL (Clone 2C3A 12 C, BioVendor GmbH, Heidelberg, Germany). Monoclonal antibody was diluted to 1 : 100 with TBS buffer. Labelled polymer-HRP anti-mouse antibody (DaKoCytomation, Glostrup, Denmark) was used for secondary antibody staining. The two-step

DAKO EnVision System technique was used. Hematoxylin served as a counterstain for both antibody reactions.

Controls

Negative controls. The specificity of the immunoreaction was assessed by negative controls carried out by omitting the primary antibody and by omitting the primary and secondary antibody and using TBS/BSA instead. These experiments were performed in both test and control sections.

Positive controls. Tissue sections from a previous study on bone regeneration in alveolar defects [19] were expected to show significant amounts of RANKL antigen or to display CD31 activity. These biopsies, harvested at 7 months after augmentation procedure were considered positive controls and treated in the same way as test specimens.

Gingival crevicular fluid sampling

The deepest gingival biopsy sites in donor teeth were chosen for GCF sampling prior to any periodontal treatment. The area was isolated by cotton rolls drying the teeth and marginal gingiva with air before sampling. Perio paper strips were inserted for 30 seconds into the buccal crevice to a level of 1 mm below the gingival margin after supragingival plaque removal and recording of the PI were completed. Contaminated strips were excluded. GCF sampling was repeated 8 weeks after scaling and root planing. Each sample was stored at -70°C until assayed. In each patient, paper strips from different sites were pooled for each visit [12]. The estimation of GCF amounts was achieved using the electronic balance, thus all numbers on GCF measures are given in μg .

Cytokine analysis

Strips were eluted by centrifugation ($5000 \times g$, 4°C , 6 min) in $300 \mu\text{l}$ of solution containing 150 mM Tris, Pep-

statin A, leupeptin, amastatin and antipain dihydrochloride. ELISAs were used for quantitative detection of human total sRANKL (free and OPG-bound RANKL) and OPG (BioVendor GmbH, Heidelberg, Germany). In human total sRANKL ELISA, calibrators and samples (1 : 100 dilution) were incubated in wells together with the excess of recombinant OPG. The sRANKL/OPG complex appeared during the two-hour incubation step and was captured by the immobilized anti-sRANKL monoclonal antibody. After washing, horseradish peroxidase-labelled anti-OPG polyclonal antibody was added and incubated in the wells. In human OPG ELISA, the standards and samples (1 : 3 dilution) were incubated with a mouse monoclonal anti-human OPG antibody coated in wells. After washing, biotin-labeled polyclonal anti-human OPG antibody was added and incubated with captured OPG. After adding conjugate and following stop solution, the reaction was measured at 450 nm.

Statistical analysis

Clinical parameters (PI, GI, GBI, PPD and CAL) were calculated for all chronic periodontitis patients. The Wilcoxon signed rank test for clinical parameters was used to evaluate the differences before and after treatment. Correlations between clinical parameters were analyzed by Spearman's correlation coefficient. The Mann-Whitney *U* test enabled comparative evaluations between diseased and healthy groups (SPSS 14.0 for Windows).

Results

Clinical evaluation

The data in Table 1 characterizes patients diagnosed with chronic periodontitis. The table displays medians for

Table 1. Medians and ranges for clinical parameters in sites used for GCF sampling at baseline (BS – before surgery), after scaling and root planing (PS – at surgery) and two months later at control visit (CV) in periodontitis patients

	Baseline (BS)	Periodontal Surgery (PS)	Control visit (CV)	<i>p</i> -value Wilcoxon's signed rank test		
				Change BS-PS	Change PS-CV	Change BS-CV
Plaque Index (PI)	1.05 (0.17-2.32)	0.38 (0.11-0.77)	0.31 (0.06-0.57)	0.001	0.173	0.002
Gingival Index (GI)	1.33 (0.59-2.10)	0.75 (0.09-1.57)	0.35 (0.05-1.37)	0.001**	0.006	0.001
Pocket Depth (mm)	3.53 (1.6-5.38)	3.04 (1.59-4.57)	2.35 (1.19-4.04)	0.001**	0.001**	0.001**
Clinical Attachment Level (mm)	3.64 (1.68-5.38)	3.15 (1.64-4.57)	3.04 (1.16-4.04)	0.001**	0.007**	0.001**
Gingival Bleeding Index (%)	28.9 (4.7-96.2)	13.80 (0.00-53.57)	9.50 (0.00-22.36)	0.012*	0.034*	0.001**

Non-significant difference ($p > 0.05$), significance levels (* $p < 0.05$, ** $p < 0.001$).

the 17 chronic periodontitis patients at baseline, before surgery and at control visit two months after surgery appointment. The periodontal status of the 10 healthy subjects is characterized by full mouth PI of 0.01 ±0.14; GI of 0.18 ±0.3 and PPD of 1.4 ±0.6 mm. Thereby, the values for periodontal probing and clinical attachment were calculated on the basis of single-tooth measurements, taking into account only teeth used for biopsy sampling.

In the periodontitis group, all clinical parameters showed statistically significant improvement from baseline evaluation to intermediate evaluation at surgical appointment followed by further improvement at control visit (Table 1).

sRANKL immunohistochemistry

All 17 samples from the periodontal group showed positive RANKL staining. All specimens displayed granular cytoplasmic staining of moderate to strong intensity. A cytoplasmic concentration of activity was regularly observed in cells of different origins, but the majority of positively stained cells appeared to be located at the basement membrane. Table 2 shows the distribution pattern of RANKL activity in every biopsy from chronic periodontitis patients. This pattern did not distinguish between the times of biopsy harvesting (Figs. 1-5). In the granulation tissue, the distribution of positive staining was related to blood vessels. Interestingly, the CD31 staining revealed endothelial cell activity in less than 50% of all samples (Table 2; Figs. 6 and 7). It was generally weaker than RANKL staining and disclosed a much smaller number of positive cells (Figs. 8 and 9).

Controls

Osteoblasts, osteocytes, and single osteoclasts showed cytoplasmic RANKL immunoreactions in the positive control experiments performed using core biopsies (Figs. 10 and 11). CD31 staining assessed in these positive controls revealed most often positive reacting cells located near the capillary walls (Figs. 12 and 13).

Neither RANKL nor CD31 immunostaining was found in connective tissue from the palatal aspect of a mucoperi-

osteal flap in a periodontally healthy patient serving as negative control (Figs. 14 and 15).

Neither RANKL- nor CD31-positive cells were detected in any samples from the 10 healthy subjects (Figs. 16 and 17).

Gingival crevicular fluid measurements

Gingival crevicular fluid (GCF) levels were reduced after initial treatment and showed further diminishment two months after surgery. The reduction from 9.0 µg at BL to 7.35 µg at PS was statistically significant ($p = 0.036$),

Table 2. Distribution pattern of RANKL and CD 31 activity in the biopsies from chronic periodontitis patients

Sample	RANKL activity in the cells				CD31 activity
	KC	BM	CT	EC	
1	-	+	+	+	none
2	-	-	+	+	none
3	+	+	+	+	yes
4	+	+	+	+	yes
5	-	+	-	-	none
6	+	+	+	+	yes
7	+	+	+	+	yes
8	-	+	+	-	yes
9	-	+	+	+	none
10	+	+	+	+	weak
11	-	-	+	+	none
12	-	-	+	+	none
13	+	+	+	-	none
14	+	+	-	-	yes
15	-	-	+	-	none
16	-	-	+	+	yes
17	-	-	+	+	none

KC – keratinocytes, BM – basement membrane, CT – connective tissue; EC – endothelial cells

Table 3. RANKL and OPG concentrations in gingival crevicular fluid before surgery (baseline), after scaling and root planing (at surgery) and two months later at control visit (CV). Medians and ranges

	Baseline (BS)	Periodontal surgery (PS)	Control visit (CV)	p-values BS-PS BS-CV	
GCF amount (µg)	9.00* (3.40-90.80)	7.35* (3.20-80.00)	4.60* (1.90-92.60)	0.036*	0.021*
RANKL concentration (pg/ml)	19399.20 (9431.80-38408.20)	18310.60 (8292.60-35631.60)	14771.40 (2454.60-31217.60)	n.s.	n.s.
OPG concentration (pg/ml)	27.72 (3.76-55.04)	30.32 (3.60-69.16)	25.40 (3.40-58.36)	n.s.	n.s.

Wilcoxon signed rank test, *significant difference at $p < 0.05$

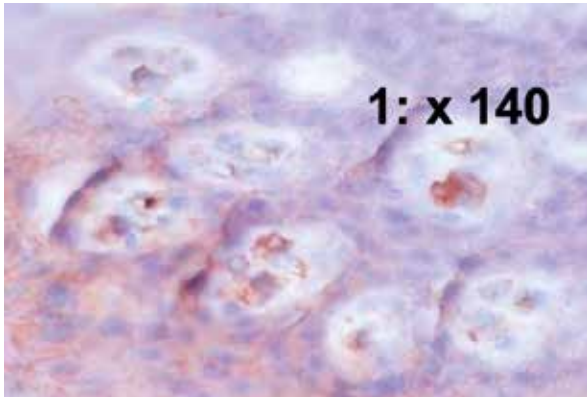


Fig. 1. Keratinocytes with weak to strong cytoplasmic RANKL expression (140x)

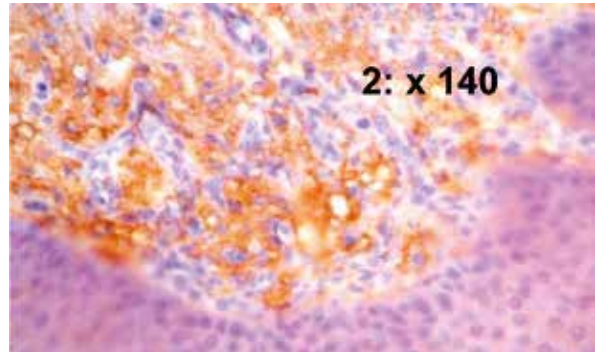


Fig. 2. Apical aspect of the basement membrane (140x)

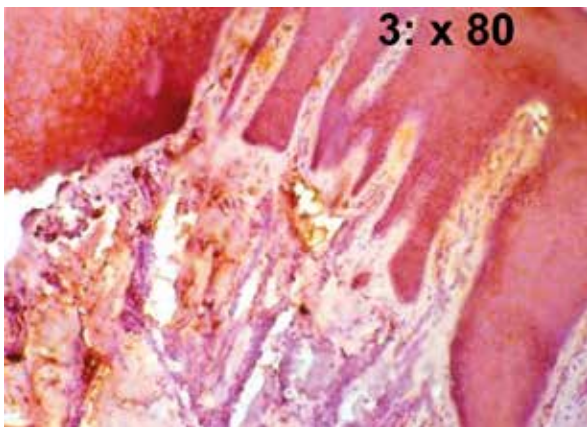


Fig. 3. RANKL expression in rete pegs (80x)

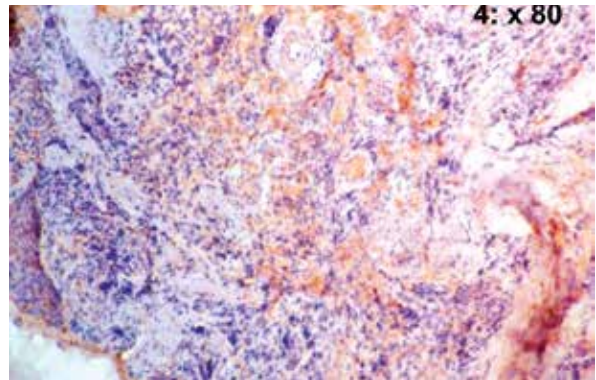


Fig. 4. Strong RANKL staining of inflammatory cells in connective tissue (80x)

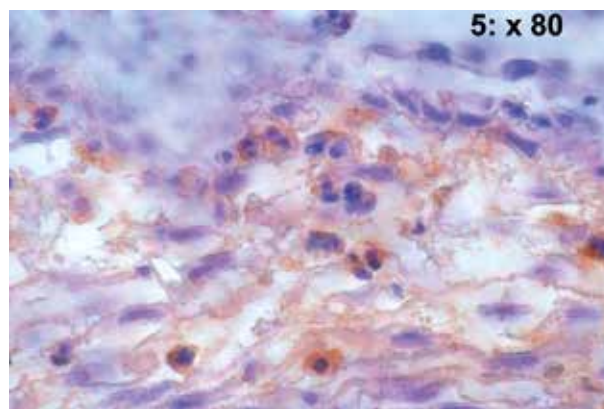
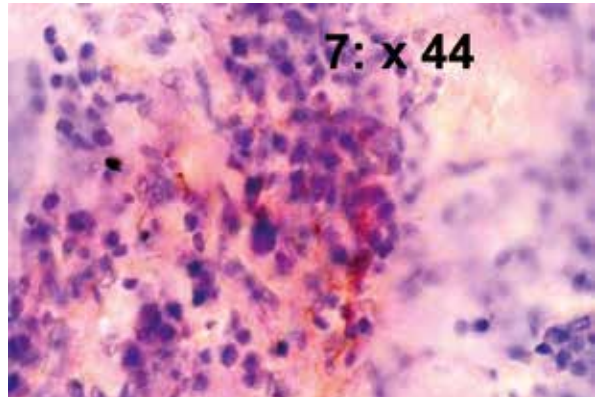
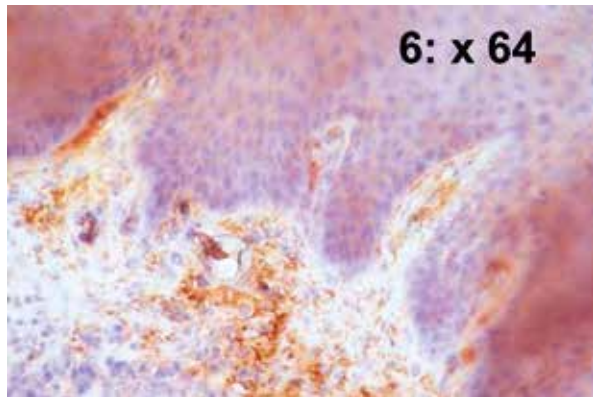
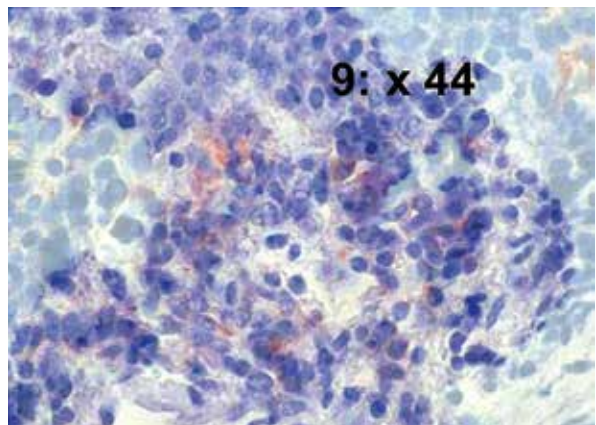
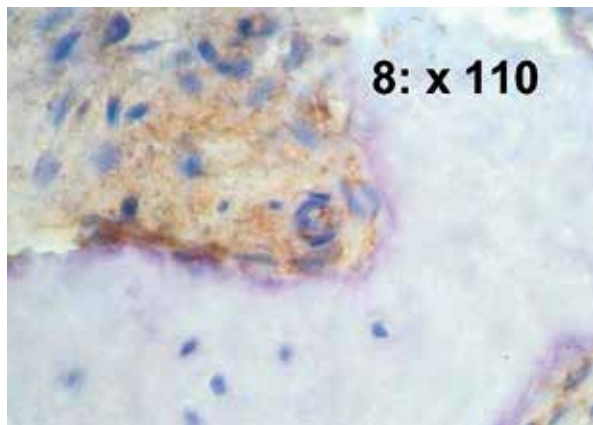


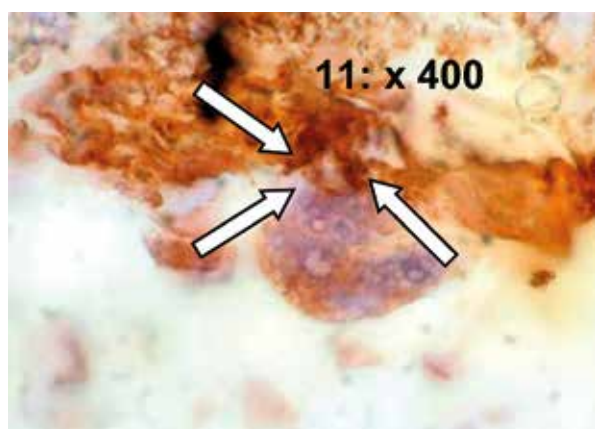
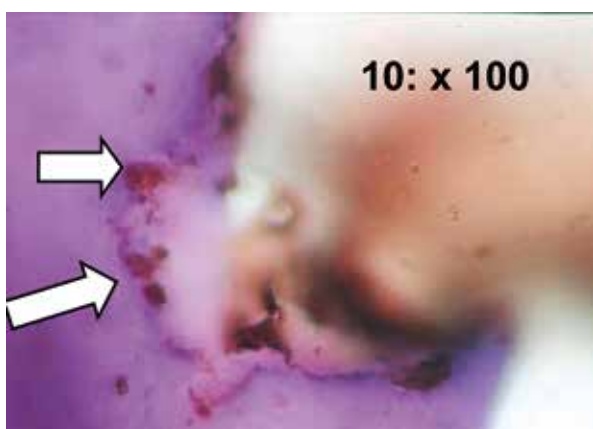
Fig. 5. Mono- and multinucleated leukocytes show strong cytoplasmic staining (80x)



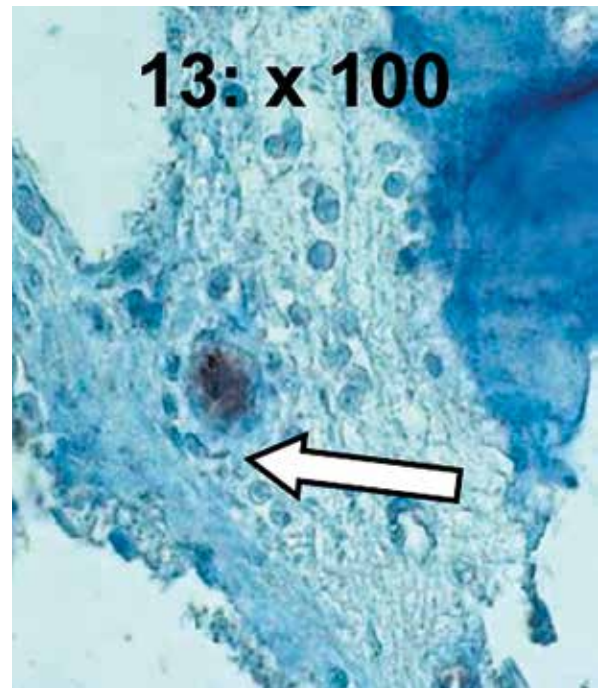
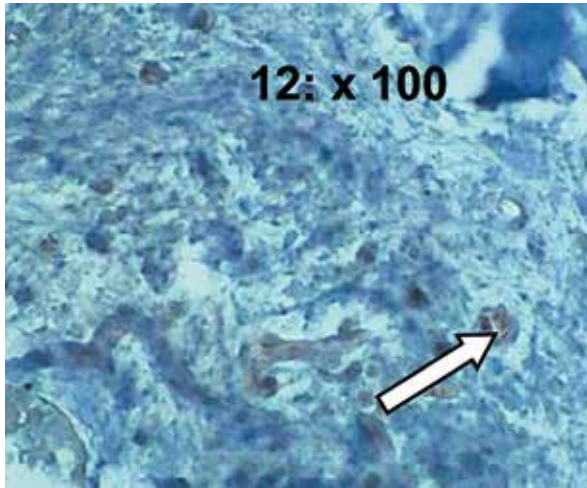
Figs. 6 and 7. Patient 4 (periodontitis group): strong RANKL expression in various cell types (64×) (Tbl. 1) associated with strong CD31 activity (44×) in connective tissues



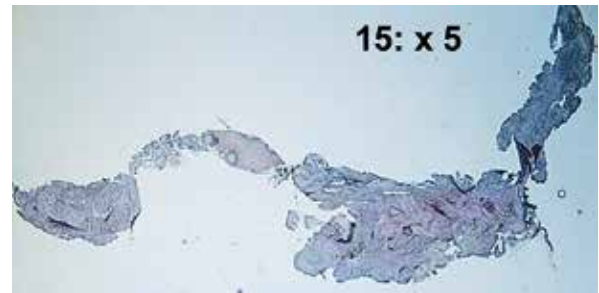

Figs. 8 and 9. Patient 16 in the chronic periodontitis group; biopsy harvesting at surgery: strong RANKL reaction (110×) combined with weak CD31 staining (44×)



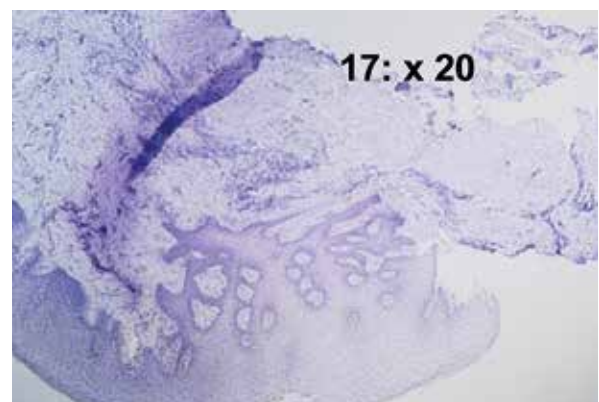
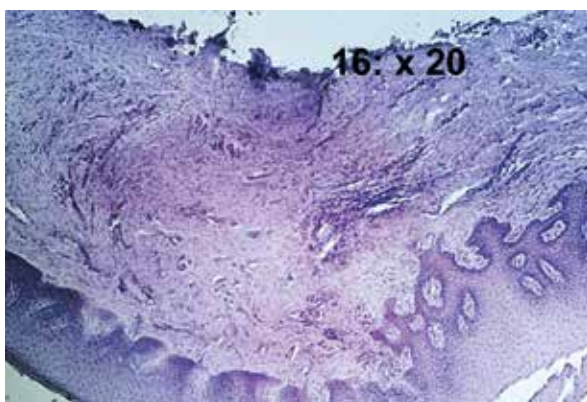
Figs. 10 and 11. Positive controls from core biopsies of alveolar bone: RANKL-positive cells exhibit expression of the protein in osteoblasts (left, arrows; 100×) and multinucleated osteoclasts (right, arrows; 400×)



Figs. 12 and 13. CD31 staining shows capillary walls with active cells in the connective tissue compartment of the core biopsy (100 \times , respectively)



Figs. 14 and 15. Negative controls (connective tissue from palatal aspect of the flap) no RANKL expression (20 \times) and no CD31 (5 \times) activity detectable



Figs. 16 and 17. Periodontally healthy patients: no RANKL expression in either tissue compartment of the biopsy; no CD31 activity detectable (same sample; 20 \times for both)

however, continued decrease of crevicular fluid flow was assessed with 4.60 µg two months after surgery and did not reach statistically significant value ($p = 0.209$). The difference between BL and CV estimation of GCF amount was statistically significant ($p = 0.021$).

The medians for total RANKL were 19399.20 pg/ml at baseline and 18310.60 pg/ml before surgery and 14771.40 pg/ml two months after surgery. The reductions were statistically non-significant ($p = 0.735$; $p = 0.327$; $p = 0.239$, respectively). The medians for OPG concentrations were 27.72 pg/ml, 30.32 pg/ml and 25.40 pg/ml, respectively. These changes were also statistically non-significant ($p = 0.237$, $p = 0.575$ and $p = 0.239$, respectively) (Table 3).

Discussion

This investigation clearly demonstrates that RANKL is expressed by various cells of periodontal soft tissues and can be detected when measuring the total protein content of crevicular fluid samples in chronic periodontitis. Gingival crevicular fluid content showed an increased RANKL/OPG ratio in patients with periodontitis compared to periodontally healthy subjects [12, 20]. Our study showed positive RANKL staining for keratinocytes, basement membrane cells, connective tissue cells and endothelial cells (Table 2). Connective tissue RANKL staining was found in majority of biopsies (15 out of 17) from periodontally diseased tissues. Liu *et al.* [9] used *in situ* hybridization to demonstrate that both inflammatory and epithelial cells are involved in RANKL mRNA expression in gingival tissues of periodontitis patients. Semiquantitative RT-PCR enabled their group to estimate that RANKL/OPG mRNA expression ratios decreased from advanced to moderate periodontitis and were lowest in healthy subjects [9]. They stated that an increased RANKL-to-OPG ratio may reflect a modulatory role of this relationship in periods clinically characterized by localized bone loss. However, statistically significant improvement achieved during initial therapy in some clinical parameters found no reflection neither by assessable decreases in RANKL values nor by increased OPG levels in our study. Furthermore, the gingival bleeding index, considered a marker for inflammatory process, remained high at the PS appointment, indicating a possible association with elevated RANKL levels. Significant clinical improvement found between BL and PS was not reflected by RANKL and OPG levels in GCF samples from patients.

Kawai *et al.* [21] showed activation of T and B cells will be followed by expression of RANKL into gingival tissues by these activated T and B cells. But such cells as monocytes or fibroblasts, would never be a source for RANKL expression to initiate bone resorption in periodontitis. It was stated that RANKL expression by antigen-specific activated T-cell and B-cell may be an initial step in differentiation of osteoclasts within gingival tissues, if lat-

ter are pre-inflamed. In our study, however, the positive RANKL staining of the most connective tissue cells and also cells of different origin may indicate that RANKL expression may not necessarily follow only the activation of T- and B-cells. Moreover, RANKL mRNA expression was detected from 67% of the diseased gingival tissues, whereas no expression of RANKL mRNA was observed in samples from the healthy gingival tissues. In accordance with the results from Kawai's *et al.* [21] study, we also found that healthy tissues did not show any RANKL expression.

A recent study in rats demonstrated that osteoclasts and periodontal ligament (PDL) cells are able to express RANKL and RANK under physiological conditions [22]. Interleukin (IL)-1 β and tumor necrosis factor α (TNF- α) expression together with RANKL and RANK transcription in osteoclasts could only be detected by *in situ* hybridization under experimentally challenged pathological conditions [21, 23]. The authors assume that RANKL-RANK expression is not the only autocrine pathway for regulating differentiation and proliferation of osteoclasts. Periodontal ligament (PDL) cells submitted to orthodontic force also expressed IL-1 β , TNF- α and RANKL in this experiment. The onset of chronic periodontitis is associated with the expression of inflammatory cytokines, i.e. IL-1 β or TNF- α . RANKL activity in epithelial and connective tissue cells in the present study may indicate a causal relationship between the inflammatory cytokines and autocrine RANKL expression. The low co-incidence in some active endothelial cells of a few patients and the often widely distributed numbers of RANKL-active cells seen in our study support the concept of autocrine RANKL expression in cells of different origin. While Tonetti *et al.* [14] regularly detected PECAM-1 expression around capillary loops in healthy gingival samples, we were unable to find any positive staining for CD31 in tissues from non-periodontitis subjects.

Our results were in agreement with the finding that RANKL-positive cells were widely distributed in periodontitis patients, whereas OPG-positive cells were present in samples from both periodontally diseased patients and healthy subjects [24]. Though we did not use antibodies against OPG due to our limited access to the antibodies, we regularly observed RANKL expression in epithelial cells from the diseased group. Using monoclonal antibodies, Crotti *et al.* [25] detected OPG in both epithelial lining cells and endothelial cells; no information was given on RANKL labeling in epithelial cells. Their finding of RANKL-expressing mononuclear leukocytes in granulation tissues and matrices is consistent with the RANKL expression by mono- and multinuclear leukocytes in our periodontitis patients [26]. Our observations only partially support the hypothesis that RANKL expression is restricted to T- and B-cell activation, as suggested previously [11].

Osteoclasts as a source of RANKL expression have been questioned, since their positive staining may result from binding extracellular RANKL to RANK receptor on the cell membrane [23]. Nevertheless, positive cytoplasmic staining of osteoclasts in our positive controls confirms the immunohistochemical method used in this study.

RANKL is a membrane-binding protein in osteoblasts, but the expression of membrane-anchored RANKL on T-cells is limited and the major portion of RANKL protein produced by T-cells may become active after shedding in the soluble form. We performed ELISA for GCF total sRANKL (free and OPG-bound RANKL) to evaluate the active form of that protein [27].

Amounts of RANKL and OPG proteins estimated in our GCF samples substantiate immunohistological observations. The values are somewhat higher than those reported previously [12]. Since samples were pooled in both studies, the total amount of GCF per sample remains unknown, and thus any comparison would lack accuracy. The clinical data in our study indicate improvements in regard to patient's oral hygiene performance; the residual probing depths; attachment level measures and bleeding of the crevice during the course of the treatment (Table 1). These improvements were partially reflected by protein levels estimated by analysing GCF samples. According to the data published by other groups, concentrations estimated for RANKL showed a tendency to decrease parallel with the descending amounts of GCF at every time point of sampling. On the contrary, OPG levels showed an inconsistent development and did not reveal a clear tendency either to decrease or to increase. Since estimated changes in values did not reach the level of statistical significance for both proteins, we were unable to address the effects of periodontal therapy to the regulation of expression of the two proteins in periodontal tissues in this study.

RANKL expression correlated positively with IL-6 and Oncostatin M in the GCF of periodontitis patients, whereas OPG levels were not detectable in the majority of diseased or healthy sites [23]. However, the OPG levels estimated exceeded those assessed by our study. The RANKL content in our pooled samples was much higher than that estimated for single sites by Lu *et al.* [23] Weighing as a method for quantifying the GCF amount contains the concern of evaporative losses because of delay in determination [28]. As mentioned in the same paper, the solution may be the use of a sealed container, as it was done in this study. The RANKL/OPG ratios in the GCF estimated with therapy progress remain future discussion topic.

Acknowledgements

This research was supported in part by The Scientific and Technical Research Council of Turkey (TUBITAK). Our gratitude belongs Dr. Stefan Roth, BioVendor Heidelberg, Germany, who kindly provided the monoclonal

RANKL antibody. We are grateful to Ms. Balz and Ms. von Zitzewitz (Department of Oral Surgery, Head: Professor Dr. P. Reichart) for their expertise in the immunohistochemical processing. We appreciate the support by Ms. Kanitz in preparing the ELISA tests (Institute for Periodontology, CC 3 Universitätsmedizin Charité, Berlin, Germany).

The authors declare no conflict of interest.

References

- Gori F, Hofbauer LC, Dunstan CR, et al. (2000): The expression of osteoprotegerin and RANK ligand and the support of osteoclast formation by stromal-osteoblast lineage cells is developmentally regulated. *Endocrinology* 141: 4768-4776.
- Feng X (2005): RANKing intracellular signaling in osteoclasts. *IUBMB Life* 57: 389-395.
- Kanzaki H, Chiba M, Shimizu Y, Mitani H (2001): Dual regulation of osteoclast differentiation by periodontal ligament cells through RANKL stimulation and OPG inhibition. *J Dent Res* 80: 887-891.
- Kanzaki H, Chiba M, Shimizu Y, Mitani H (2002): Periodontal ligament cells under mechanical stress induce osteoclastogenesis by receptor activator of nuclear factor kappaB ligand up-regulation via prostaglandin E2 synthesis. *J Bone Miner Res* 17: 210-220.
- Fukushima H, Kajiyama H, Takada K, et al. (2003): Expression and role of RANKL in periodontal ligament cells during physiological root-resorption in human deciduous teeth. *Eur J Oral Sci* 111: 346-352.
- Bartold PM, Cantley MD, Haynes DR (2010): Mechanisms and control of pathologic bone loss in periodontitis. *Periodontol* 2000 53: 55-69.
- Ohazama A, Courtney JM, Sharpe PT (2004): Opg, Rank, and Rankl in tooth development: co-ordination of odontogenesis and osteogenesis. *J Dent Res* 83: 241-244.
- Lossdörfer S, Götz W, Jäger A (2002): Immunohistochemical localization of receptor activator of nuclear factor kappaB (RANK) and its ligand (RANKL) in human deciduous teeth. *Calcif Tissue Int* 71: 45-52.
- Liu D, Xu JK, Figliomeni L, et al. (2003): Expression of RANKL and OPG mRNA in periodontal disease: possible involvement in bone destruction. *Int J Mol Med* 11: 17-21.
- Valverde P, Kawai T, Taubman MA (2005): Potassium channel-blockers as therapeutic agents to interfere with bone resorption of periodontal disease. *J Dent Res* 84: 488-499.
- Taubman MA, Valverde P, Han X, Kawai T (2005): Immune response: the key to bone resorption in periodontal disease. *J Periodontol* 76: 2033-2041.
- Mogi M, Otogoto J, Ota N, Togari A (2004): Differential expression of RANKL and osteoprotegerin in gingival crevicular fluid of patients with periodontitis. *J Dent Res* 83: 166-169.
- Maas M, Stapleton M, Bergom C, et al. (2005): Endothelial cell PECAM-1 confers protection against endotoxic shock. *Am J Physiol Heart Circ Physiol* 288: 159-164.
- Tonetti MS, Gerber L, Lang NP (1994): Vascular adhesion molecules and initial development of inflammation in clinically healthy human keratinized mucosa around teeth and osseointegrated implants. *J Periodontal Res* 29: 386-392.

15. Bock O, Loch G, Schade U, et al. (2005): Osteosclerosis in advanced chronic idiopathic myelofibrosis is associated with endothelial overexpression of osteoprotegerin. *Br J Haematol* 130: 76-82.
16. Silness J, Loe H (1964): Periodontal disease in pregnancy. II. Correlation between oral hygiene and periodontal condition. *Acta Odontol Scand* 22: 121-135.
17. Loe H, Silness J (1963): Periodontal disease in pregnancy. I. Prevalence and severity. *Acta Odontol Scand* 21: 533-551.
18. Ainamo J, Bay I (1975): Problems and proposals for recording gingivitis and plaque. *Int Dent J* 25: 229-235.
19. Friedmann A, Strietzel FP, Maretzki B, et al. (2002): Histological assessment of augmented jaw bone utilizing a new collagen barrier membrane compared to a standard barrier membrane to protect a granular bone substitute material. *Clin Oral Implants Res* 13: 587-594.
20. Baltacıoğlu E, Kehribar MA, Yuva P, et al. (2010): Total oxidant status and bone resorption biomarkers in serum and gingival crevicular fluid of patients with periodontitis. *J Periodontol* 85: 317-326.
21. Kawai T, Matsuyama T, Hosokawa Y, et al. (2006): B and T lymphocytes are the primary sources of RANKL in the bone resorptive lesion of periodontal disease. *Am J Pathol* 169: 987-998.
22. Ogasawara T, Yoshimine Y, Kiyoshima T, et al. (2004): In situ expression of RANKL, RANK, osteoprotegerin and cytokines in osteoclasts of rat periodontal tissue. *J Periodontal Res* 39: 42-49.
23. Lu HK, Chen YL, Chang HC, et al. (2006): Identification of the osteoprotegerin/receptor activator of nuclear factor-kappa B ligand system in gingival crevicular fluid and tissue of patients with chronic periodontitis. *J Periodontal Res* 41: 354-360.
24. Crotti T, Smith MD, Hirsch R, et al. (2003): Receptor activator NF kappaB ligand (RANKL) and osteoprotegerin (OPG) protein expression in periodontitis. *J Periodontal Res* 38: 380-387.
25. Crotti TN, Smith MD, Findlay DM, et al. (2004): Factors regulating osteoclast formation in human tissues adjacent to peri-implant bone loss: expression of receptor activator NFkappaB, RANK ligand and osteoprotegerin. *Biomaterials* 25: 565-573.
26. Teng YT, Nguyen H, Gao X, et al. (2000): Functional human T-cell immunity and osteoprotegerin ligand control alveolar bone destruction in periodontal infection. *J Clin Invest* 106: 59-67.
27. Nagasawa T, Kiji M, Yashiro R, et al. (2007): Roles of receptor activator of nuclear factor- κ B ligand (RANKL) and osteoprotegerin in periodontal health and disease. *Periodontol* 2000 43: 65-84.
28. Griffiths GS (2003): Formation, collection and significance of gingival crevice fluid. *Periodontology* 2000 31: 32-42.